



# MARS is calling

**CLINID conference**  
Hunter Ratliff  
04/16/2025

*Ages, dates, and other identifying information may have been changed  
I have no conflict of interest in relation to this presentation*

# Shortcuts



**Part A:** (inpatient)

MARS #1: immunocompromise | GI microbiome

**Part B** (outpatient): Clinic time | rash | eos timeline

MARS #2: case | Mir's water | pathogen biofilms

**Part C** (readmission): Alpha-gal

MARS #2: case | LSMMG | nematodes | meds

**Takeaway slide**

# Case 1: HPI



A **73 y/o M** with PMH including CLL, CAD, OSA, seizures p/w **cardiogenic shock**

# Case 1: HPI

---

A **73 y/o M** with PMH including CLL, CAD, OSA, seizures p/w **cardiogenic shock**

- Admitted to OSH with **three weeks** of **dyspnea**
- Had been also having **chest pain** while shoveling snow
- **?diaphoresis** (but not with chest pain)

# Case 1: HPI

---

A **73 y/o M** with PMH including CLL, CAD, OSA, seizures p/w **cardiogenic shock**

- Admitted to OSH with **three weeks** of **dyspnea**
- Had been also having **chest pain** while shoveling snow
- **?diaphoresis** (but not with chest pain)

Not much else in the initial H&P, since patient was in florid shock

# Case 1: HPI


A **73 y/o M** with PMH including CLL, CAD, OSA, seizures p/w **cardiogenic shock**

- Admitted to OSH with **three weeks** of **dyspnea**
- Had been also having **chest pain** while shoveling snow
- **?diaphoresis** (but not with chest pain)

Not much else in the initial H&P, since patient was in florid shock

CBC	Result
WBC	<b>36</b>
Hgb	16
Platelets	176
Creatine	1.46
Lactate	<b>3.7</b>

Baseline is 13-20



# Case 1: HPI

A **73 y/o M** with PMH including CLL, CAD, OSA, seizures p/w **cardiogenic shock**

- Admitted to OSH with **three weeks** of **dyspnea**
- Had been also having **chest pain** while shoveling snow
- **?diaphoresis** (but not with chest pain)

Not much else in the initial H&P, since patient was in florid shock

CBC	Result
WBC	<b>36</b>
Hgb	16
Platelets	176
Creatine	1.46
Lactate	<b>3.7</b>

Baseline is 13-20

Troponin	
Initial	<b>1,200</b>
+40 min	<b>5,200</b>
+2 hr	<b>11,300</b>
+8 hr	<b>24,700</b>

Hemodynamics
Levophed: 0.13 (mcg/kg/min)
Milrinone: 0.125 (mcg/kg/min)

# Case 1: HPI

A **73 y/o M** with PMH including CLL, CAD, OSA, seizures p/w **cardiogenic shock**

- Admitted to OSH with **three weeks** of **dyspnea**
- Had been also having **chest pain** while shoveling snow
- **?diaphoresis** (but not with chest pain)

Not much else in the initial H&P, since patient was in florid shock

CBC	Result
WBC	36
Hgb	16
Platelets	176
Creatine	1.46
Lactate	<b>3.7</b>

Baseline is 13-20

Troponin	
Initial	<b>1,200</b>
+40 min	<b>5,200</b>
+2 hr	<b>11,300</b>
+8 hr	<b>24,700</b>

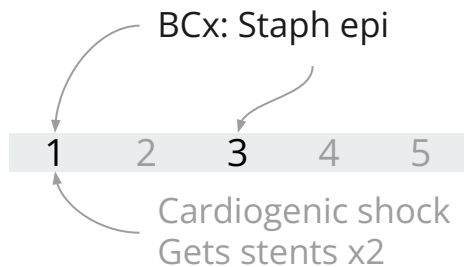
## Emergent cath

- Confirms shock is cardiogenic (cardiac index **1.42**)
- 99% stenosis of RCA
- Placed stents x2

# Case 1: HPI

A **73 y/o M** with PMH including CLL (has port), CAD, OSA, seizures p/w **cardiogenic shock**

- **Staph epi** grows in both sets of blood cultures, twice
  - Unofficial **time to positivity** implies **port infection**

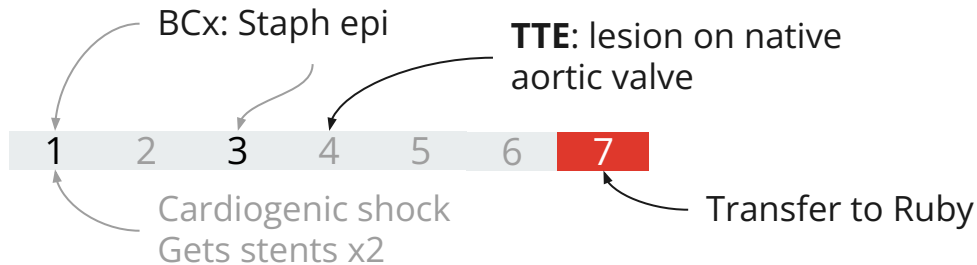


	<b>Port</b>	Peripheral
Collected	9:02 am	6:07 am
TTP	<b>13 hrs</b>	21 hrs

# Case 1: HPI

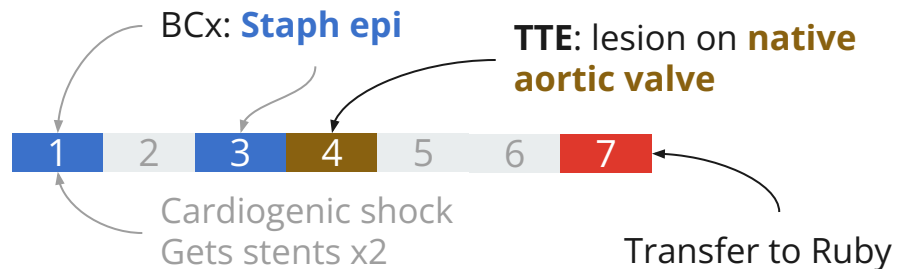
A **73 y/o M** with PMH including CLL (has port), CAD, OSA, seizures p/w **cardiogenic shock**

- **Staph epi** grows in both sets of blood cultures, twice
  - Unofficial **time to positivity** implies **port infection**
- Transthoracic echo: Echodensity on **aortic valve**
  - **Native** aortic valve



# Case 1: Summary

A **73 y/o M** with PMH including CLL (has port), CAD/PAD, OSA, seizures p/w **cardiogenic shock** & NSTEMI s/p stenting. Found to have persistent **staph epi bacteremia** and echodensity on **native aortic** valve

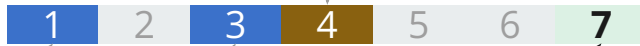

# Case 1: Transfer to Ruby

A 73 y/o M with PMH including CLL (has port), CAD/PAD s/p EVAR, OSA, seizures p/w **cardiogenic shock** & **native aortic** valve **staph epi endocarditis**.

- Repeat **blood cultures no growth**
  - On **day 7 of vancomycin**

Echo: **native aortic valve IE**



BCx: **Staph epi**

BCx: **No growth**

## Discharge summary

Patient underwent cardiac catheterization on [REDACTED] which showed 3 vessel disease. Cardiothoracic surgery was consulted and recommended PCI to RCA and mid LAD. Due to cardiogenic shock he was initiated on Levophed and milrinone. Impella was considered but vascular access was difficult.

Swan-Ganz catheter was placed. Blood cultures were obtained **from his port** and were positive for **staphylococcus epidermidis** for which ID was consulted.

# Case 1: Transfer to Ruby

A 73 y/o M with PMH including CLL (has port), CAD/PAD s/p EVAR, OSA, seizures p/w **cardiogenic shock** & **native aortic** valve **staph epi endocarditis**.

- Repeat **blood cultures no growth**
  - On **day 7 of vancomycin**
- **Transesophageal echo: 1x1cm lesion** on aortic valve

Echo: **native aortic valve IE**



BCx: **Staph epi**

BCx: **No growth**

## Discharge summary

Patient underwent cardiac catheterization on [REDACTED] which showed 3 vessel disease. Cardiothoracic surgery was consulted and recommended PCI to RCA and mid LAD. Due to cardiogenic shock he was initiated on Levophed and milrinone. Impella was considered but vascular access was difficult.

Swan-Ganz catheter was placed. Blood cultures were obtained **from his port** and were positive for **staphylococcus epidermidis** for which ID was consulted.

# Case 1: Hardware

A 73 y/o M with PMH including CLL (has port), CAD/PAD s/p EVAR, OSA, seizures p/w **cardiogenic shock** & **native aortic** valve **staph epi endocarditis**.

Discharge summary mentions **EVAR**

- 5 years ago, had endovascular aneurysm repair for AAA

Echo: **native aortic** valve IE



BCx: **Staph epi**

BCx: **No growth**

## Discharge summary

Patient underwent cardiac catheterization on [REDACTED] which showed 3 vessel disease. Cardiothoracic surgery was consulted and recommended PCI to RCA and mid LAD. Due to cardiogenic shock he was initiated on Levophed and milrinone. **Impella was considered but vascular access was difficult due to his EVAR for Impella or IABP.** Swan-Ganz catheter was placed. Blood cultures were obtained **from his port** and were positive for **staphylococcus epidermidis** for which ID was consulted.

# Case 1: Hardware

A 73 y/o M with PMH including CLL (has port), CAD/PAD s/p EVAR, OSA, seizures p/w **cardiogenic shock** & **native aortic** valve **staph epi endocarditis**.

Discharge summary mentions **EVAR**

- 5 years ago, had endovascular aneurysm repair for AAA
- **No imaging done** as of yet (only had CTA PE)

Echo: **native aortic valve IE**

**CTA**



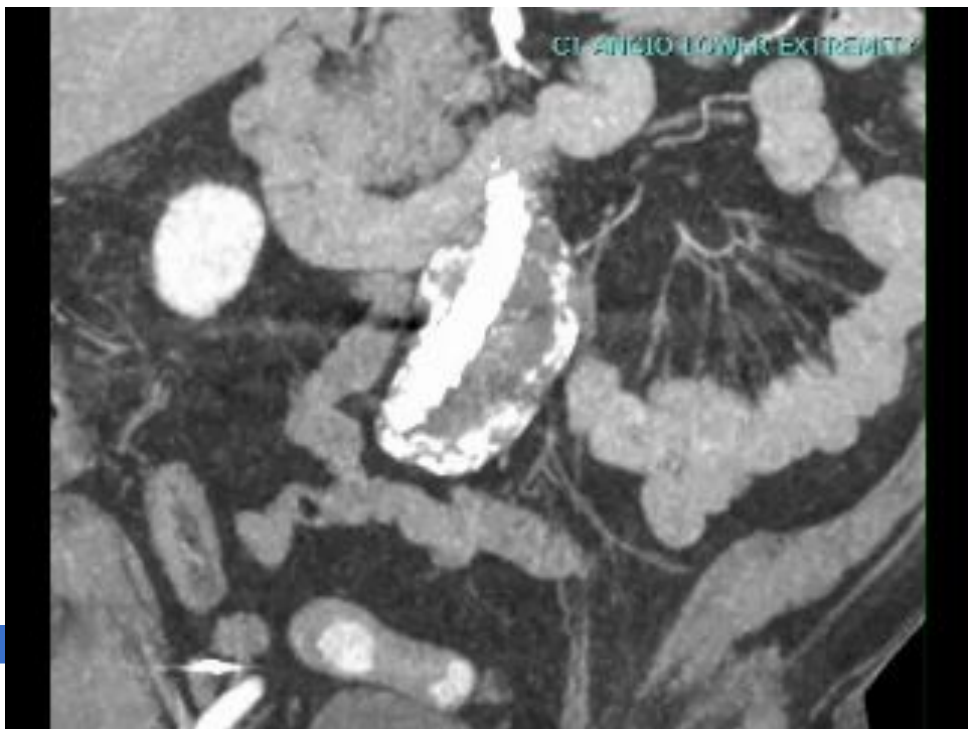
BCx: **Staph epi**

BCx: **No growth**

## Discharge summary

Patient underwent cardiac catheterization on [REDACTED] which showed 3 vessel disease. Cardiothoracic surgery was consulted and recommended PCI to RCA and mid LAD. Due to cardiogenic shock he was initiated on Levophed and milrinone. **Impella was considered but vascular access was difficult due to his EVAR for Impella or IABP.** Swan-Ganz catheter was placed. Blood cultures were obtained **from his port** and were positive for **staphylococcus epidermidis** for which ID was consulted.

# Case 1: Hardware



BCx: Staph epi

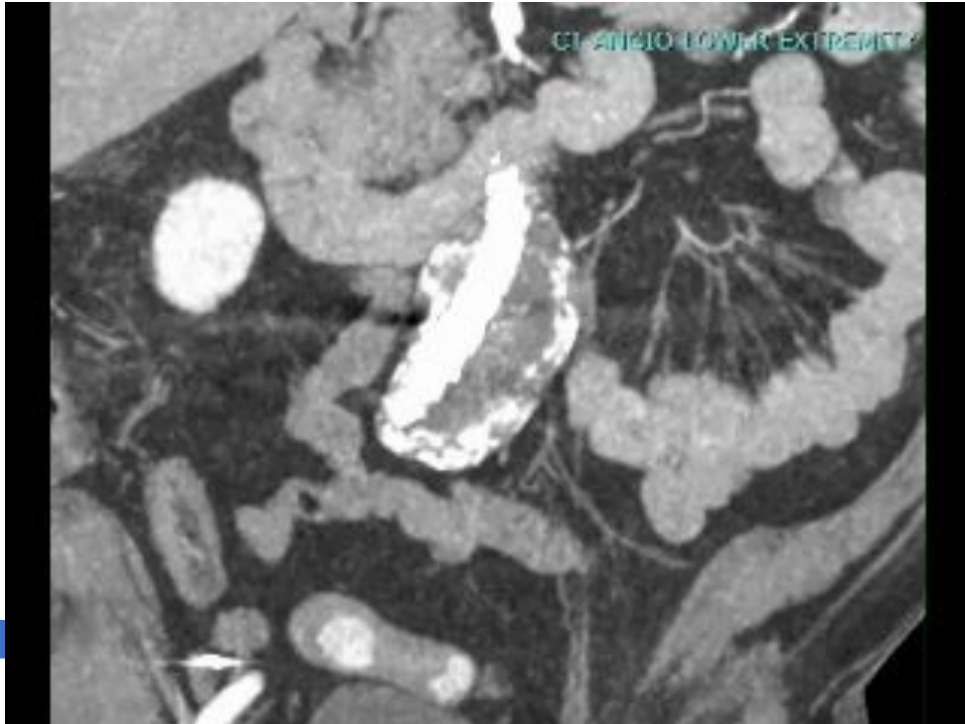
BCx: No growth

## CTA A/P with runoff

**Indication:** Hx EVAR, preoperative exam

**Aortoiliac:** Postsurgical changes from EVAR for infrarenal abdominal aortic aneurysm. Aneurysm sac at iliac bifurcation measures 5.7 cm, **unchanged from [prior scans]**.

# Case 1: Hardware

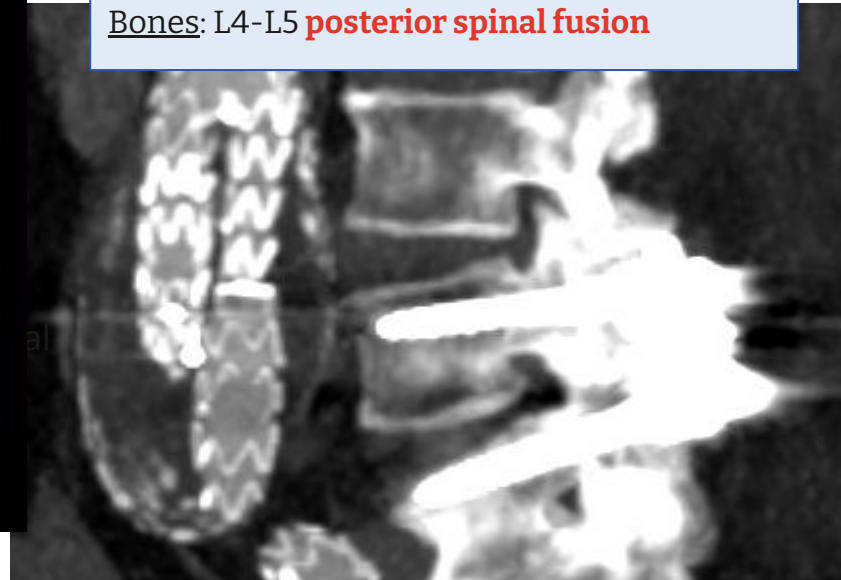

## CTA A/P with runoff

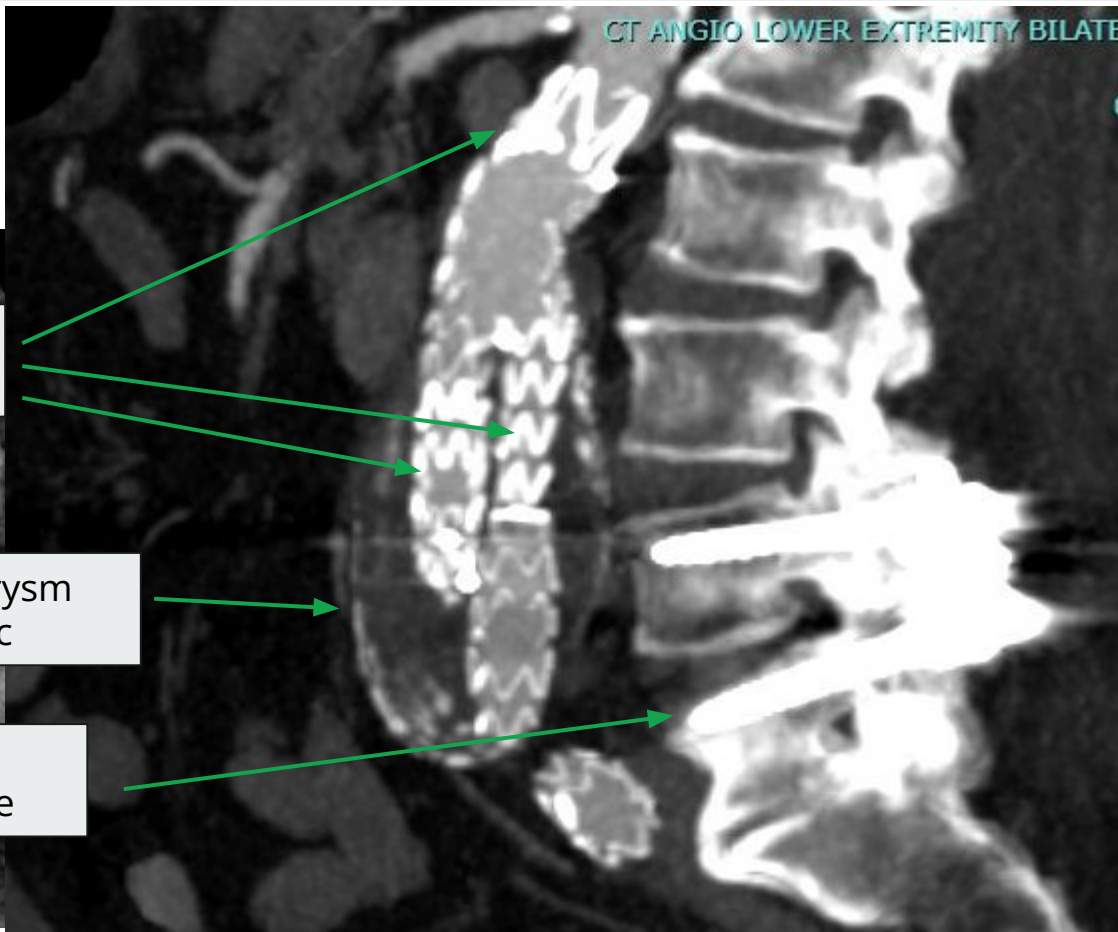
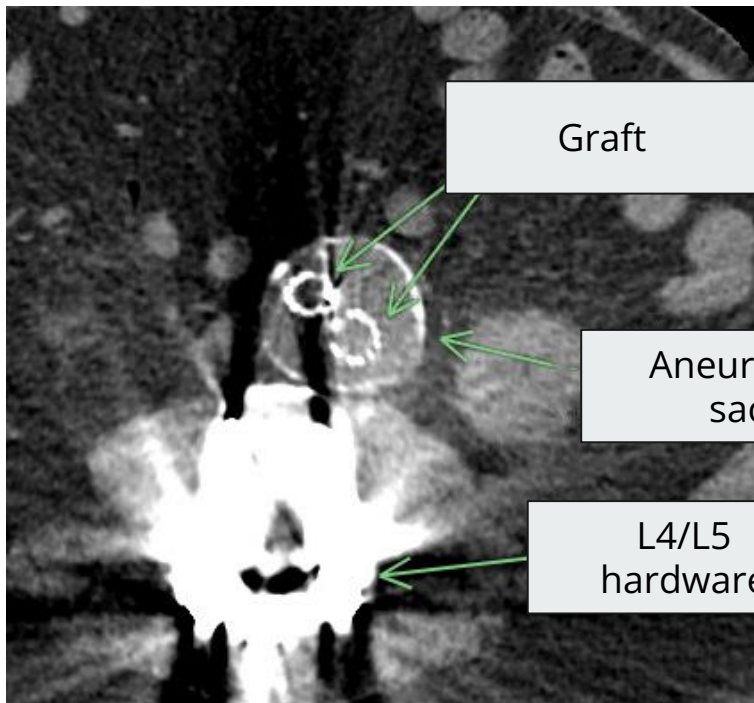
Spleen: evolving **splenic infarct**

Kidneys: Right **renal infarct**

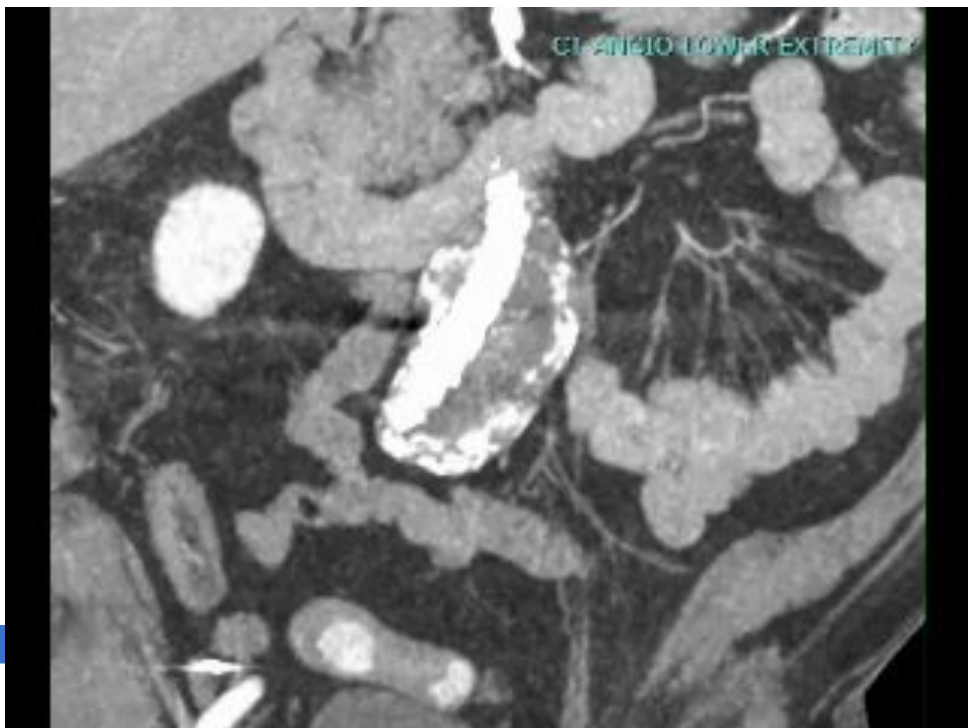
Bones: L4-L5 **posterior spinal fusion**



# Case 1: Hardware



# Case 1: Hardware



BCx: **Staph epi**

BCx: **No growth**

## CTA A/P with runoff

Indication: Hx EVAR, preoperative exam

Aortoiliac: Postsurgical changes from EVAR for infrarenal abdominal aortic aneurysm. Aneurysm sac at iliac bifurcation measures 5.7 cm, **unchanged from [prior scans]**.

Spleen: evolving **splenic infarct**

Kidneys: Right **renal infarct**

Bones: L4-L5 **posterior spinal fusion**

**IMPRESSION:** **stable size** of infrarenal abdominal aortic aneurysm sac. Evolving splenic and renal infarcts



# Vascular Graft Infections (VGI)

## Objectives

- Accurately **diagnose & categorize** (suspected & confirmed) **VGIs**
- Describe surgical management options &

**Recall my prior presentation**  
From October of 2024  
<https://www.huntermatliff1.com/talk/cid-2024-10-03/>

DeSimone et al  
*Clinical Infectious Diseases*  
[citation 2.1]

Clinical Infectious Diseases



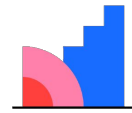
13 June 2024  
Volume 53  
Number 12  
IDSA  
hivma  
oxford  
academic.oup.com/cid

**MAGIC**  
Management of Aortic Graft Infection Collaboration

[Q1] Is this a  
vascular graft  
infection?

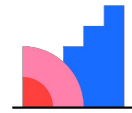


**[Q2] Utility of  
PET/CT or SPECT?**



**Mentimeter**

**[Q3] Chance of  
relapse w/o  
suppression**



**Mentimeter**

**Table 1. A Case Definition for Vascular Graft Infection of the Management of Aortic Graft Infection Collaboration (MAGIC)**

	Clinical/Surgical	Radiography	Laboratory <sup>a</sup>
Major criteria	<ol style="list-style-type: none"><li>1. Purulence (confirmed by microscopy) around graft or in aneurysm sac during surgery<sup>b</sup></li><li>2. Open wound with exposed graft or communicating sinus tract</li><li>3. Fistula development (eg, aortoenteric)</li><li>4. Graft insertion in an infected site (eg, fistula, mycotic aneurysm, or infected pseudoaneurysm)</li></ol>	<ol style="list-style-type: none"><li>1. Perigraft fluid on CT scan <math>\geq 3</math> mo after insertion</li><li>2. Perigraft gas on CT scan <math>\geq 7</math> wk after insertion</li><li>3. An increase in perigraft gas volume demonstrated on serial imaging</li></ol>	<ol style="list-style-type: none"><li>1. Organisms recovered from an explanted graft</li><li>2. Organisms recovered from an intraoperative specimen</li><li>3. Organism recovered from a percutaneous aspirate of perigraft fluid</li></ol>



**Prior presentation (Oct'24)**  
<https://www.hunerratliff1.com/talk/cid-2024-10-03/>

**Table 1. A Case Definition for Vascular Graft Infection of the Management of Aortic Graft Infection Collaboration (MAGIC)**

	Clinical/Surgical	Radiography	Laboratory <sup>a</sup>
Major criteria	<ol style="list-style-type: none"> <li>1. Purulence (confirmed by microscopy) around graft or in aneurysm sac during surgery</li> <li>2. Open wound with exposed graft or communicating sinus tract</li> <li>3. Fistula development (eg, aortoenteric)</li> <li>4. Graft insertion in an infected site (eg, fistula, mycotic aneurysm, or infected pseudoaneurysm)</li> </ol>	<ol style="list-style-type: none"> <li>1. Perigraft fluid on CT scan <math>\geq 3</math> mo after insertion</li> <li>2. Perigraft gas on CT scan <math>\geq 7</math> wk after insertion</li> <li>3. An increase in perigraft gas volume demonstrated on serial imaging</li> </ol>	<ol style="list-style-type: none"> <li>1. Organisms recovered from an explanted graft</li> <li>2. Organisms recovered from an intraoperative specimen</li> <li>3. Organism recovered from a percutaneous aspirate of perigraft fluid</li> </ol>
Minor criteria	<ol style="list-style-type: none"> <li>1. Localized clinical features of VGI (eg, erythema, warmth, swelling, purulent discharge, and pain)</li> <li>2. Fever <math>\geq 38^{\circ}\text{C}</math> with VGI as most likely cause</li> </ol>	<ol style="list-style-type: none"> <li>1. Other (eg, suspicious perigraft gas/fluid/soft tissue inflammation; aneurysm expansion; pseudo-aneurysm formation; focal bowel wall thickening; discitis/osteomyelitis; suspicious metabolic activity on FDG PET/CT; radiolabeled leucocyte uptake)</li> </ol>	<ol style="list-style-type: none"> <li>1. Blood culture(s) positive and no apparent source except for VGI</li> <li>2. Abnormally elevated inflammatory markers with VGI as the most likely cause (eg, ESR, CRP, and white blood cell count)</li> </ol>



Management of Aortic Graft Infection Collaboration

**Suspected VGI**

~~One major~~ - or -  
Minor from 2 of 3 categories

**Prior presentation (Oct'24)**

<https://www.hunerratliff1.com/talk/cid-2024-10-03/>

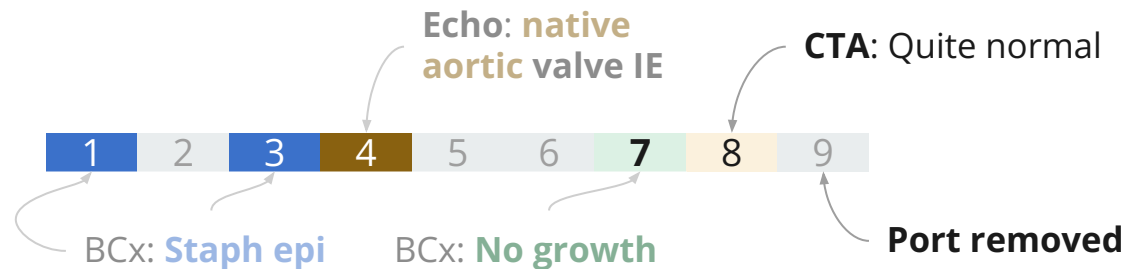**Confirmed VGI**

~~One major~~ - **plus** - any other criterion (major or minor) from another category

# Case 1: Hospital course

A 73 y/o M with PMH including CLL (has port), CAD/PAD s/p EVAR, OSA, seizures p/w **cardiogenic shock** & **native aortic** valve **staph epi endocarditis**.

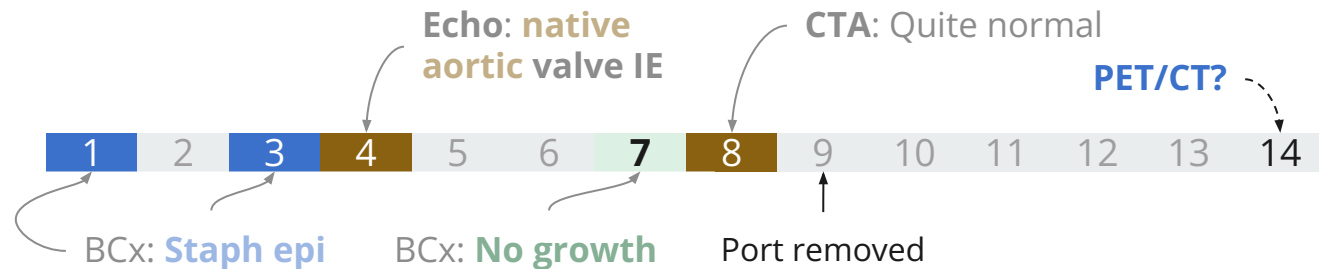
- **Vascular surgery consulted:** Not concerned for graft infection
- Port is removed



# Case 1: Hospital course

A 73 y/o M with PMH including CLL (has port), CAD/PAD s/p EVAR, OSA, seizures p/w **cardiogenic shock** & **native aortic** valve **staph epi endocarditis**. Clinical concern for VGI but CTA normal

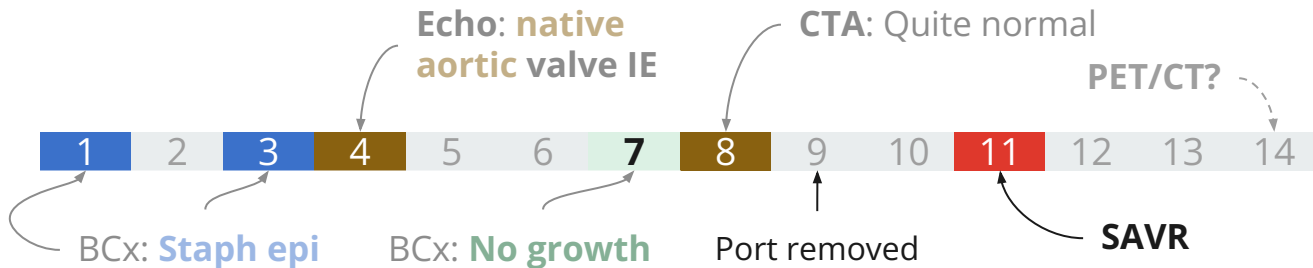
- Asked for **PET/CT or SPECT...**
  - Can't happen **until next week**



# Case 1: Hospital course

A 73 y/o M with PMH including CLL (has port), CAD/PAD s/p EVAR, OSA, seizures p/w **cardiogenic shock** & **native aortic** valve **staph epi endocarditis**. Clinical concern for VGI but CTA normal

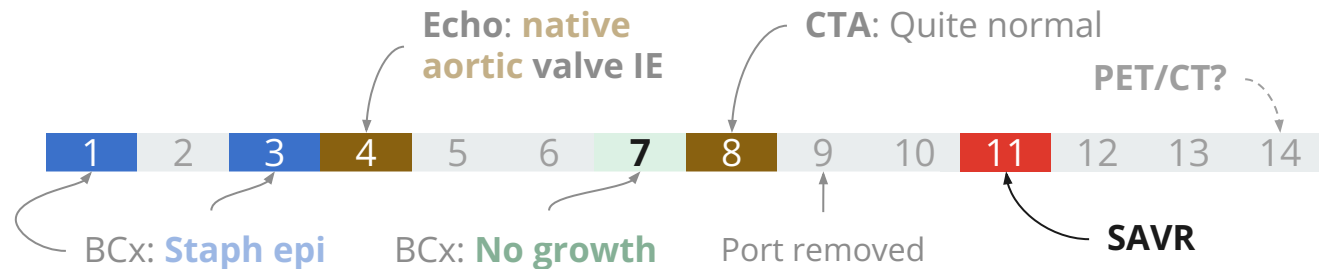
- Asked for **PET/CT or SPECT...**
  - Can't happen **until next week**
- CT surgery plans on **replacing aortic valve** before that time
  - Cardiogenic shock from aortic insufficiency is a **class I indication**



# Case 1: Hospital course

A 73 y/o M with PMH including CLL (has port), CAD/PAD s/p EVAR, OSA, seizures p/w **cardiogenic shock** & **native aortic** valve **staph epi endocarditis**. Clinical concern for VGI but CTA normal

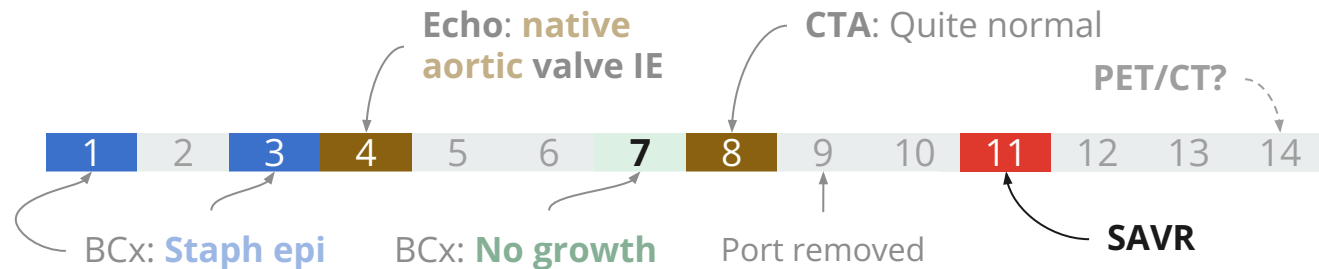
- Opted for **no nuclear imaging**
  - Would have been on 2 weeks on antibiotics at that point



# Case 1: Hospital course

A 73 y/o M with PMH including CLL (has port), CAD/PAD s/p EVAR, OSA, seizures p/w **cardiogenic shock** & **native aortic** valve **staph epi endocarditis**. Clinical concern for VGI but CTA normal

- Opted for **no nuclear imaging**
  - Would have been on 2 weeks on antibiotics at that point
- Had **surgical aortic valve replacement** with bioprosthetic valve
  - **Gram stain was positive**, but **no growth on cultures**
  - **Pathology** consistent with **acute endocarditis**





**MARS is calling...**



## MARS #1: HPI

---

A **38 y/o M** with no PMH (he is in excellent health) p/w **two days** of a **painful vesicular rash** in the T12 distribution

# MARS #1: HPI

---

A **38 y/o M** with no PMH (he is in excellent health) p/w **two days** of a **painful vesicular rash** in the T12 distribution

- Has been stressed recently with work (needing to **travel far from home**)
- Reportedly **received Shingrex booster** a few years ago
  - Which is kind of strange since he's immunocompetent

# MARS #1: HPI

---

A **38 y/o M** with no PMH (he is in excellent health) p/w **two days** of a **painful vesicular rash** in the T12 distribution

- Has been stressed recently with work (needing to **travel far from home**)
- Reportedly **received Shingrex booster** a few years ago
  - Which is kind of strange since he's immunocompetent

## Next steps?

- More questions?
- DDX?

Has been stressed recently with work  
(needing to **travel far from home**)



[Image Credit:](#) NASA/Joel Kowsky  
April 1, 2026

# MARS #1: Host changes in spaceflight [1]

## Don't sue me

The "Mars/MARS" cases are hypothetical and any similarity to real persons are coincidental

I have no affiliation with NASA (but my wife did)

- I would be happy for that to change, if NASA needs a space-healthcare epidemiologist

Shout out to [UTMB's aerospace medicine residency](#)



## Biomarkers of Inflammation in the LSAH: A Derived Systematic Review

Genevieve Korst, Hunter Ratliff, Adriana Babiak-Vazquez, Corey Theriot, Ruth A. Reitzel, Susana Zanello



# MARS #1: Host changes in spaceflight [1]

---

Spaceflight (zero gravity and other factors) do some **really weird stuff** to human physiology

- Most of these changes are non-infectious (but still really interesting)
- However, there are a fair amount of **immunologic changes** [\[self citation\]](#)

# MARS #1: Host changes in spaceflight [1]

---

Spaceflight (zero gravity and other factors) do some **really weird stuff** to human physiology

- Most of these changes are non-infectious (but still really interesting)
- However, there are a fair amount of **immunologic changes** [\[self citation\]](#)

Spaceflight itself **causes immunocompromise**

- Which is why astronauts get the Shingrex vaccine [2]

# MARS: Host immunosuppression in spaceflight [1]

Spaceflight makes you immunocompromised

- **26 instances of infections** during the Space Shuttle program (STS-1 to STS-89; from 1989-98)
- More recently, **14 out of 17** astronauts had **reactivation of herpesviruses** (during short duration, LEO flights, or on return)

LEO = Low earth orbit



# MARS: Host immunosuppression in spaceflight [1]

## How?

- **Reversible hypoplasia** of lymph tissue (spleen & thymus)
- **Blunted mitogen response** of T lymphocytes (compared to terrestrial controls)
- Animal models show **widespread effects** on both **innate** and **humoral** immune response
- Seems to be **time limited** (but we haven't done years long missions, like to Mars)



# MARS: Host immunosuppression in spaceflight [1]

## How?

- **Reversible hypoplasia** of lymph tissue (spleen & thymus)
- **Blunted mitogen response** of T lymphocytes (compared to terrestrial controls)
- Animal models show **widespread effects** on both **innate** and **humoral** immune response
- Seems to be **time limited** (but we haven't done years long missions, like to Mars)

## Why?

- **Gravity** (lymphatic drainage) may play a role
- Might also be **psych response** (similar issues seen with longterm submarines or antarctica)

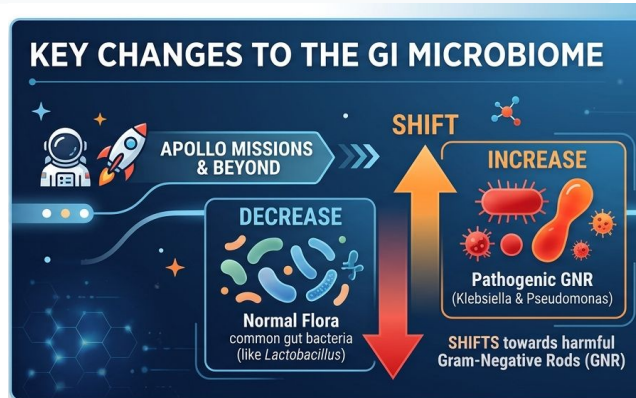


# MARS: GI microbiome shift [1]

## During Apollo missions:

- **Pathogenic increase:** Gram-negative rods (Klebsiella & Pseudomonas)
- **Loss of flora:** Significant shift away from normal healthy bacteria

*Evidence from Soviet studies (Salyut & Mir) shows changes as early as two weeks into flight.*



# MARS: GI microbiome shift [1]

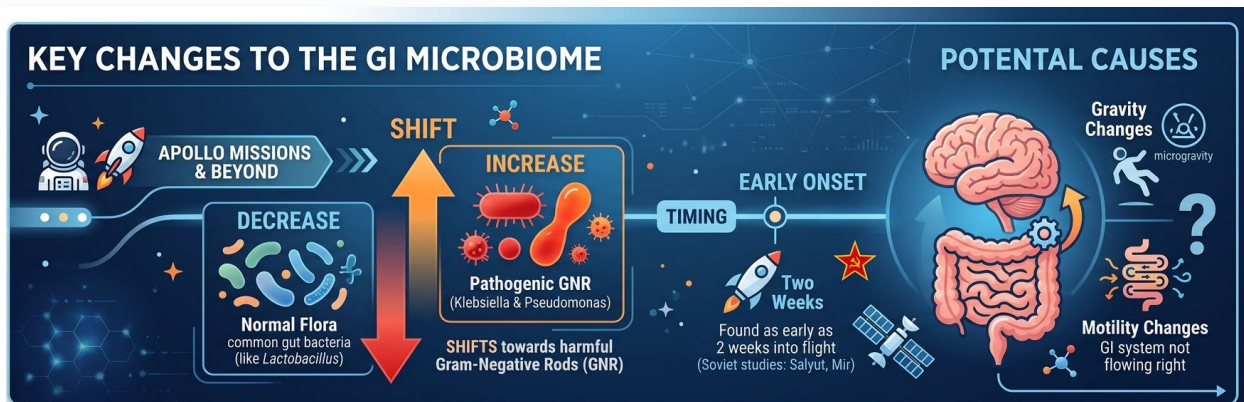
During Apollo missions:

- **Pathogenic increase:** Gram-negative rods (Klebsiella & Pseudomonas)
- **Loss of flora:** Significant shift away from normal healthy bacteria

*Evidence from Soviet studies (Salyut & Mir) shows changes as early as two weeks into flight.*

## Potential Causes

- **Altered Gravity:** Microgravity impacts fluid distribution
- **Motility Changes:** GI system "not flowing right" in space environment



# Returning to Earth (Case #1)



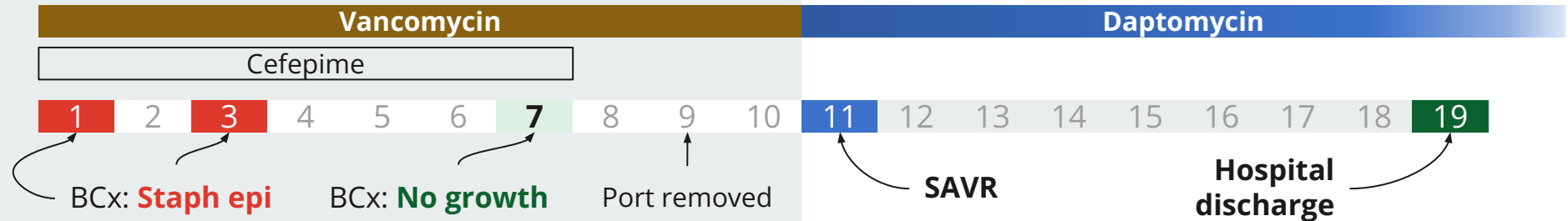
**Artemis II landing**

[Image Credit](#): NASA/Joel Kowsky

# Case 1: Summary of inpatient

A **73 y/o M** with PMH including CLL (had port), CAD/PAD s/p EVAR, OSA, seizures p/w **cardiogenic shock** & **native aortic valve staph epi endocarditis**. Clinical concern for VGI but CTA normal

- s/p **SAVR** with pathology confirming bacterial endocarditis
- Treated with **vanco** → **dapto**
- Plan for lifelong **doxy**



# Case 1: Eosinophilia

At the time of the **initial** consult, patient already had **noticeable eosinophilia**



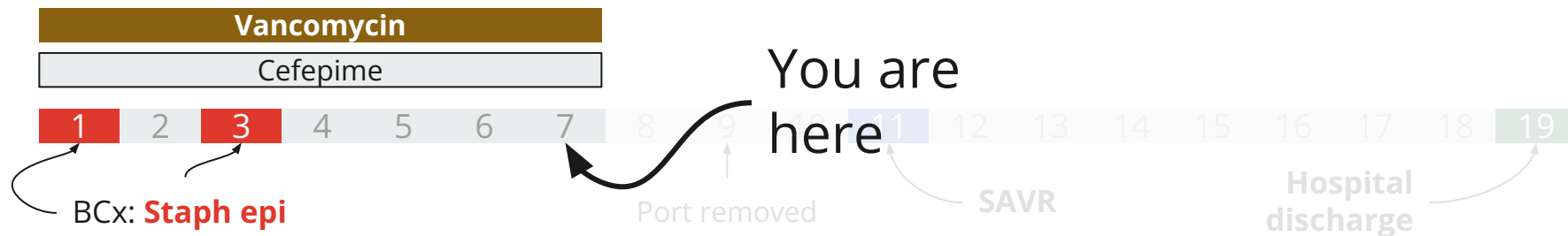
ABS COUNT	
PMN ABS	17.23 ▲
LYMPHS ABS	0.82 ▼
<b>EOS ABS</b>	<b>0.87 ▲</b>
MONOS ABS	1.72 ▲
BASOS ABS	0.17

# Case 1: Eosinophilia

At the time of the **initial consult**, patient already had **noticeable eosinophilia**

- Was on vancomycin and cefepime

ABS COUNT	
PMN ABS	17.23 ▲
LYMPHS ABS	0.82 ▼
<b>EOS ABS</b>	<b>0.87 ▲</b>
MONOS ABS	1.72 ▲
BASOS ABS	0.17

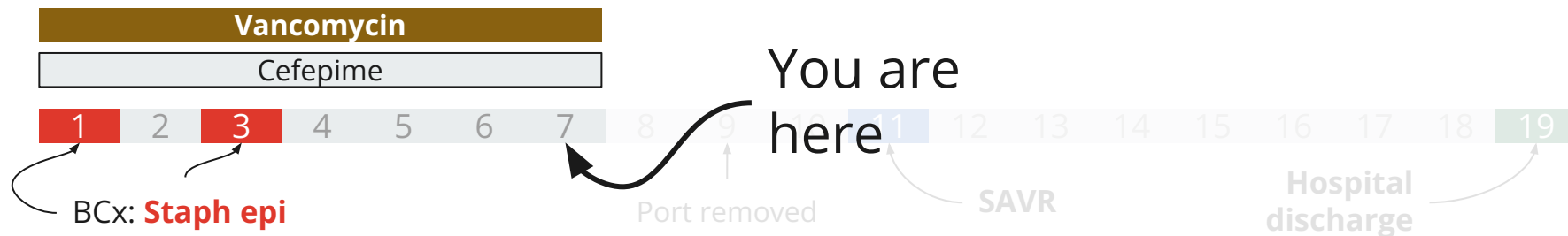


# Case 1: Eosinophilia

At the time of the **initial consult**, patient already had **noticeable eosinophilia**

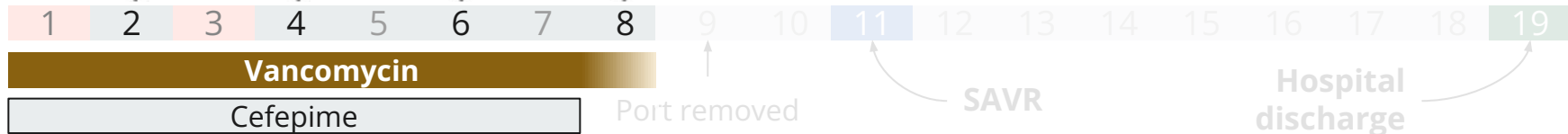
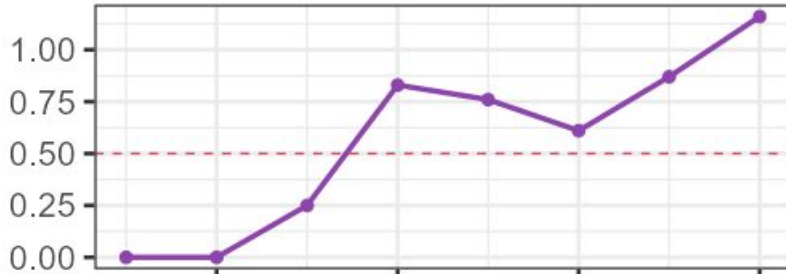
- Was on vancomycin and cefepime
- **No rash**
  - At least not yet...

ABS COUNT	
PMN ABS	17.23 ▲
LYMPHS ABS	0.82 ▼
<b>EOS ABS</b>	<b>0.87 ▲</b>
MONOS ABS	1.72 ▲
BASOS ABS	0.17



# Case 1: Eosinophilia

Absolute eosinophil count



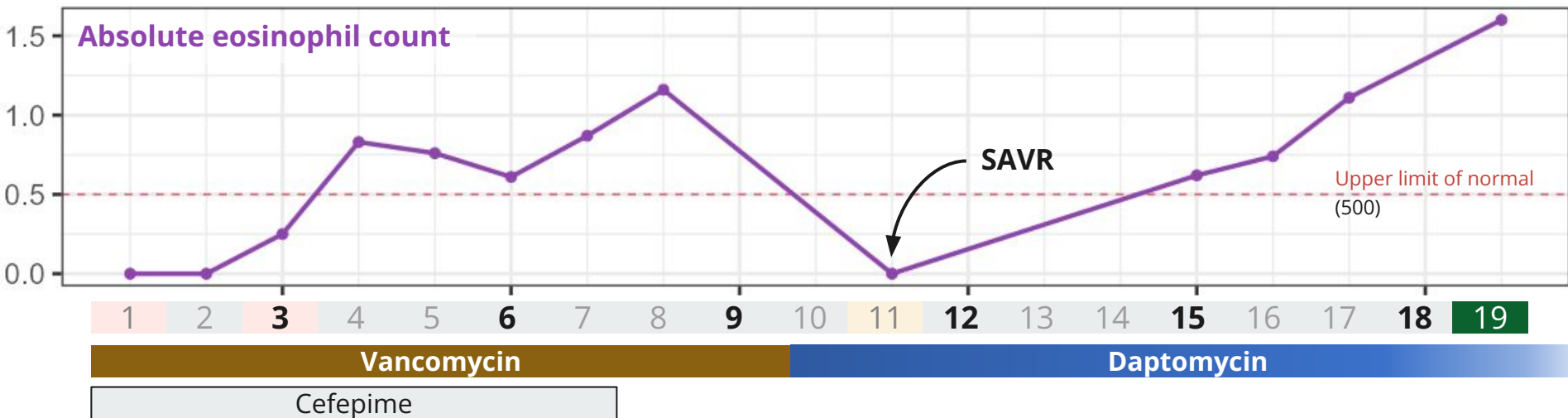ABS COUNT	
PMN ABS	17.23 ▲
LYMPHS ABS	0.82 ▼
<b>EOS ABS</b>	<b>0.87 ▲</b>
MONOS ABS	1.72 ▲
BASOS ABS	0.17

Upper limit of normal (500)



# Case 1: Eosinophilia

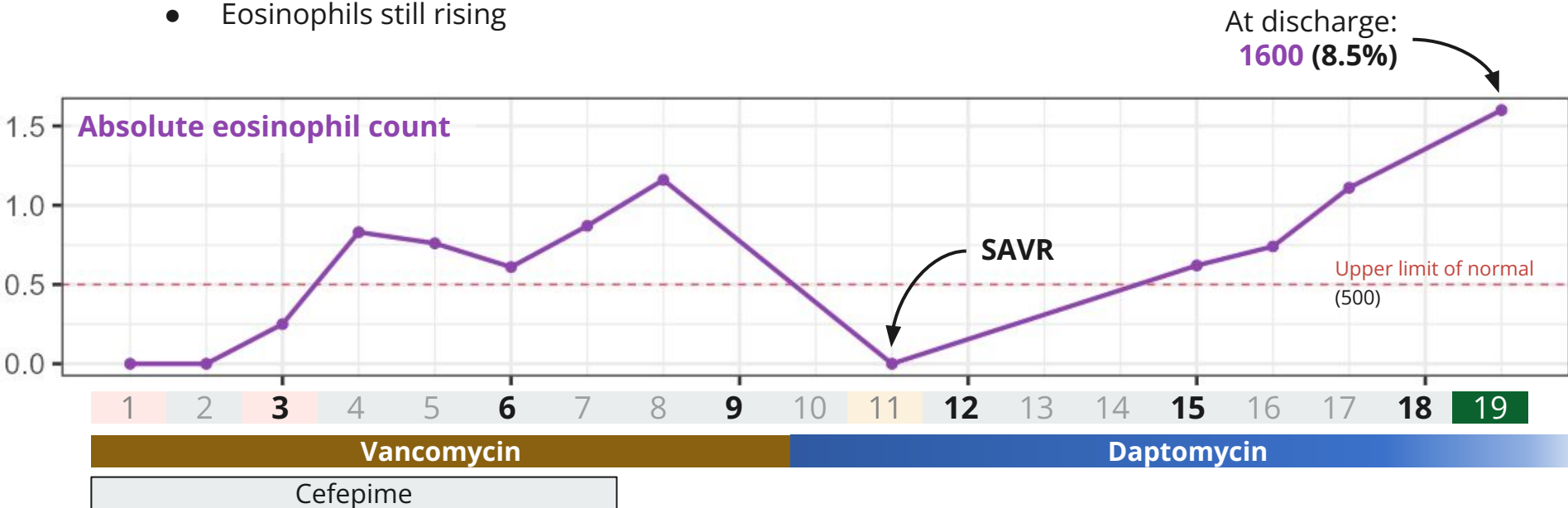
Switched to **daptomycin**...with **no improvement** (perhaps worsened?)



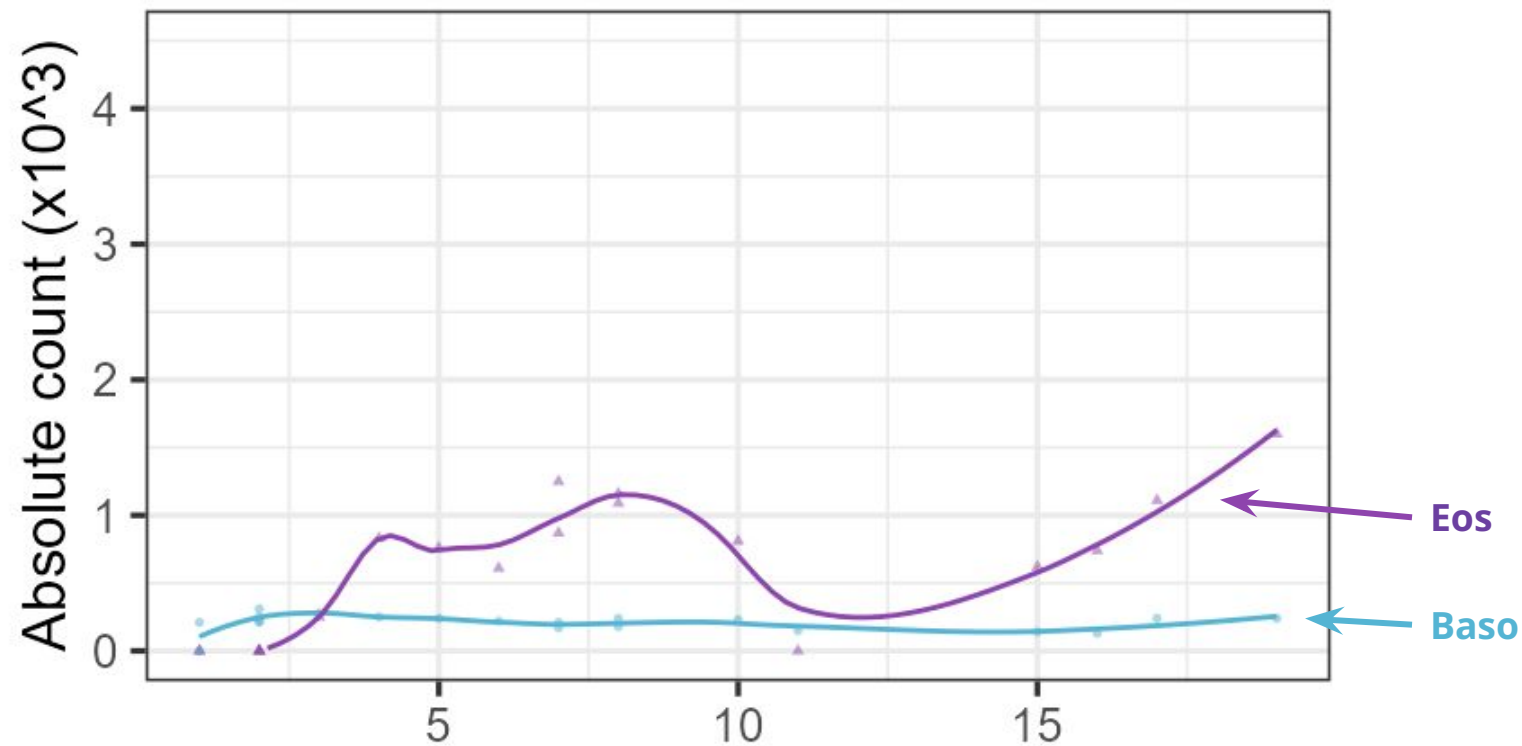
# Case 1: Eosinophilia

Switched to **daptomycin**...with **no improvement** (perhaps worsened?)

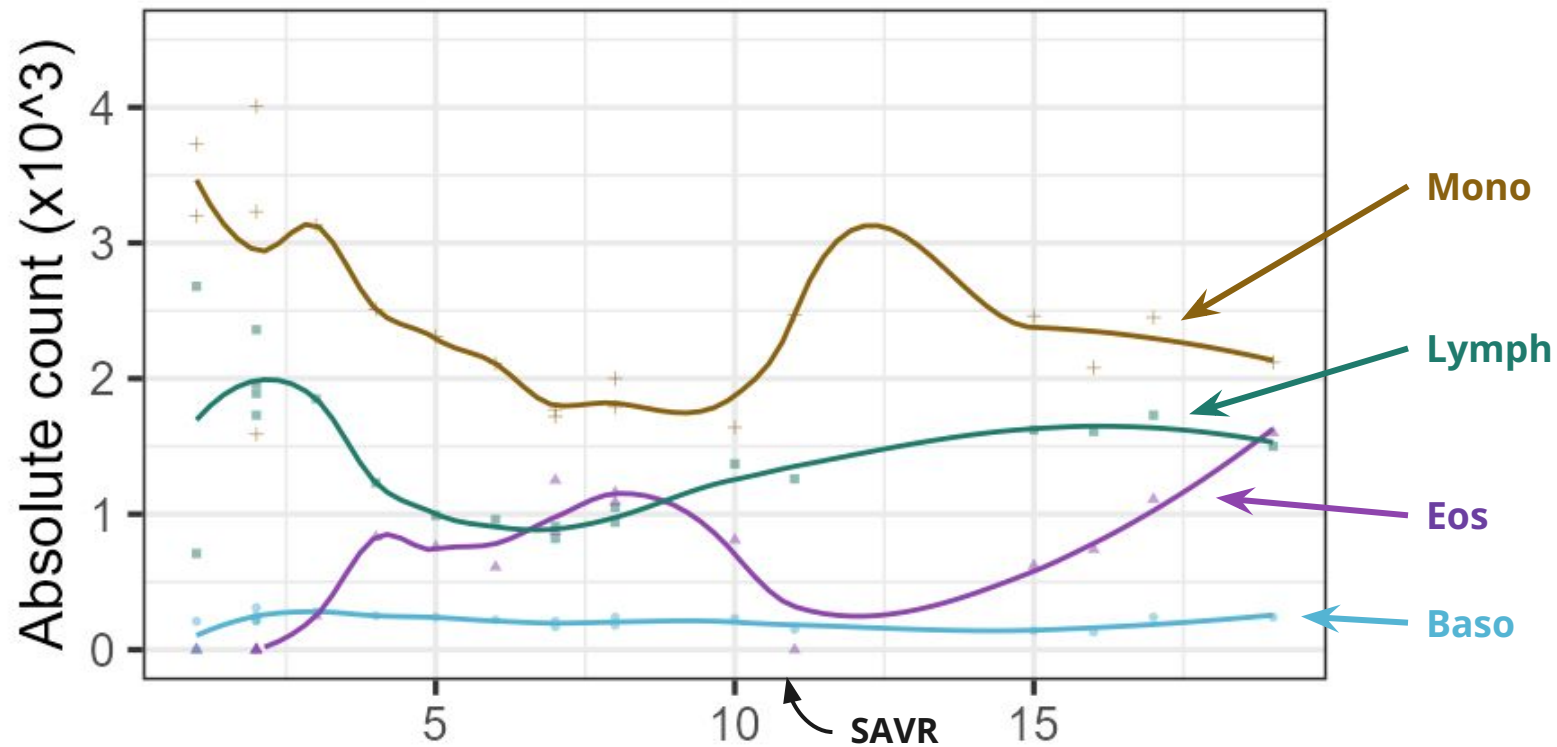
- Still asymptomatic
- Eosinophils still rising



## Case 1: Full differential (w/o neutrophils)

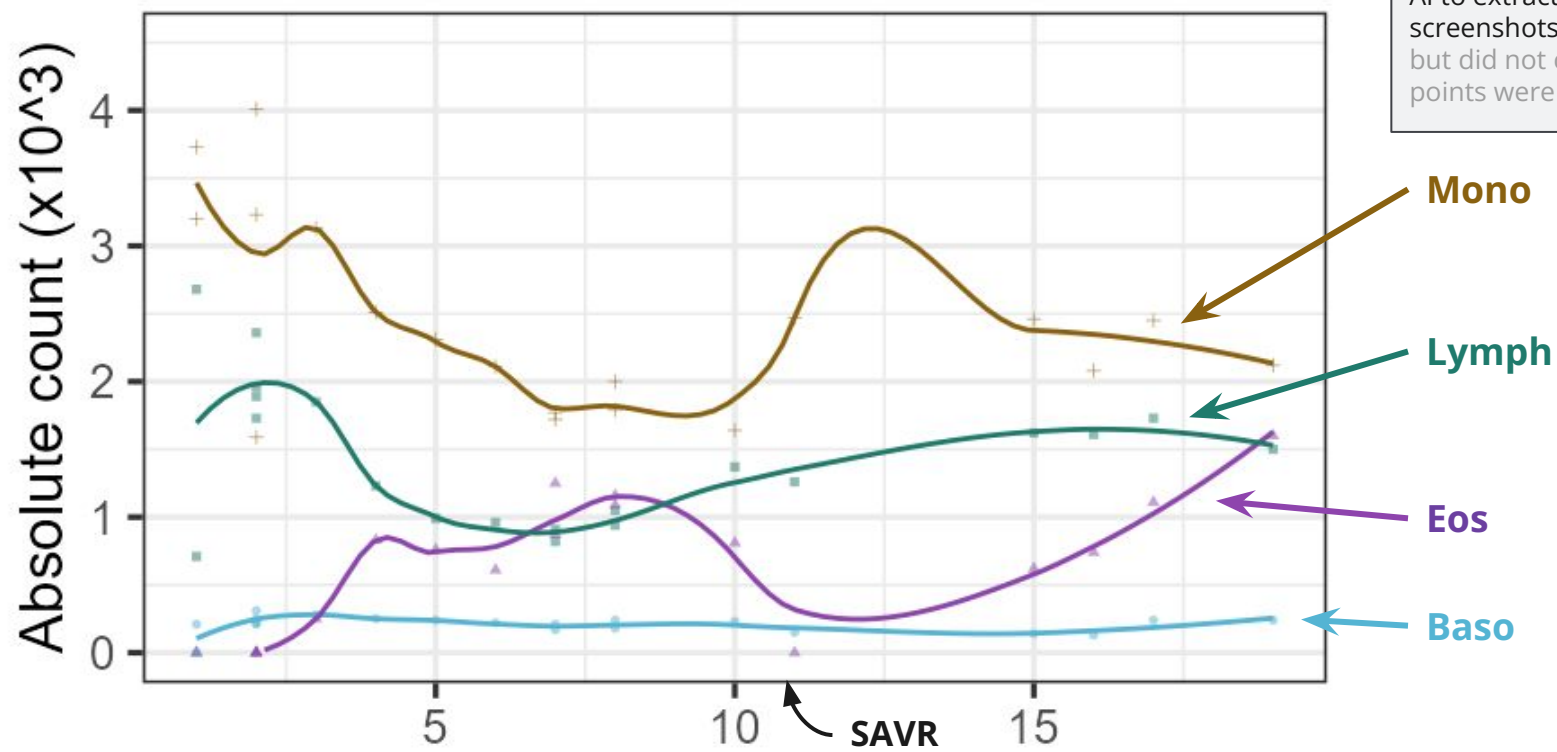


# Case 1: Full differential (w/o neutrophils)



# Case 1: Full differential (w/o neutrophils)

**Disclosure**  
I used a local (non-cloud) form of AI to extract these numbers from screenshots; I spot checked them, but did not confirm all 1000 data points were read correctly



## Case 1: OPAT

---

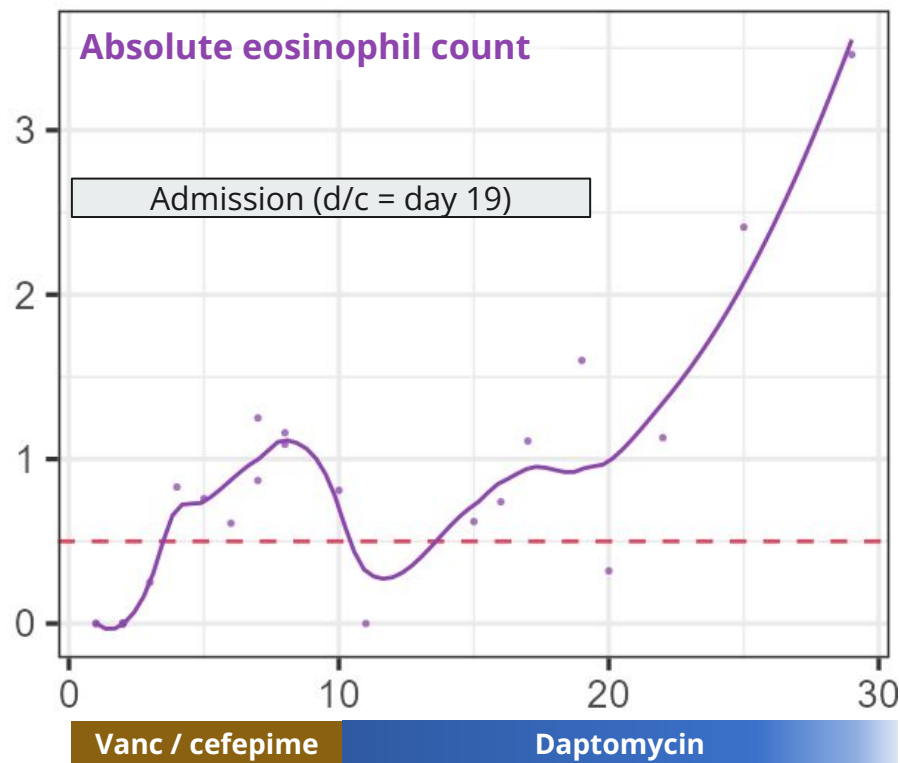
- Discharged to SNF
- Having nose bleeds (Brilinta)
- No other concerns (per staff at SNF)

## Case 1: OPAT

- Discharged to SNF
- Having nose bleeds (Brilinta)
- No other concerns (per staff at SNF)

Those eosinophils **just keep on rising**

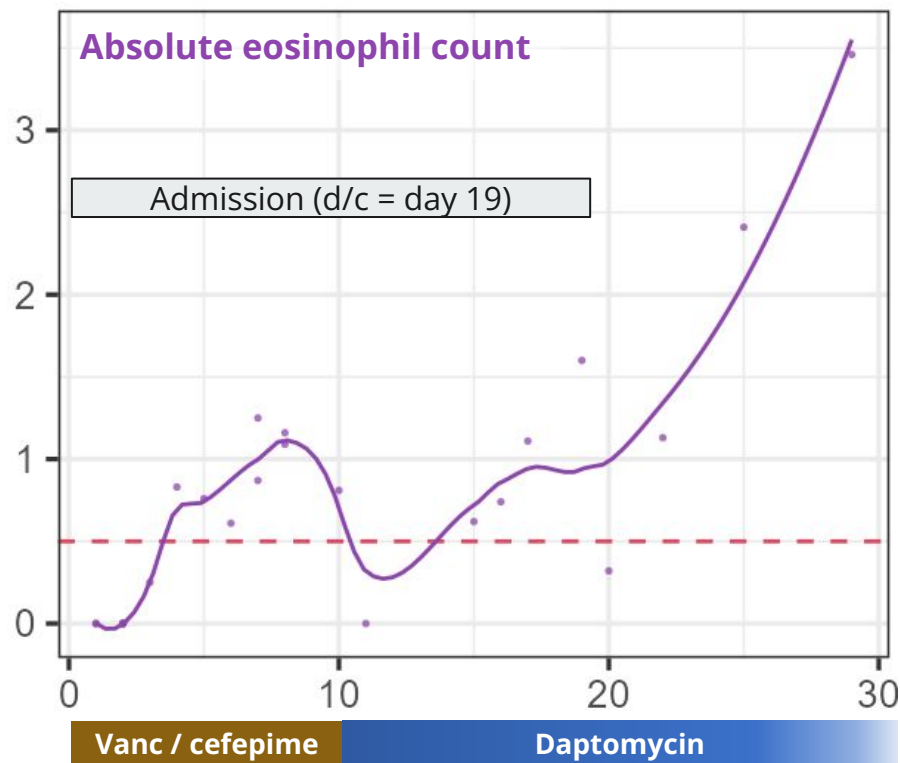
- Now at **3500**



## Case 1: OPAT

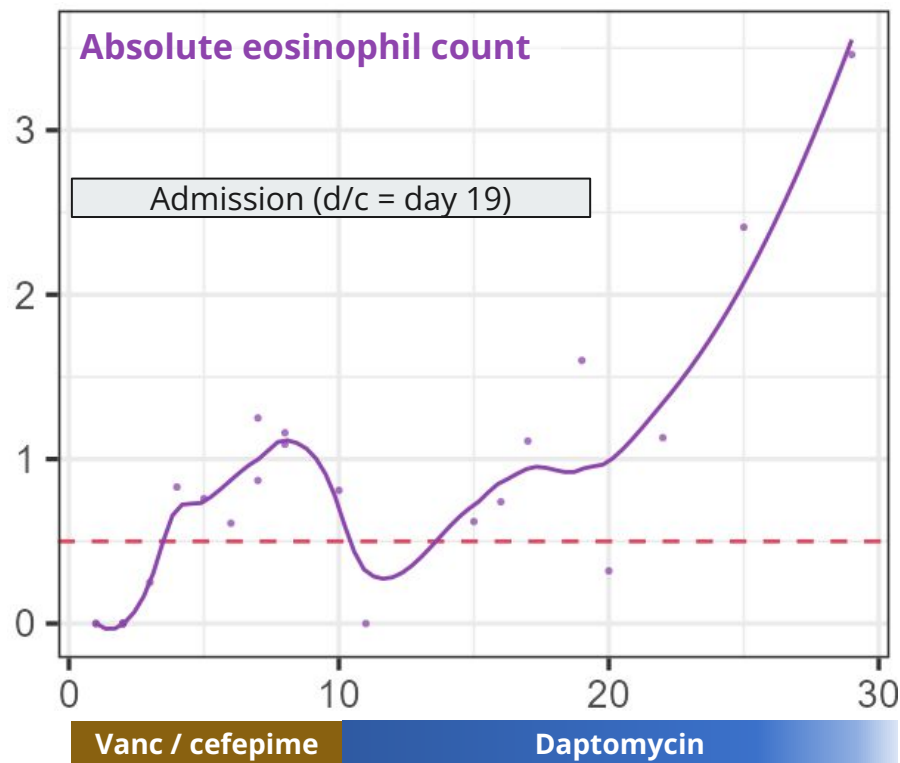
Labs	Day 17
WBC	20.6
Abs neut	14.9
Abs eos	1.1
CRP	35
AST	---
ALT	---
AlkPhos	---
Days since SAVR	7

← Shortly before discharge



## Case 1: OPAT

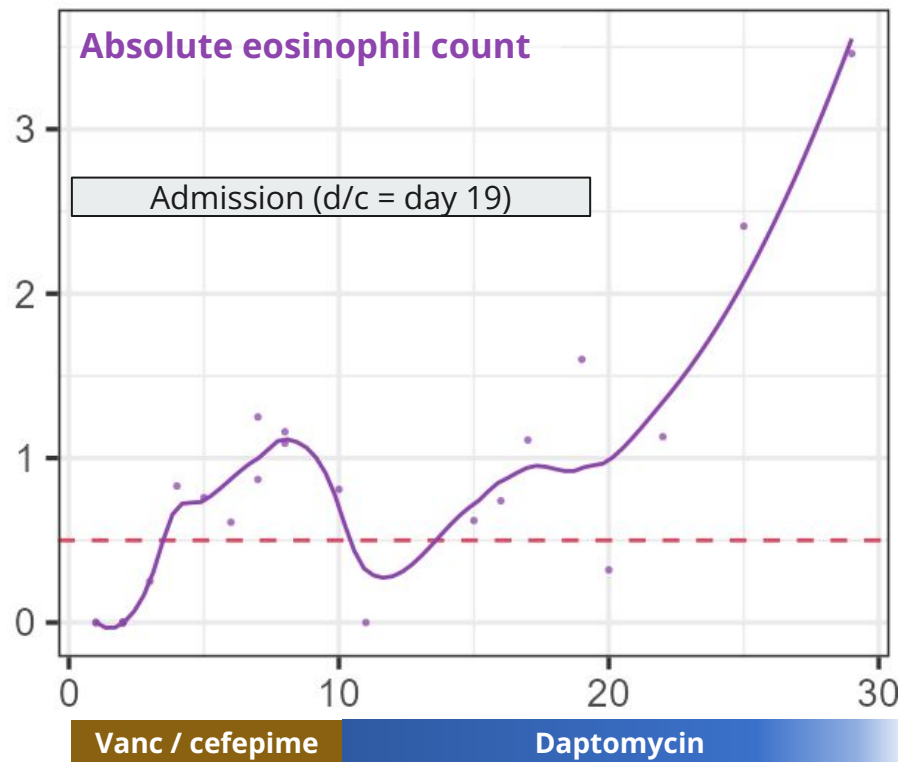
Labs	Day 17	D22	D25
WBC	20.6	18.9	17.7
Abs neut	14.9	15.5	11.6
Abs eos	1.1	1.2	<b>2.4</b>
CRP	35	32	---
AST	---	29	25
ALT	---	22	30
AlkPhos	---	71	<b>149</b>
Days since SAVR	7	12	15



# Case 1: OPAT

ID clinic follow up

Labs	Day 17	D22	D25	D29
WBC	20.6	18.9	17.7	17.6
Abs neut	14.9	15.5	11.6	11.1
Abs eos	1.1	1.2	<b>2.4</b>	<b>3.5</b>
CRP	35	32	---	13
AST	---	29	25	<b>53</b>
ALT	---	22	30	<b>57</b>
AlkPhos	---	71	<b>149</b>	<b>188</b>
Days since SAVR	7	12	15	19

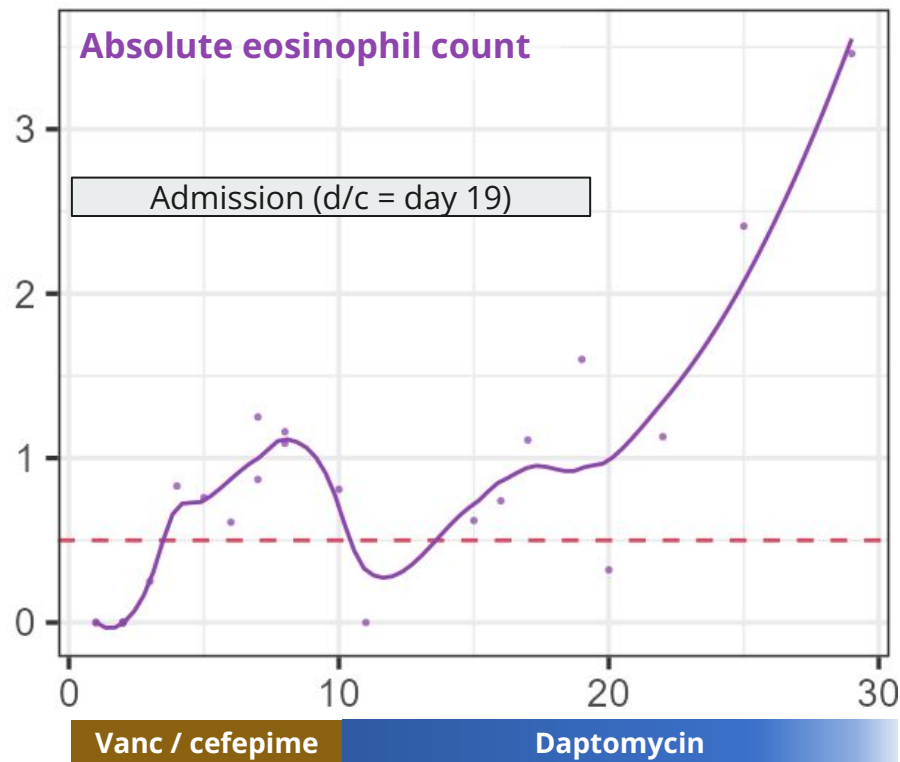


# Case 1: OPAT

ID clinic follow up

Labs	Day 17	D22	D25	D29
WBC	20.6	18.9	17.7	17.6
Abs neut	14.9	15.5	11.6	11.1
Abs eos	1.1	1.2	2.4	3.5
CRP	35	32	---	13
AST	---	29	25	53
ALT	---	22	30	57
AlkPhos	---	71	149	188
Days since SAVR	7	12	15	19

- Normal platelets (200s-300s)
- Chem7 unremarkable
- CK normal (30s)

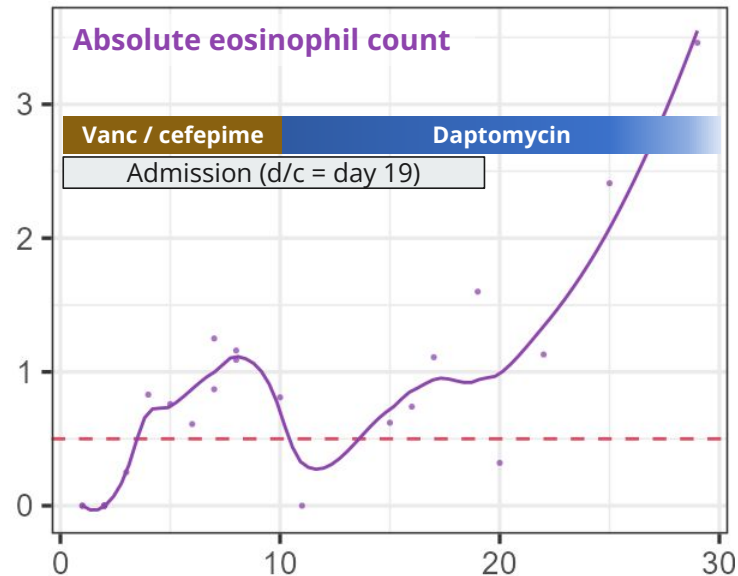


# Case 1: Clinic follow up

A **73 y/o M** with PMH including **CLL** (had port), AAA w/ h/o EVAR, OSA, seizures p/w **native staph epi endocarditis** s/p **SAVR** (day 11). c/f VGI but CTA normal. Developing **profound eosinophilia**...

And **LFT problems**...

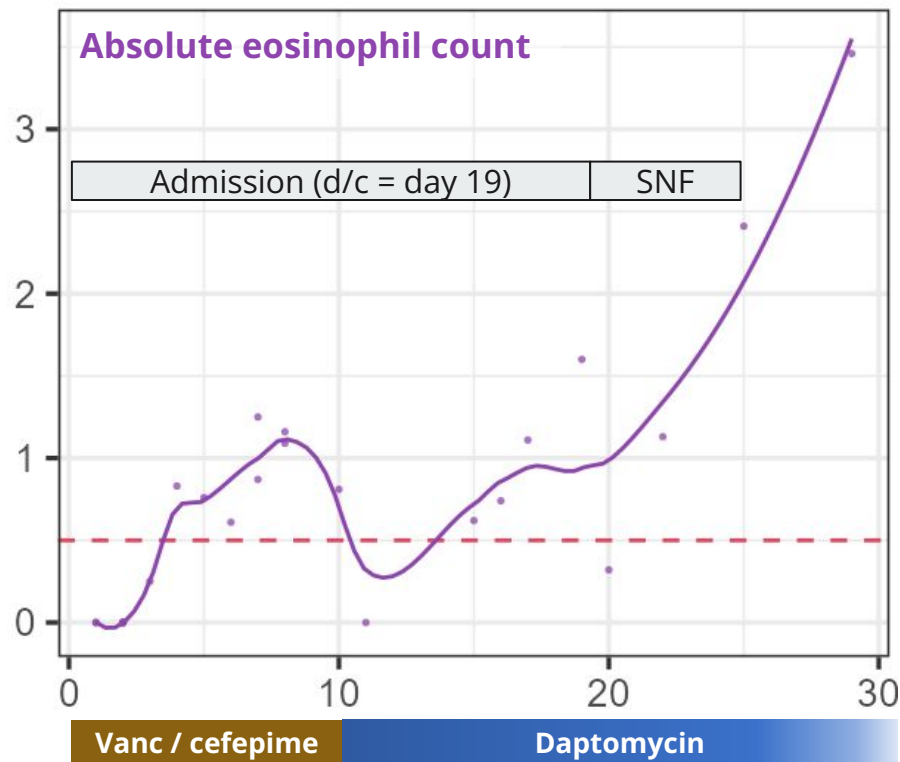
...time to ask about **Drug Reaction with Eosinophilia and Systemic Symptoms**



Recent labs	Day 17	D22	D25	D29
WBC	20.6	18.9	17.7	17.6
Abs eos	1.1	1.2	<b>2.4</b>	<b>3.5</b>
CRP	35	32	---	13
AST	---	29	25	<b>53</b>
ALT	---	22	30	<b>57</b>
AlkPhos	---	71	<b>149</b>	<b>188</b>
Since SAVR	7	12	15	19

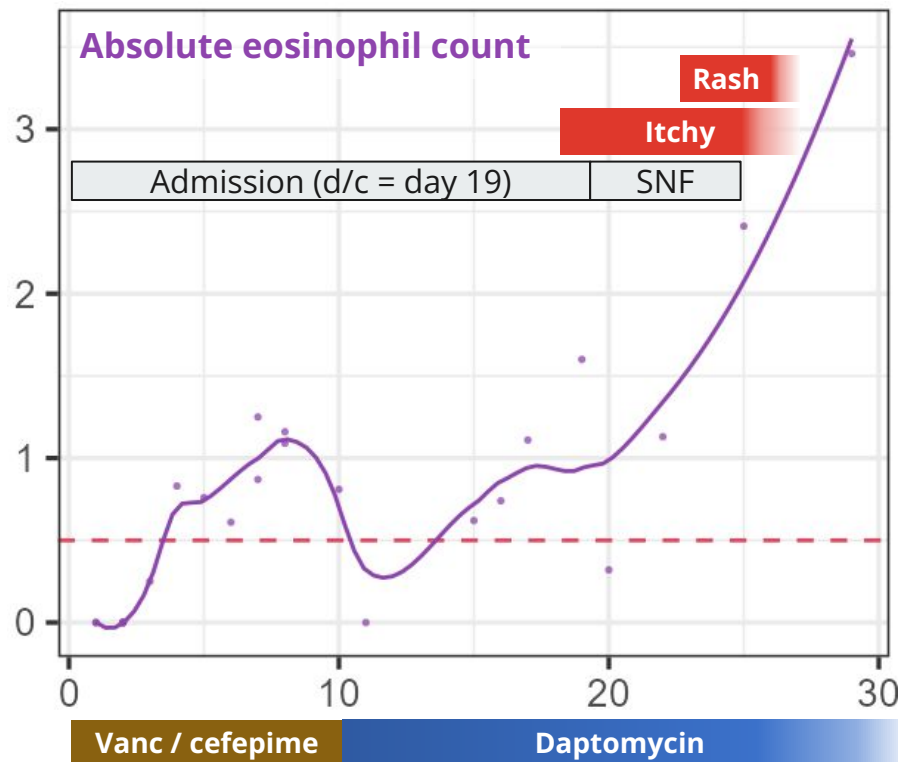
# Case 1: ID clinic follow up

- His **breathing is fine**
  - Though one must assume there are some eosinophils in his lungs...
- His major concern is the nosebleeds



# Case 1: ID clinic follow up

- His **breathing is fine**
  - Though one must assume there are some eosinophils in his lungs...
- His major concern is the nosebleeds
- But he has been having an **itchy rash**



## Case 1: ID clinic follow up

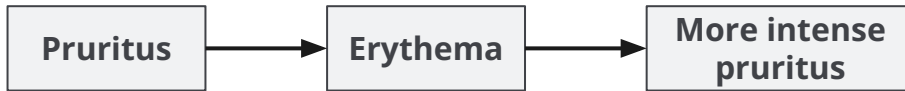

He's had **itchy rashes before** (more on this later), but **never been this severe** before

# Case 1: ID clinic follow up

---

He's had **itchy rashes before** (more on this later), but **never been this severe** before



# Case 1: ID clinic follow up

He's had **itchy rashes before** (more on this later), but **never been this severe** before

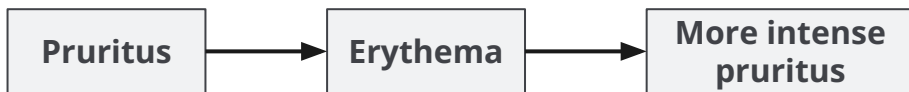

Zero improvement with:

- Topical steroid cream
- Benadryl

# Case 1: ID clinic follow up

He's had **itchy rashes before** (more on this later), but **never been this severe** before



Zero improvement with:

- Topical steroid cream
- Benadryl

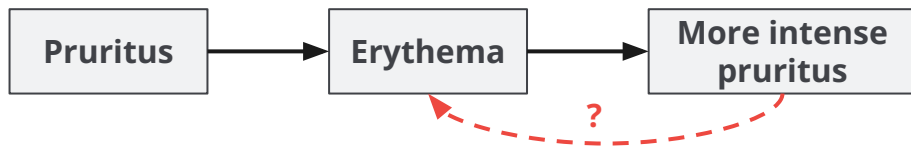
## Rash before abx

**Onset:** Wife informs that he had a minor version of this same rash for maybe a **month before hospitalization**

- Started on **bilateral legs**
- Lesser extent in webs of fingers

# Case 1: ID clinic follow up

He's had **itchy rashes before** (more on this later), but **never been this severe** before



Zero improvement with:

- Topical steroid cream
- Benadryl

## Rash before abx

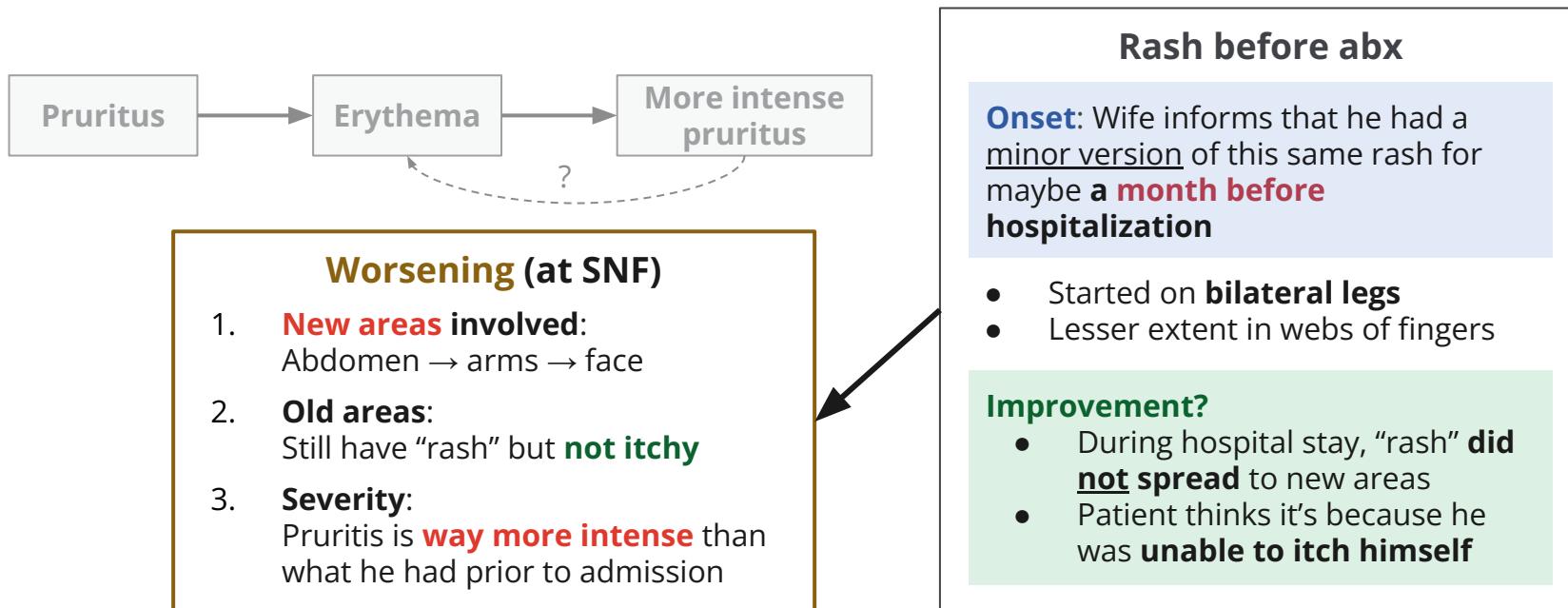
**Onset:** Wife informs that he had a minor version of this same rash for maybe a **month before hospitalization**

- Started on **bilateral legs**
- Lesser extent in webs of fingers

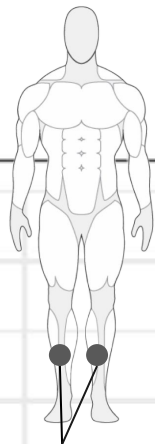
## Improvement?

- During hospital stay, "rash" **did not spread** to new areas
- Patient thinks it's because he was **unable to itch himself**

# Case 1: ID clinic follow up



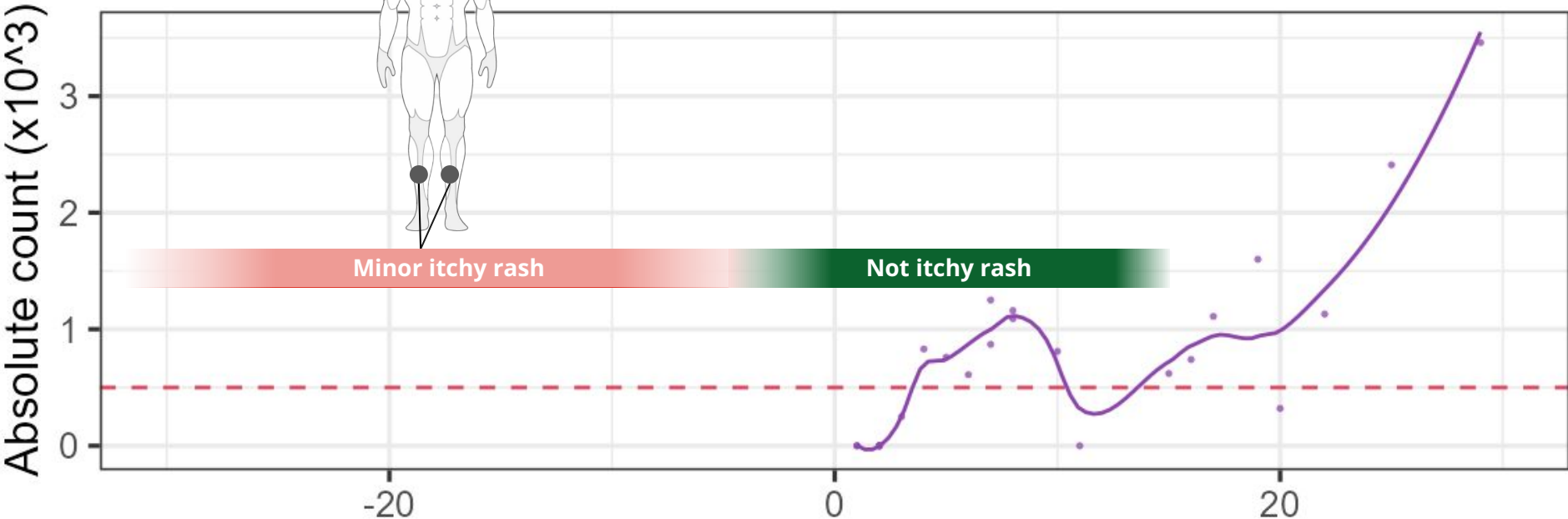
# Case 1: Rash timeline



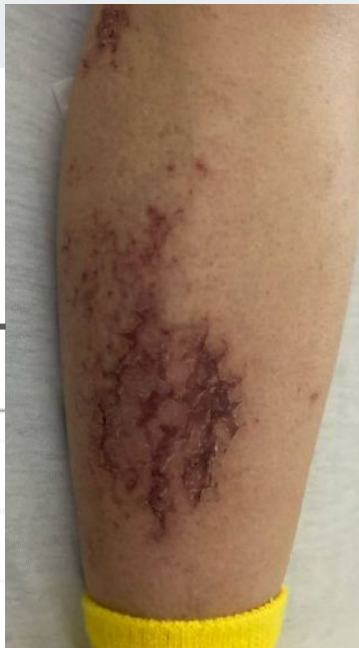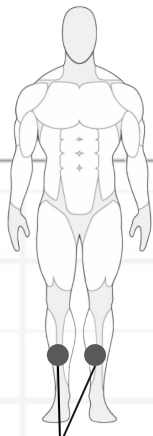
**Rash before abx**

**Onset:** Wife informs that he had a minor version of this same rash for maybe a **month before hospitalization**

- Started on **bilateral legs**
- Lesser extent in webs of fingers



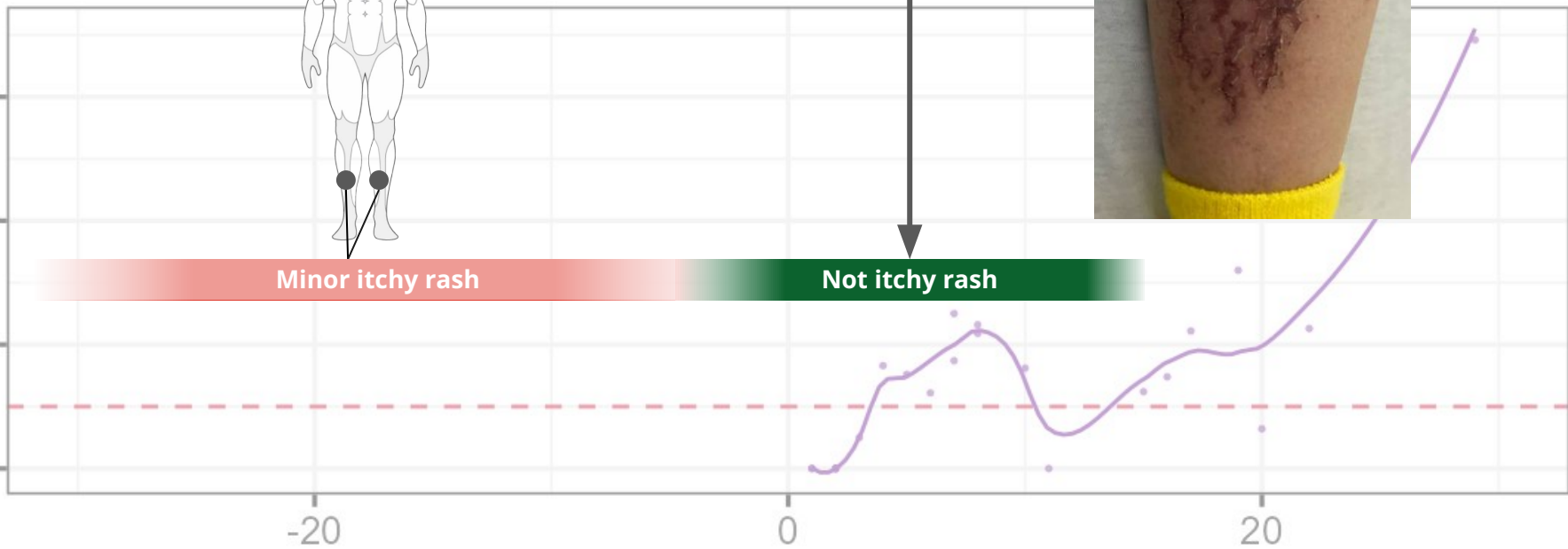
# Case 1: Rash timeline



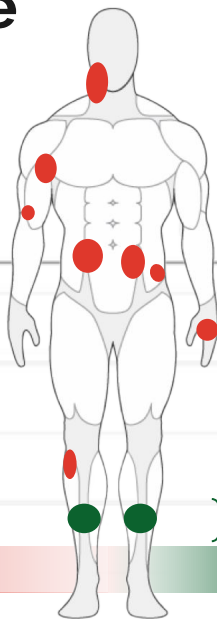
Absolute count ( $\times 10^3$ )

Minor itchy rash

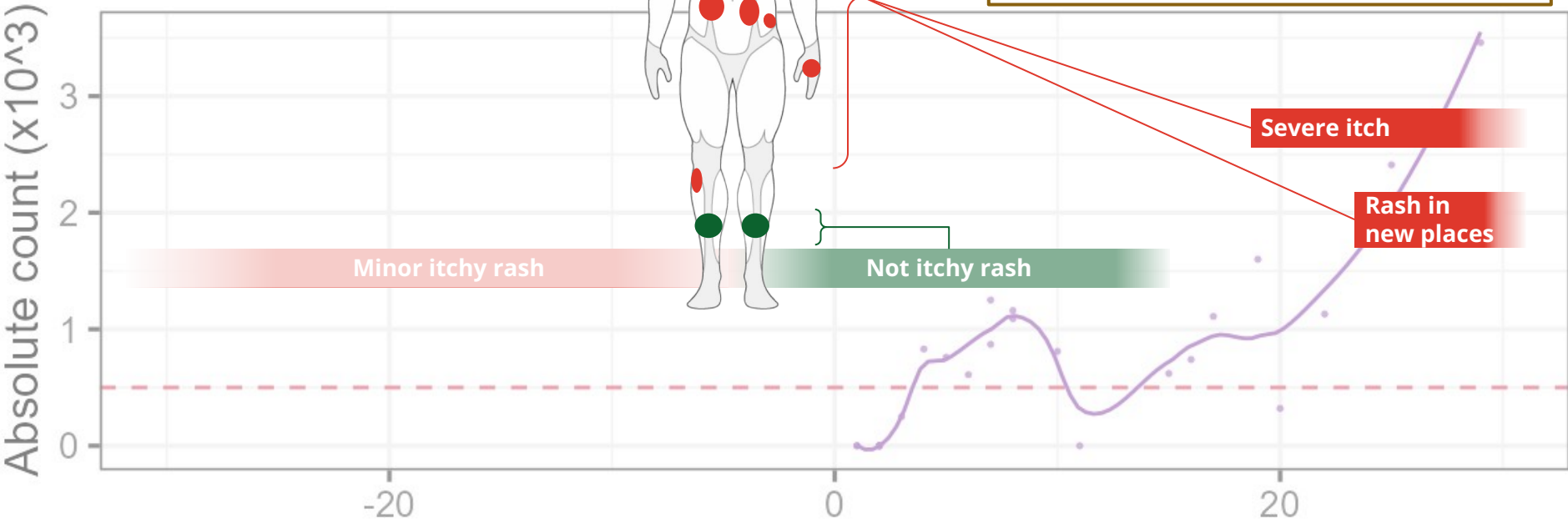
Not itchy rash



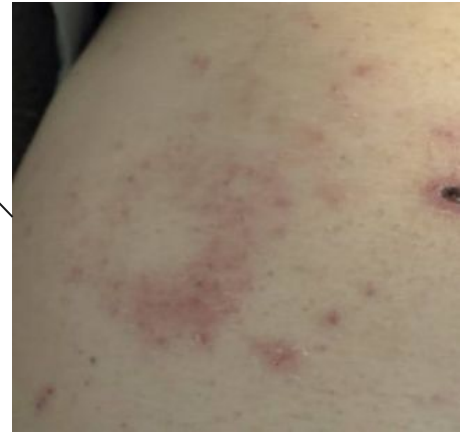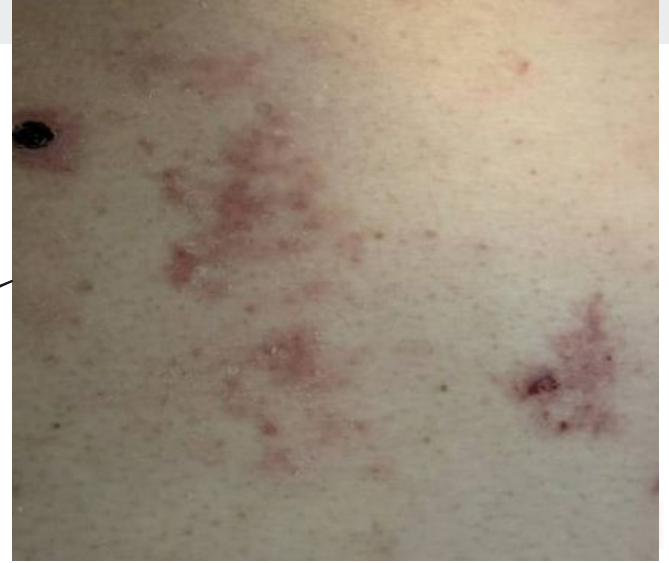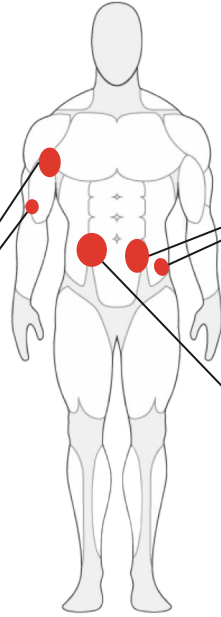
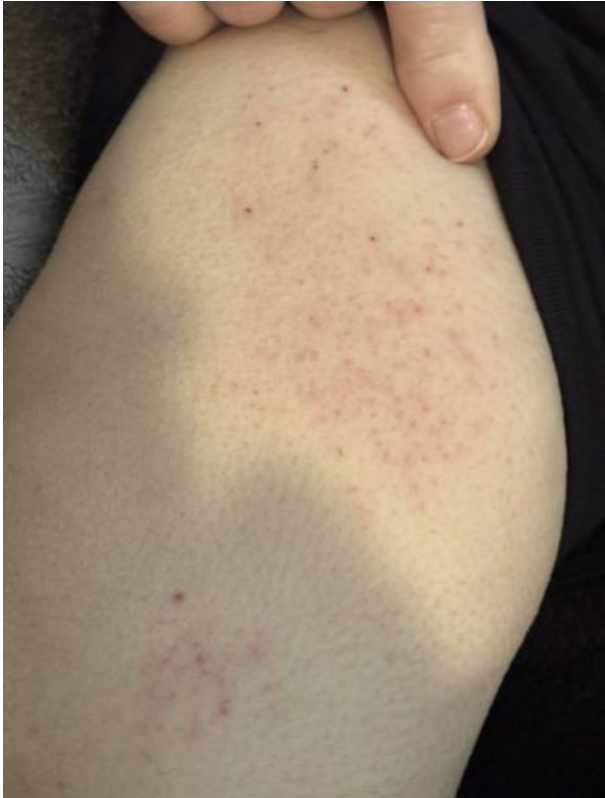# Case 1: Rash timeline



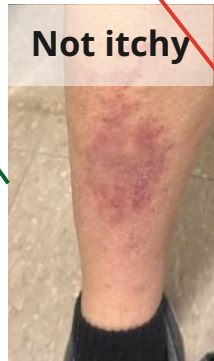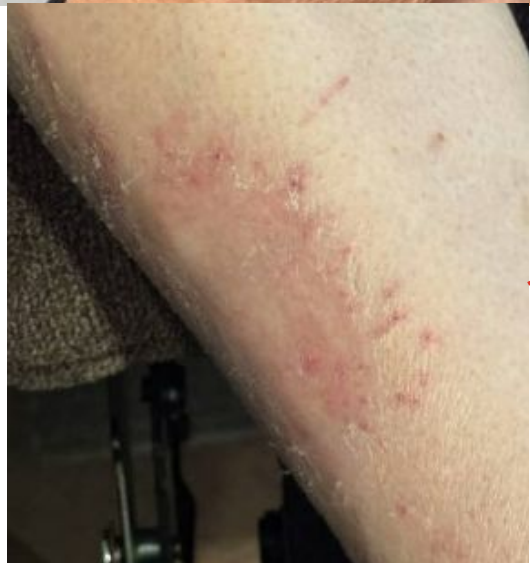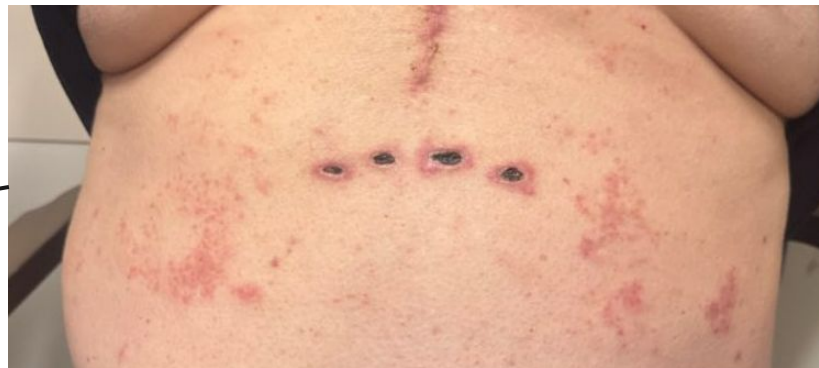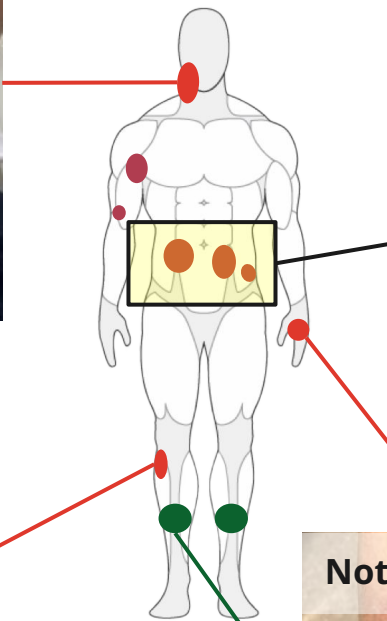
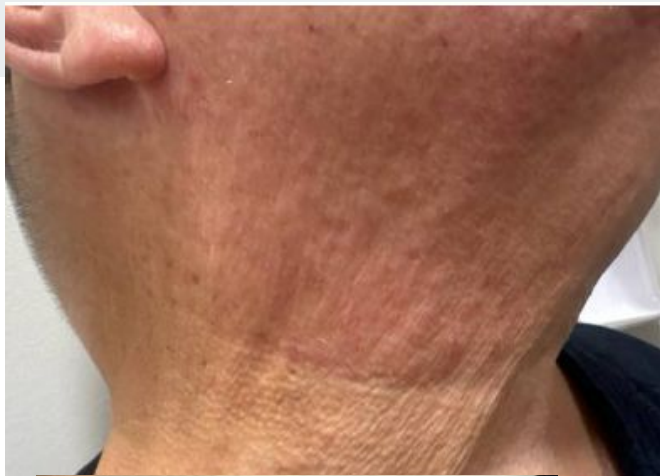
- Worsening (at SNF)**
1. New areas involved:  
Abdomen → arms → face
  2. Old areas: **no longer itchy**
  3. Severity: Pruritis is **way more intense**



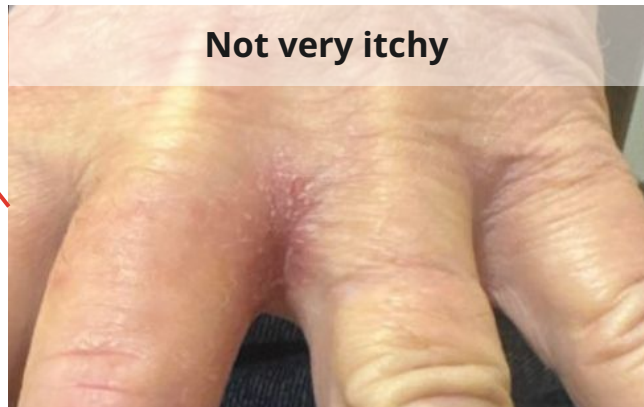## Case 1: Exam



**Blanching rashes**

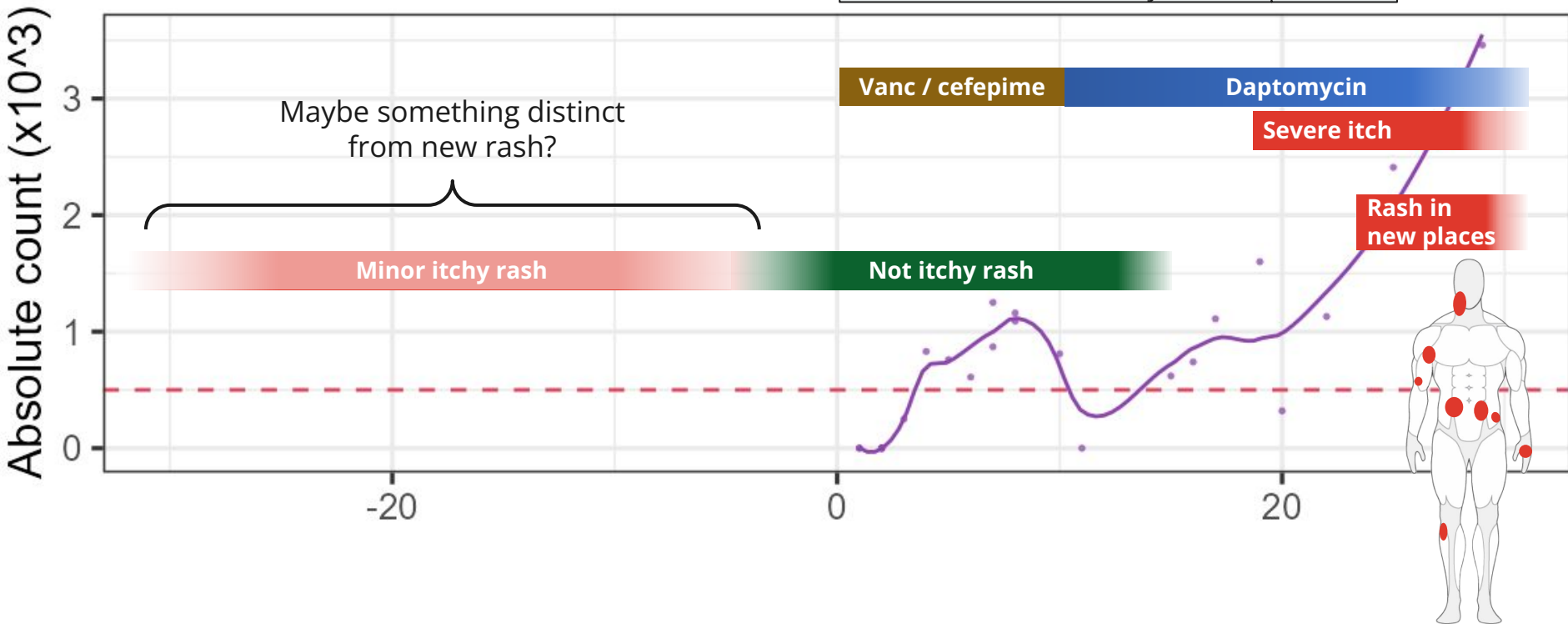


Not itchy



Not very itchy

# Case 1: Rash timeline



# Case 1: Social history, exposures, & risk factors



## Geographic & Travel

- Lives on Ohio/WV border with wife of 35+ years
- No recent travel, never out of the country

## Case 1: Social history, exposures, & risk factors



<b>Geographic &amp; Travel</b>	<ul style="list-style-type: none"><li>• Lives on Ohio/WV border with wife of 35+ years</li><li>• No recent travel, never out of the country</li></ul>
<b>Occupational</b>	<ul style="list-style-type: none"><li>• No longer working</li><li>• Doesn't spend much time outdoors anymore (<b>used to hunt</b>, but not as much in recent years; none this season)</li></ul>

## Case 1: Social history, exposures, & risk factors

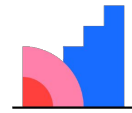


<b>Geographic &amp; Travel</b>	<ul style="list-style-type: none"><li>• Lives on Ohio/WV border with wife of 35+ years</li><li>• No recent travel, never out of the country</li></ul>
<b>Occupational</b>	<ul style="list-style-type: none"><li>• No longer working</li><li>• Doesn't spend much time outdoors anymore (<b>used to hunt</b>, but not as much in recent years; none this season)</li></ul>
<b>Animals</b>	<ul style="list-style-type: none"><li>• Denies farm animal exposures, bird/reptile exposures, or other animal exposure (aside from their pet dog)</li></ul>

## Case 1: Social history, exposures, & risk factors

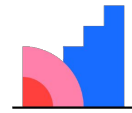
<b>Geographic &amp; Travel</b>	<ul style="list-style-type: none"><li>• Lives on Ohio/WV border with wife of 35+ years</li><li>• No recent travel, never out of the country</li></ul>
<b>Occupational</b>	<ul style="list-style-type: none"><li>• No longer working</li><li>• Doesn't spend much time outdoors anymore (<b>used to hunt</b>, but not as much in recent years; none this season)</li></ul>
<b>Animals</b>	<ul style="list-style-type: none"><li>• Denies farm animal exposures, bird/reptile exposures, or other animal exposure (aside from their pet dog)</li></ul>
<b>Medications</b>	<ul style="list-style-type: none"><li>• Has been on Lamictal (seizures) and aspirin (CAD) for &gt;8 years</li><li>• Started on <b>Brilinta</b> on admission (~day 1) after had PCI</li><li>• Started on <b>amio</b> (post-SAVR) for A-fib</li><li>• <u>Allergy</u>: Bactrim causes rash, no issues with other antibiotics in the past</li></ul>

[Q4] What is  
causing the rash?



**Mentimeter**

**[Q5] Eosinophilia:  
How high is too  
high?**

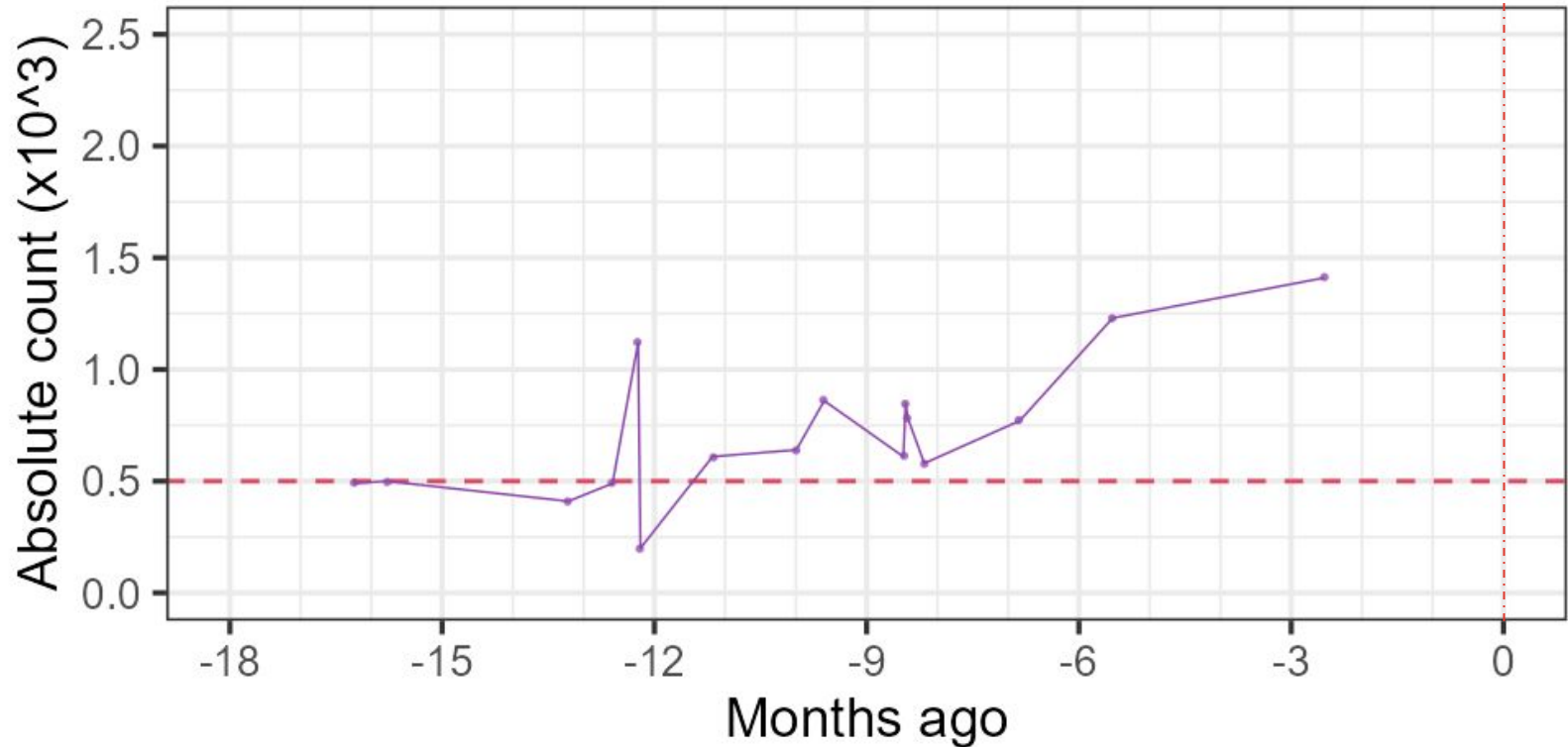


**Mentimeter**

Assuming no symptoms

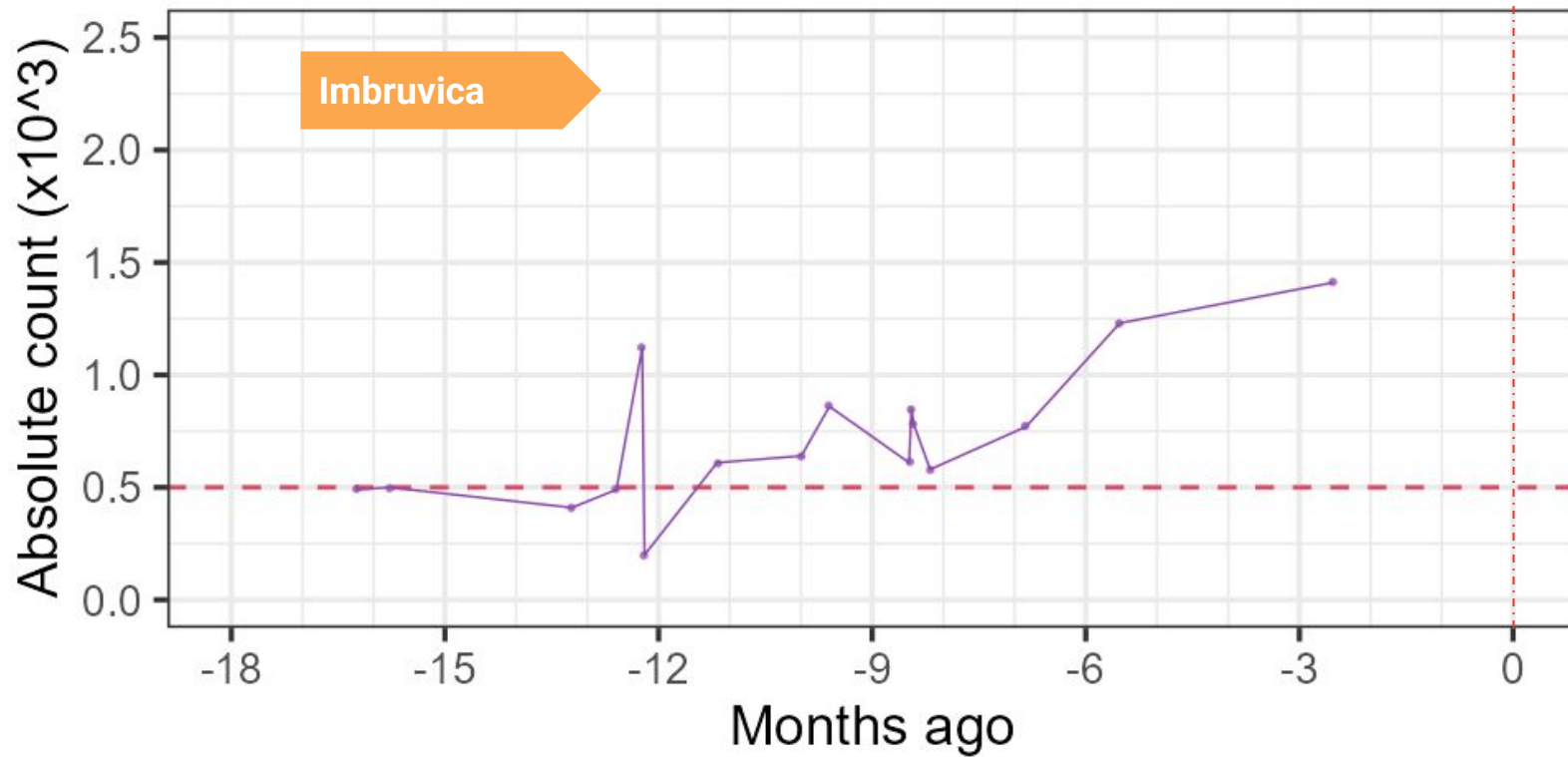
## Case 1: Eosinophilia is not *exactly* new...

IE admission

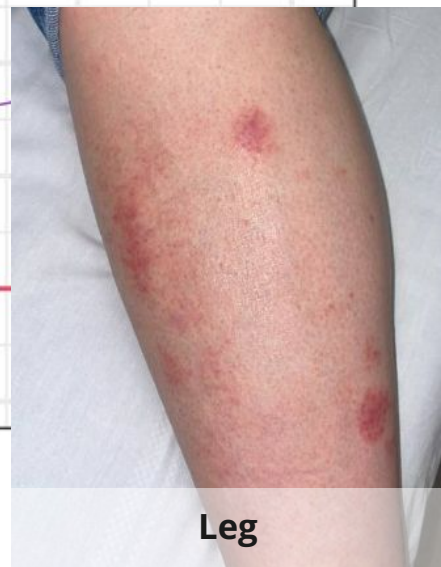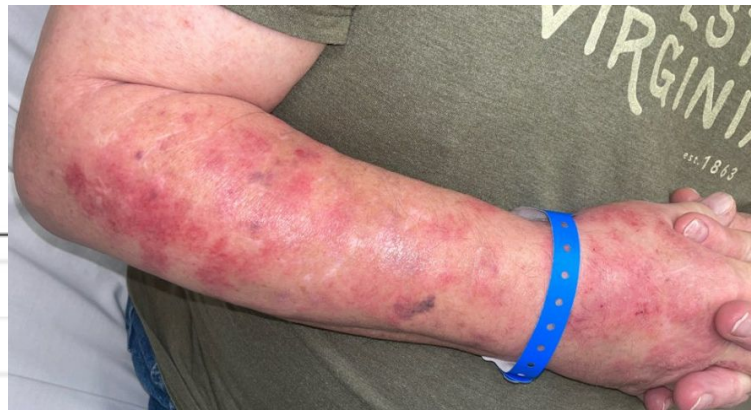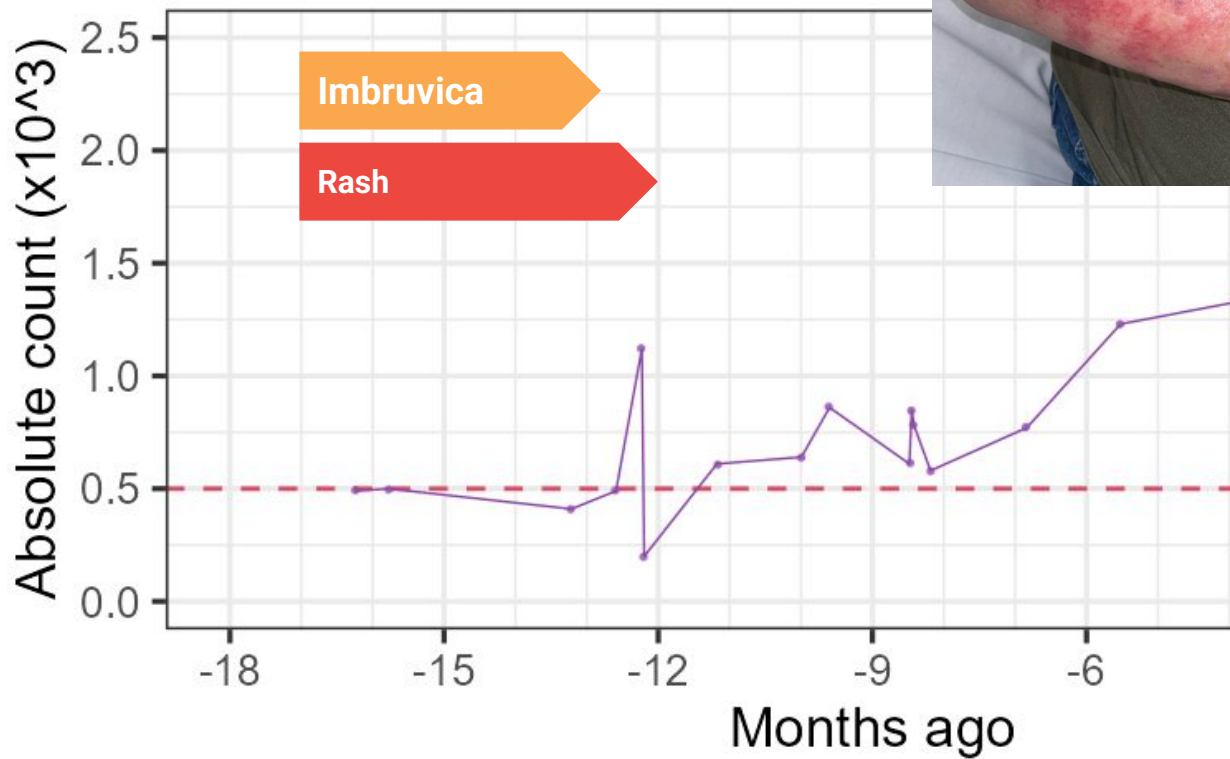


**Imbruvica**  
(ibrutinib)

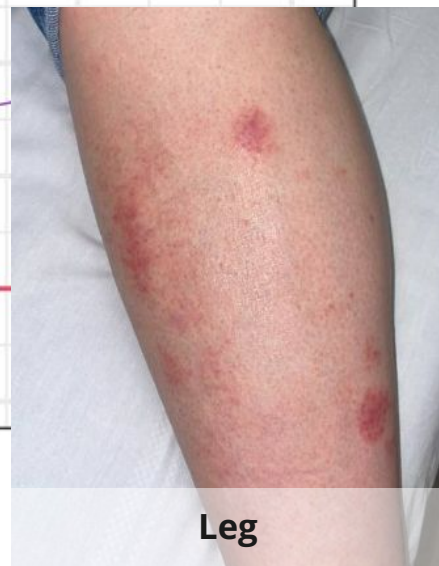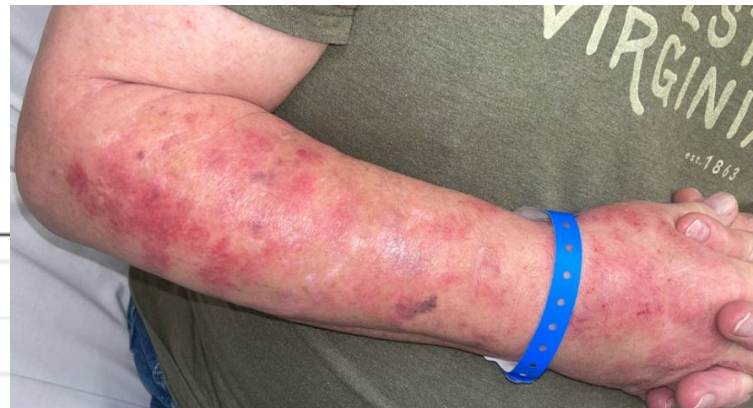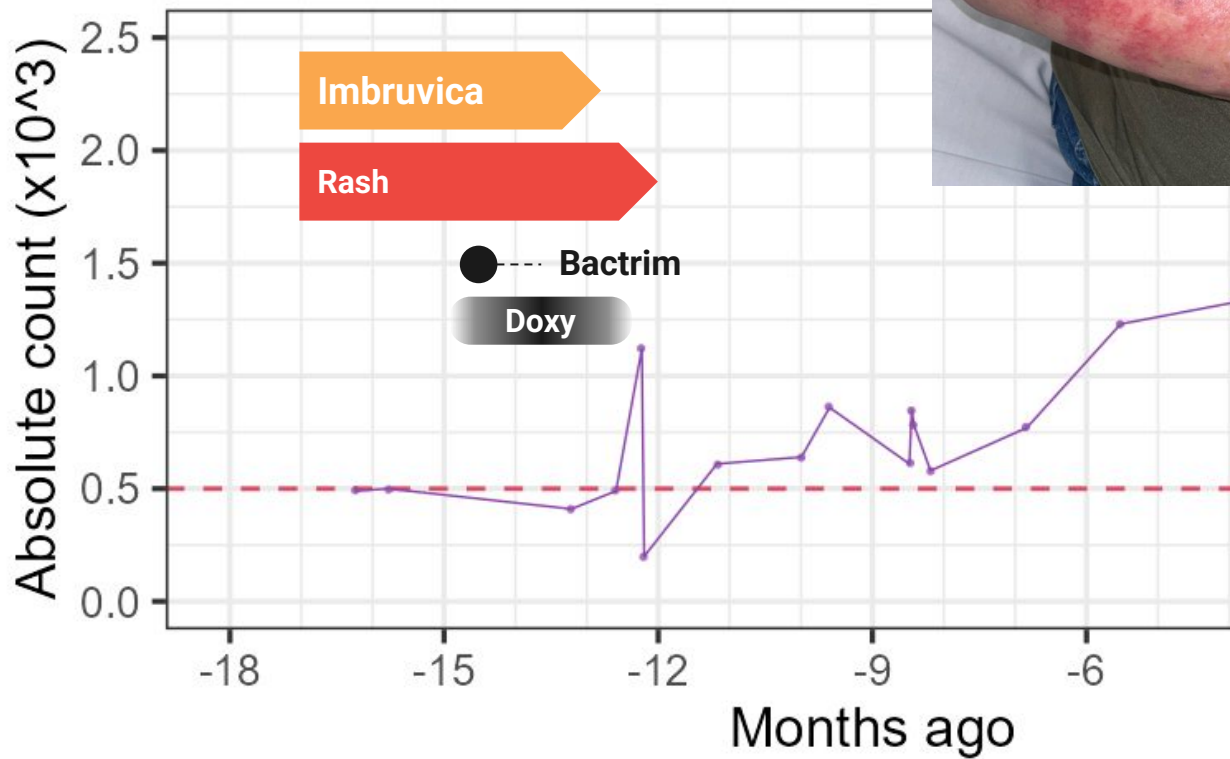
**IE admission**



## Imbruvica (ibrutinib)

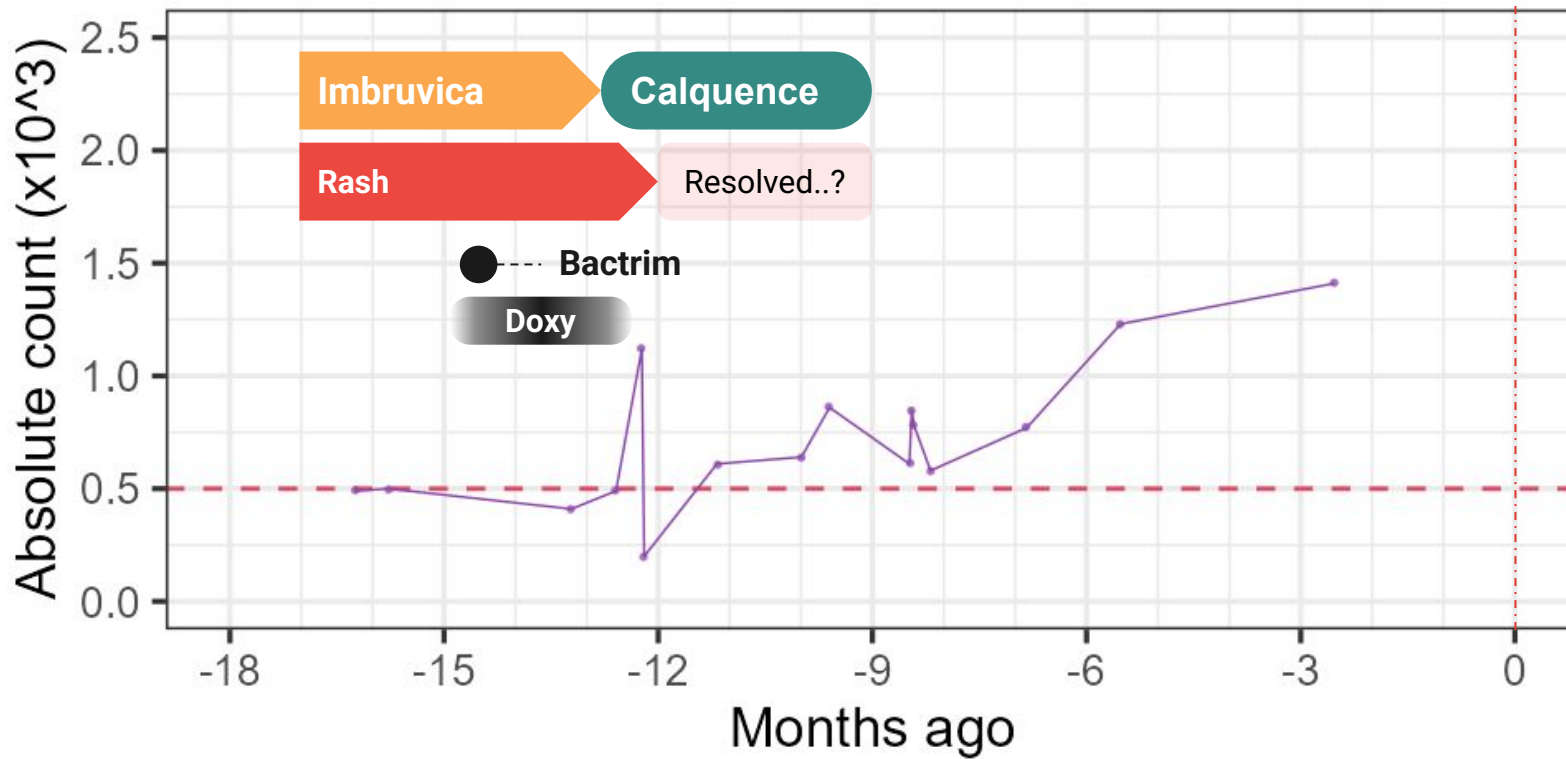


# Imbruvica (ibrutinib)

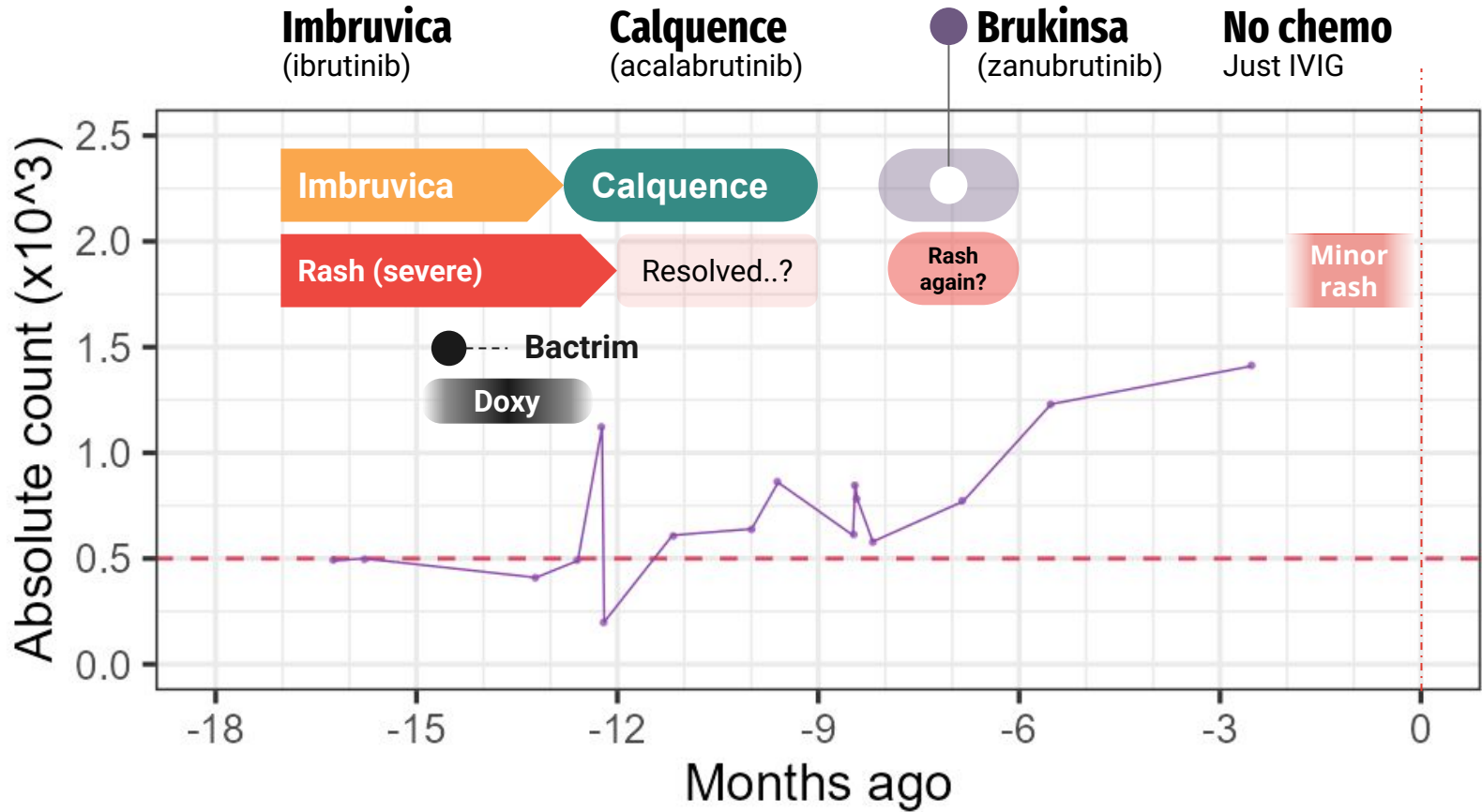


**Imbruvica**  
(ibrutinib)

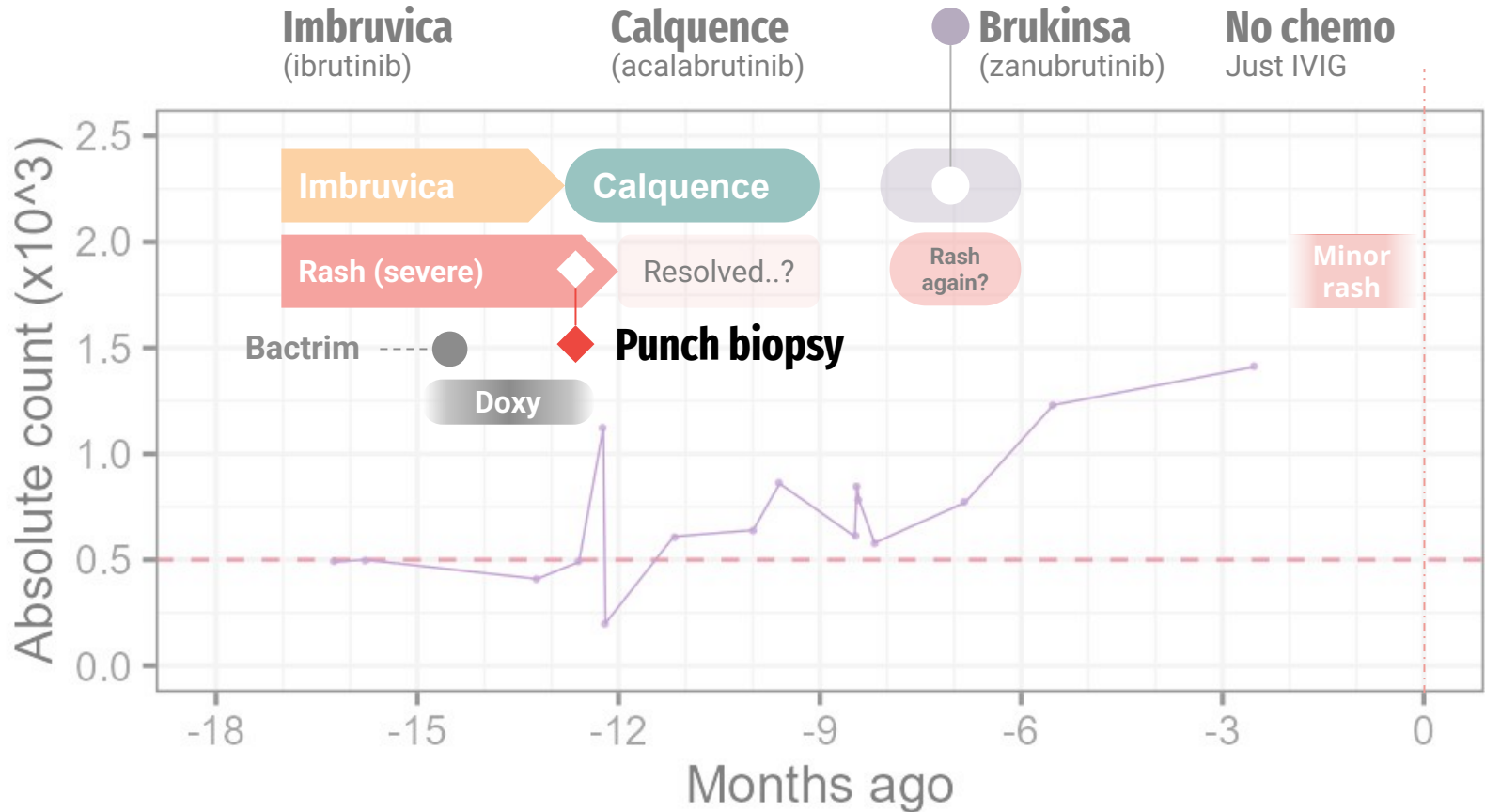
**Calquence**  
(acalabrutinib)



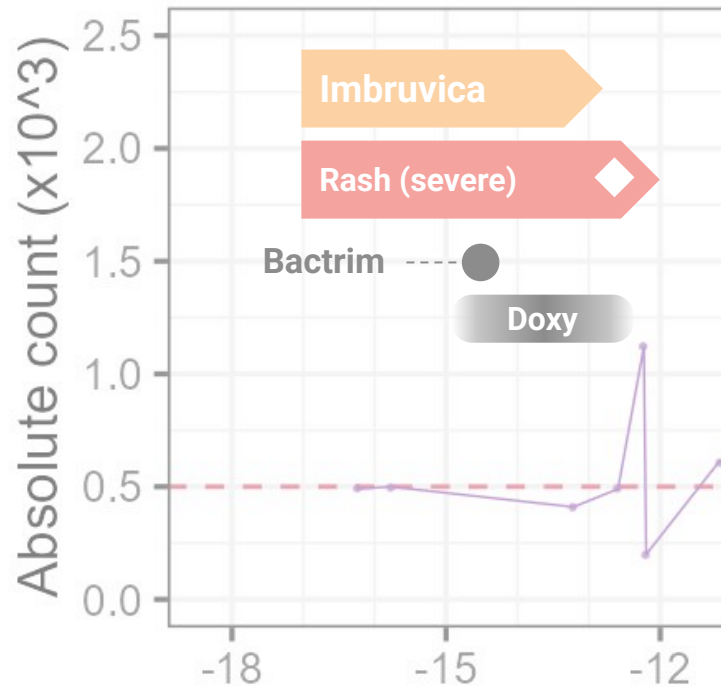
Bruton's tyrosine kinase (BTK) inhibitors



# Bruton's tyrosine kinase (BTK) inhibitors



## Case 1: Old Bx



### ◆ Punch biopsy of arm

**Subacute spongiotic dermatitis** with **superficial lymphocytic cell infiltrates** and **actinic changes**, see Comment

These findings are **entirely non-specific** and those of a subacute to chronic spongiotic dermatitis with superficial predominant perivascular infiltrates associated (possibly secondarily) with actinic damage. Eczematized actinic keratosis is possible; but Epic indicates this biopsy is a portion of a broader eruption. A **spongiotic drug eruption is a possibility**, or even an erythema reaction due to rubbing may also be explain these histopathologic findings.

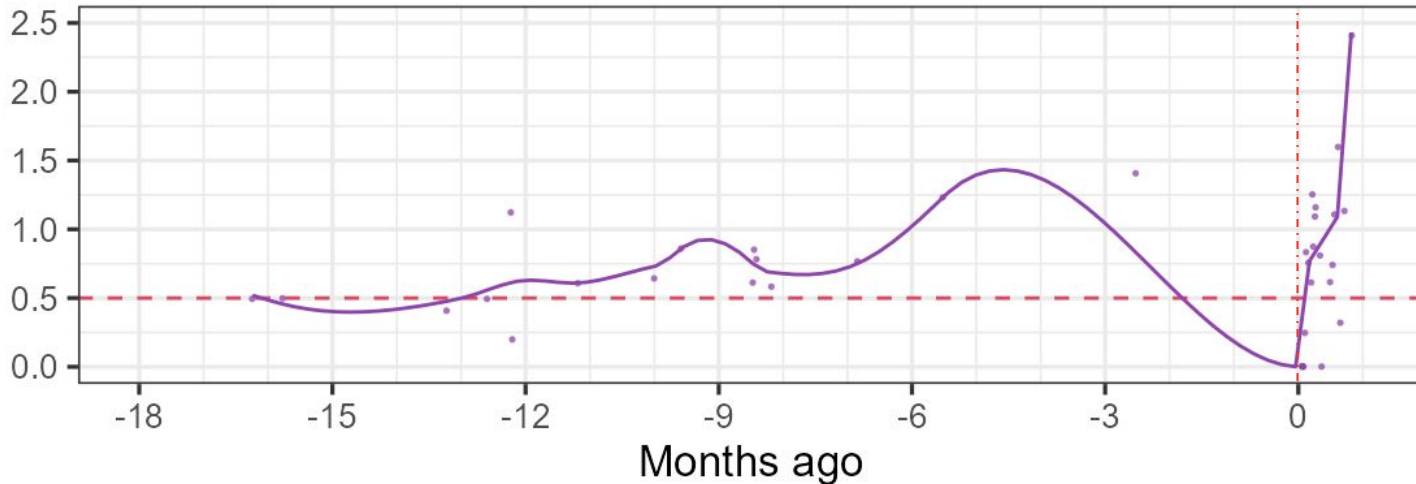
There are **no overt tumoral infiltrates** to suggest a fully developed leukemia cutis. A connective tissue disorder is unlikely but cannot be excluded with complete surety. These histopathological features would **not be characteristically seen** in subacute cutaneous lupus nor Sweet's syndrome. The direct immunofluorescence studies are nonspecific.

# Case 1: ID clinic follow up

Did not suspect issues to be related to antibiotics

- Still **changed to Zyvox** (hard to continue dapto with eosinophils > 2k)

Strongly advised **prompt hematology follow up**



# MARS call #2

Artemis II Commander Reid Wiseman  
peers out Orion's main cabin windows,  
as the crew travels towards the Moon

April 2nd, 2026

Image credit: JSC/NASA



## MARS #2: HPI

You are called after **multiple crew members** of the **ISS** have come down with **progressive respiratory symptoms**



**Artemis II lunar flyby**, captured three minutes before the Orion spacecraft went behind the Moon  
[Credit](#): NASA (4/6/2026 19:41 EDT)

## MARS #2: HPI



A few months into an **ISS expedition** (mission **month 2.5**), two of the six crew members developed **productive cough** and **dyspnea**

# MARS #2: HPI

---

A few months into an **ISS expedition** (mission **month 2.5**), two of the six crew members developed **productive cough** and **dyspnea**

For the **past six days**, two of the crew members have been feeling ill

- **Three days ago**, one crew member (*Crew A*) **developed fevers**
- **Today**, that same crew member developed **increased work of breathing** and looks pale

# MARS #2: HPI

A few months into an **ISS expedition** (mission **month 2.5**), two of the six crew members developed **productive cough** and **dyspnea**

For the **past six days**, two of the crew members have been feeling ill

- **Three days ago**, one crew member (*Crew A*) **developed fevers**
- **Today**, that same crew member developed **increased work of breathing** and looks pale

<b>Antibiotic</b>	(more ill) <b>Astronaut A</b>	<b>Astronaut B</b>
<b>Augmentin</b>	No improvement	No improvement
<b>Bactrim</b>	No improvement	---
<b>Cipro</b>	---	<b>Mild improvement</b>

## MARS #2: HPI

A few months into an **ISS expedition** (mission **month 2.5**), two of the six crew members developed **productive cough** and **dyspnea** for the past six days. Astronaut B had **mild improvement** with some **Cipro**, but Astronaut A now has **fevers** (for **3 days**) and increased **work of breathing** (1 day), despite **Augmentin** and **Bactrim**

Epi risks	Quite ill	Sick	Healthy	Healthy	Healthy	Healthy
	Crew A	Crew B	Crew C	Crew D	Crew E	Crew F
Toilet repairs	No	Yes	No	Yes	Yes	No
Electric panel repair	Yes	Yes	No	Yes	No	No
EVA?	Yes	Yes	Yes	No	No	Yes
Food source	Lot 1	Lot 1	Lot 1	Lot 2	Lot 2	Lot 2

## MARS #2: HPI

---

A few months into an ISS expedition (mission **month 2.5**), two of the six crew members developed **productive cough** and **dyspnea** for the past six days. Astronaut B had **mild improvement** with some **Cipro**, but Astronaut A now has **fevers** (for **3 days**) and increased **work of breathing** (**1 day**), despite **Augmentin** and **Bactrim**. No clear shared epidemiologic risk factors.

Today (day of consult), exam by the crew medical officer (not a physician)

### Astronaut A

**38.9°C** (102.0°F) | 112 bpm | 108/64 | **91%**

- **Accessory muscle** use
- **Rales in RLL** > LLL;
- ↓ breath sounds RLL

### Astronaut B

**37.8°C** (100.0°F) | 104 bpm | 114/70 | **93%**

- **Coughing** on exam
- Diffuse rhonchi & scattered crackles bilaterally

# MARS 2: Summary

A few months into an **ISS expedition** (mission **month 2.5**), two of the six crew members developed **productive cough** and **dyspnea** for the past six days. No clear shared epidemiologic risk factors

Astronaut B had **mild improvement** with some **Cipro**, but Astronaut A now has **fevers** (for **3 days**) and increased **work of breathing** (**1 day**), despite **Augmentin** and **Bactrim**.

- Do you abort the mission?



Image Credit: NASA/Joel Kowsky (Artemis II Launch)

# MARS: Space is dirty! [1][3]



**Intuition:** The ISS should be clean, like an operating room

# MARS: Space is dirty! [1][3]



**Intuition:** The ISS should be clean, like an operating room

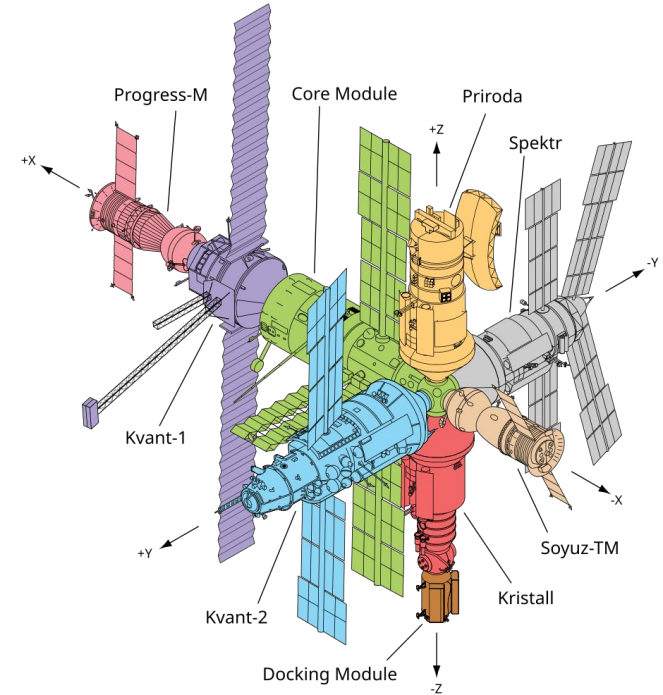
**Reality:** The microbiology of the ISS is much closer to an ICU

Over 15+ years, microbes have really built up

- Mainly skin flora (staph, micrococcus, strep, bacillus)
- But that's not all...!

# MARS: Space is dirty [3]

When NASA removed a **service panel** and **found a humid cloud of condensate**



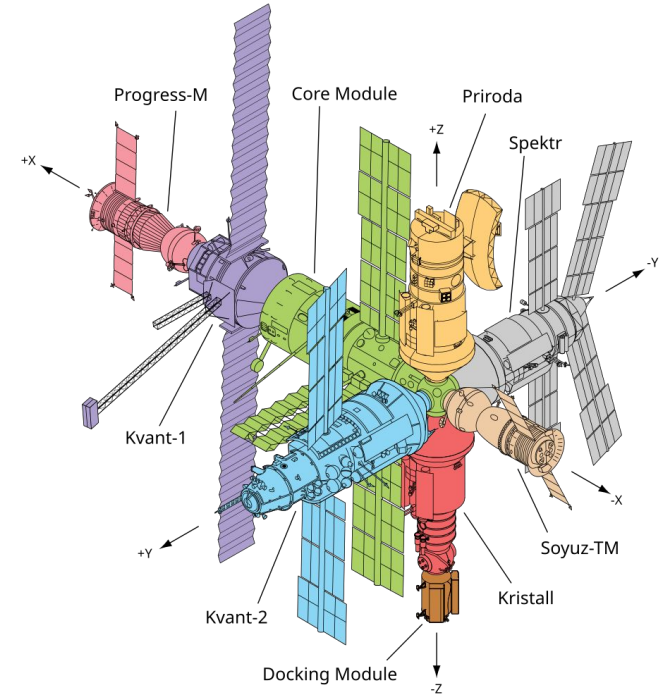
Isolated from Mir in 1998, the first space station (Soviet station)

# MARS: Space is dirty [3]

When NASA removed a **service panel** and **found a humid cloud of condensate**



AI generated image (I have no idea what it looked like)



Isolated from Mir in 1998, the first space station (Soviet station)

Guess what they  
isolated?



# MARS: Space is dirty [3]

Isolated from Mir space station (1998)

- Multiple species of:
  - **Serratia** (*S liquefaciens*, *S marcescens*)
  - **Pseudomonas**
  - **Yersinia**
  - **Corynebacterium** & **Bacillus**
- **Legionella** (x2)
- **Citrobacter frundii** (x2)
- **Enterobacter cloacae**
- **Stenotrophomonas maltophilia**
- **Elizabethkingia meningoseptica**
- **Rhodococcus** species

Space horses?



AI generated image (I have no idea what it looked like)

# MARS: Space is dirty [3]

Isolated from Mir space station (1998)

- Multiple species of:
  - **Serratia** (*S liquefaciens*, *S marcescens*)
  - **Pseudomonas**
  - **Yersinia**
  - **Corynebacterium & Bacillus**
- **Legionella** (x2)
- **Citrobacter freundii** (x2)
- **Enterobacter cloacae**
- **Stenotrophomonas maltophilia**
- **Elizabethkingia meningoseptica**
- **Rhodococcus** species

Space horses?

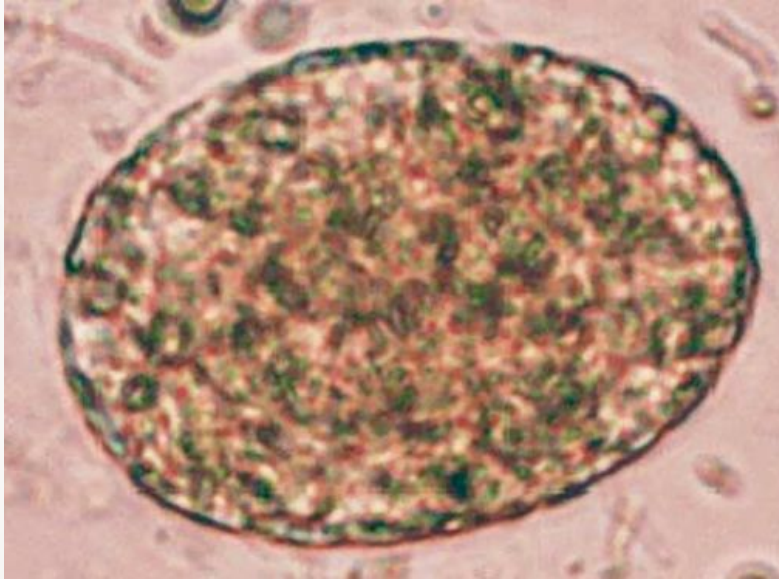
## Fungal

- Multiple species of **Candida**
- **Fusarium** species (x3)
- **Penicillium** species (x3)
- *Rhodotorula rubra* (x3)
- *Cladosporium* species (x2)
- And more

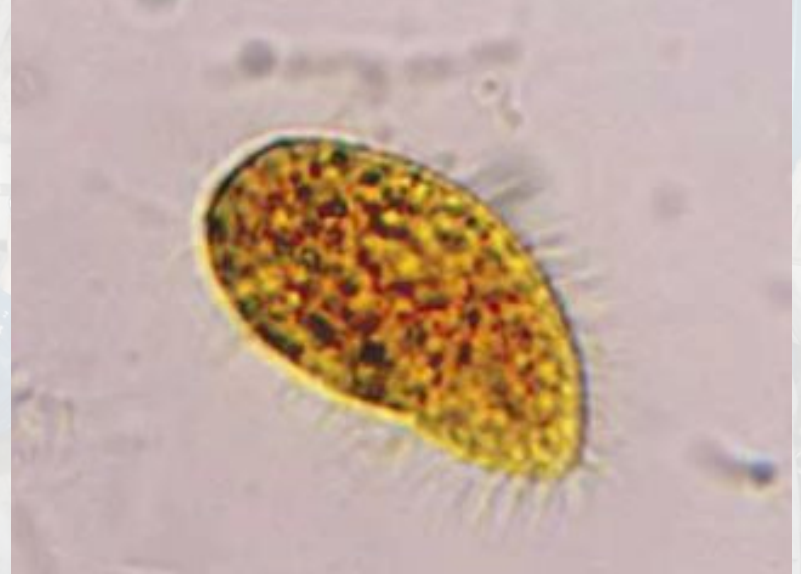

AI generated image (I have no idea what it looked like)

## MARS: Space is dirty [3]



**Amoeba** resembling *Acanthamoeba* or *Hartmanella* species



**Ciliated protozoa** resembling *Stylonychia* species

# MARS: Space is dirty [3]

Isolated from Mir space station (1998)

- Multiple species of **Serratia**, **Pseudomonas**, **Yersinia**, **Corynebacterium**, & **Bacillus**
- **Legionella** (x2)
- **Citrobacter frundii** & **Enterobacter cloacae**
- **Stenotrophomonas** & **Elizabethkingia**
- **Rhodococcus** species
- **Amoeba** & **protozoa**

Fungal

- Multiple species of **Candida**
- **Fusarium** species (x3)
- **Penicillium** species (x3)
- *Rhodotorula rubra* (x3)
- *Cladosporium* species (x2)
- And more

**Lyme? Lepto?**

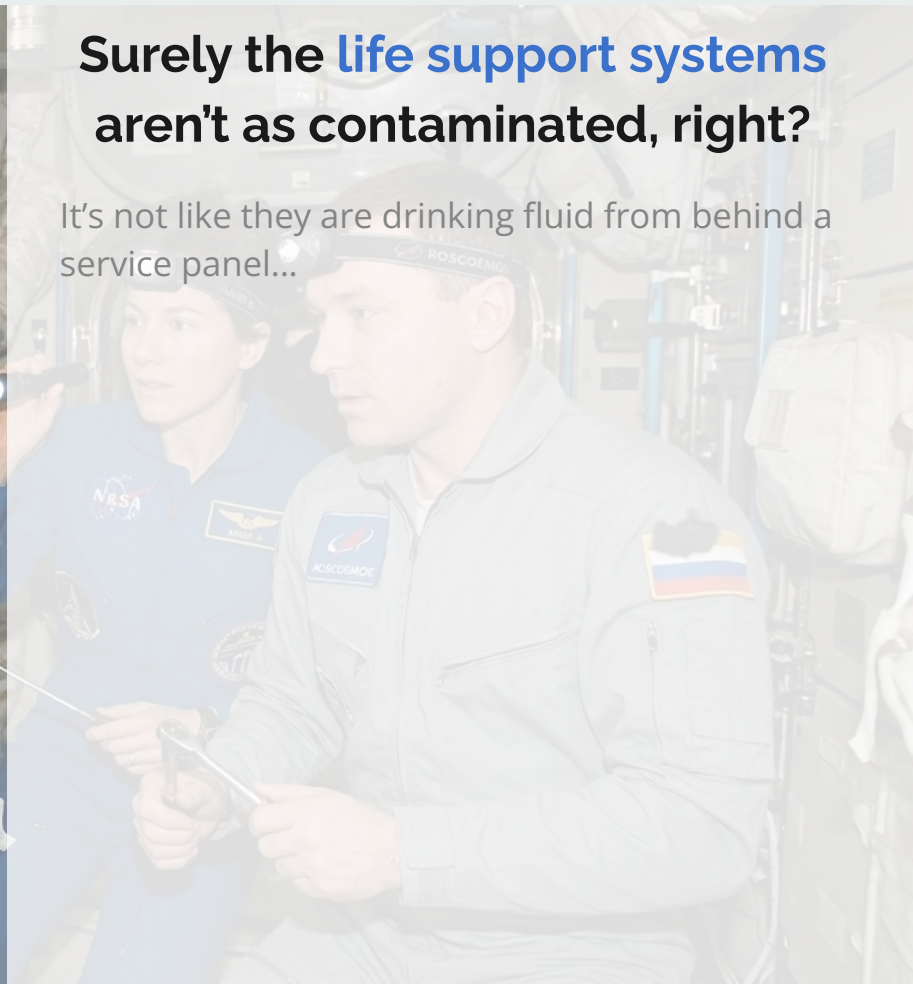
Electron microscopy suggested presence of **spirochetes**

**No mycobacteria** (at least yet)



Surely the **life support systems** aren't as contaminated, right?

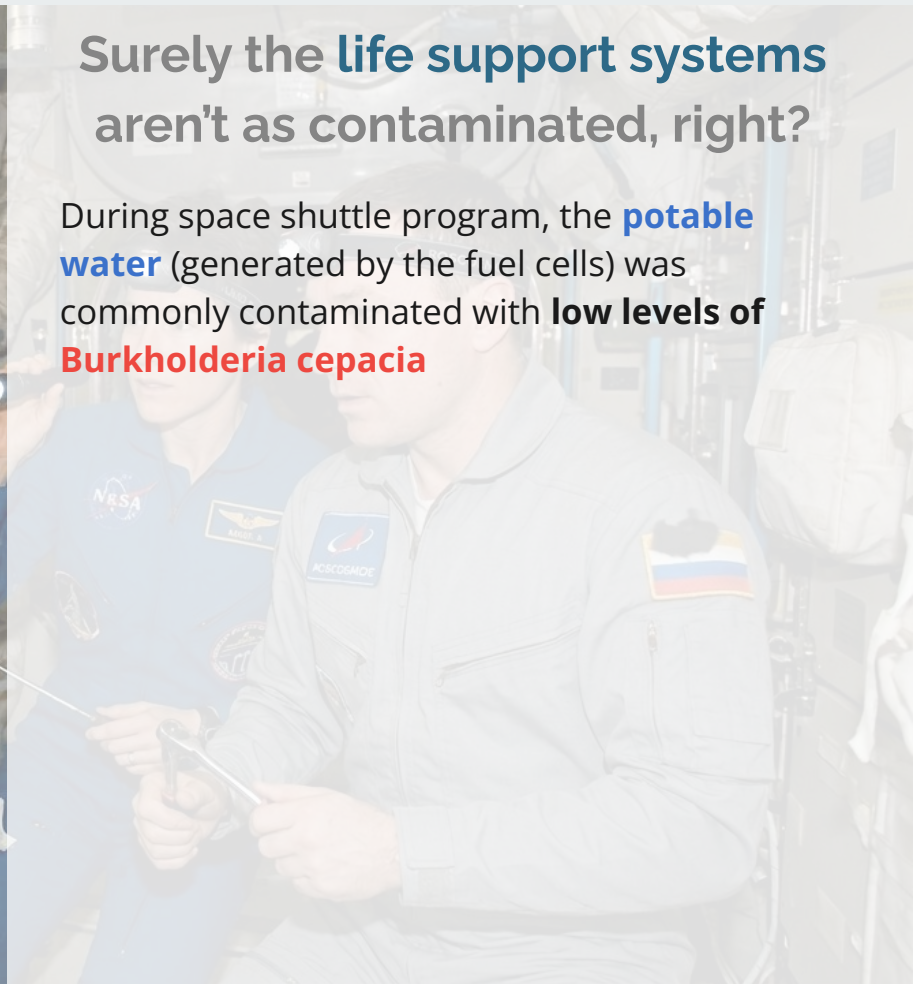It's not like they are drinking fluid from behind a service panel...





Surely the **life support systems** aren't as contaminated, right?

During space shuttle program, the **potable water** (generated by the fuel cells) was commonly contaminated with **low levels of Burkholderia cepacia**





## Outer space or an ICU?

- Pseudomonas
- Steno maltophilia
- Burkholderia
- Serratia, citrobacter, E cloacae
- Candida krusei



Surely the **life support systems** aren't as contaminated, right?

During space shuttle program, the **potable water** (generated by the fuel cells) was commonly contaminated with **low levels of Burkholderia cepacia**

# MARS: Infection Prevention & Control

---



**Standard environmental disinfection** practices (wipes, UV radiation) **do not work** well, because the bacteria are different


Because there is no gravity!

# MARS: Pathogen responses to microgravity [1]

Spaceflight doesn't just affect human physiology, it also affects pathogens too!

## Driven by Lack of Gravity

- **Fluids** are much **more static** (no convection) compared to terrestrial environment



**Artemis II Upper Stage Separation**

[Image credit: NASA \(4/1/2026\)](#)


# MARS: Pathogen responses to microgravity [1]

Spaceflight doesn't just affect human physiology, it also affects pathogens too!

## Driven by Lack of Gravity

- **Fluids** are much **more static** (no convection) compared to terrestrial environment
- Bacteria rely on **passive diffusion** for nutrients and waste removal

Exception: Bacteria with **flagella** **maintain** active transport capabilities



**Artemis II Upper Stage Separation**

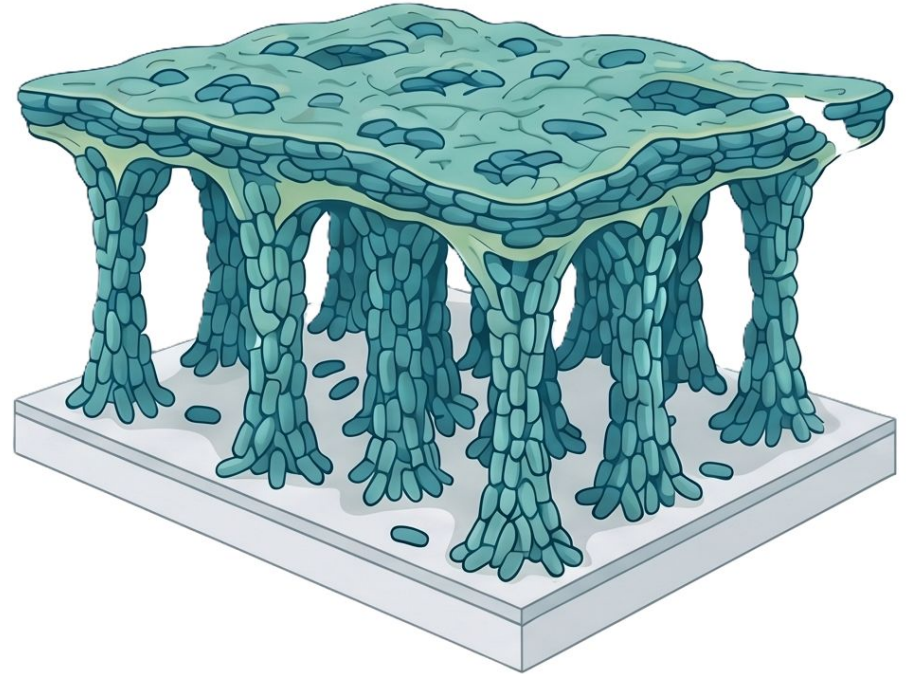
Image credit: NASA (4/1/2026)

# MARS: Pathogen responses to microgravity [1]

**Pseudomonas** overcomes diffusion limitations in microgravity by building **unique biofilms** [4]

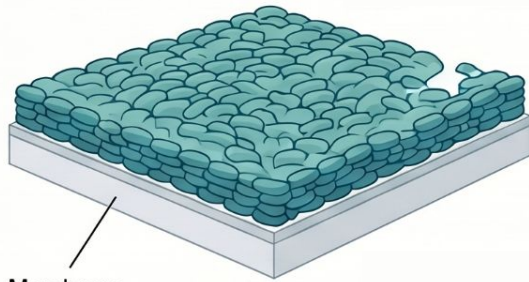
*Structure never seen on Earth:*

- Thicker overall matrix
- **"Column and canopy"** architecture
- Optimized for **nutrient diffusion**





AI generated image (Google NotebookLM)

# EARTH'S STATIC STRUCTURE (Normal Gravity)

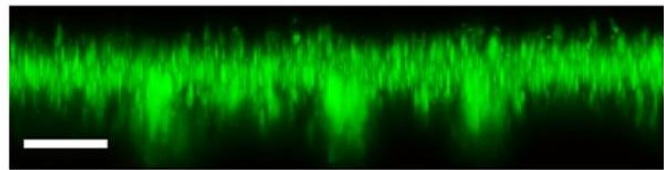
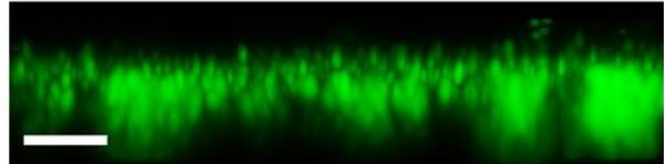
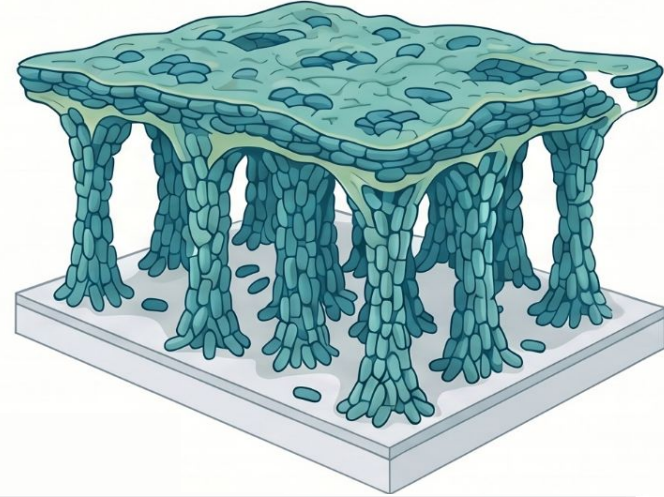


Membrane substrate



Real world data from Kim et al [4]

# THE SPACEFLIGHT "COLUMN-AND-CANOPY" (Microgravity)



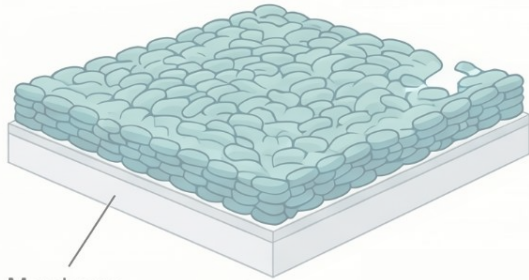
Scale bar: 10µm

# Architecture of the Void: The Unique “Column-and-Canopy” Biofilms of Space

Research from Space Shuttle missions STS-132 & STS-135 revealed that *Pseudomonas aeruginosa* forms a novel “column-and-canopy” biofilm architecture in microgravity, characterized by increased biomass, thickness, and void space, never observed under static Earth conditions.

## EARTH'S STATIC STRUCTURE

(Normal Gravity)



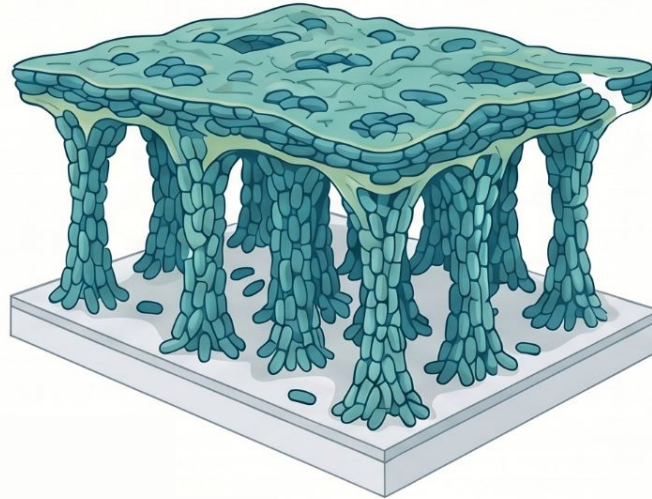
Membrane substrate

Typically forms thin, flat, and uniformly dense biofilms.

**1.8x**  
Increase in  
Void Fraction

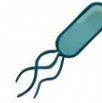## THE SPACEFLIGHT “COLUMN-AND-CANOPY”

(Microgravity)



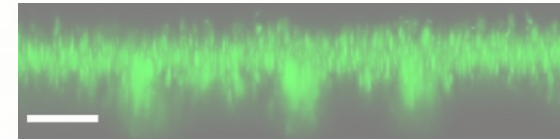
Microgravity triggers a 3D architecture consisting of dense cell aggregates forming vertical “columns” supporting a mat-like “canopy” on top.

## BIOLOGICAL DRIVERS & IMPACT



### THE NECESSITY OF MOTILITY

Flagella-driven motility is essential for this formation, bacteria without the ability to swim fail to create the column-and-canopy shape.

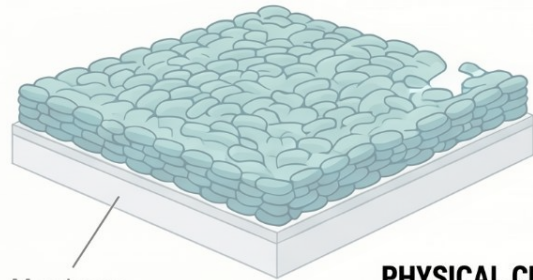


# Architecture of the Void: The Unique “Column-and-Canopy” Biofilms of Space

Research from Space Shuttle missions STS-132 & STS-135 revealed that *Pseudomonas aeruginosa* forms a novel “column-and-canopy” biofilm architecture in microgravity, characterized by increased biomass, thickness, and void space, never observed under static Earth conditions.

## EARTH'S STATIC STRUCTURE

(Normal Gravity)



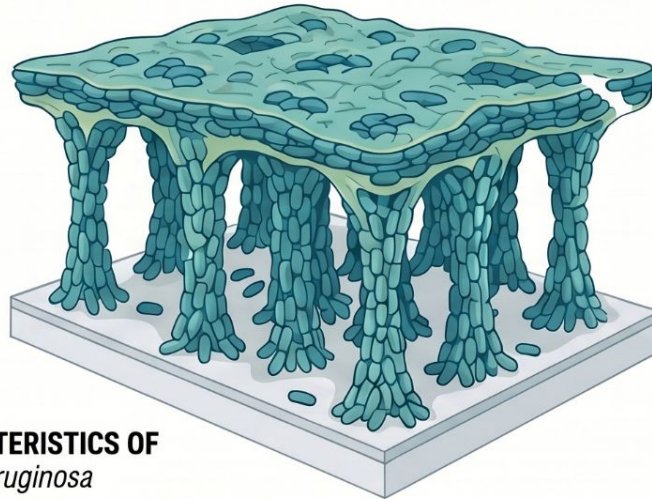
Membrane substrate

Typically forms thin, flat, and uniformly dense biofilms.

**1.8x**  
Increase in  
Void Fraction

## THE SPACEFLIGHT “COLUMN-AND-CANOPY”

(Microgravity)

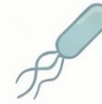

### PHYSICAL CHARACTERISTICS OF Wild Type *P. aeruginosa*

$5.4 \pm 0.5 \mu\text{m}$	Mean Thickness	$9.8 \pm 1.0 \mu\text{m}$
$3.7 \pm 0.1 \mu\text{m}^3/\mu\text{m}^2$	Biomass	$5.0 \pm 0.4 \mu\text{m}^3/\mu\text{m}^2$
$0.26 \pm 0.05$	Void Fraction	$0.47 \pm 0.02$

Microgravity triggers a 3D architecture consisting of dense cell aggregates forming vertical “columns” supporting a mat-like “canopy” on top.

## BIOLOGICAL DRIVERS & IMPACT



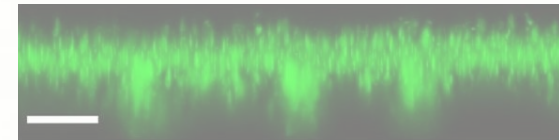
### THE NECESSITY OF MOTILITY

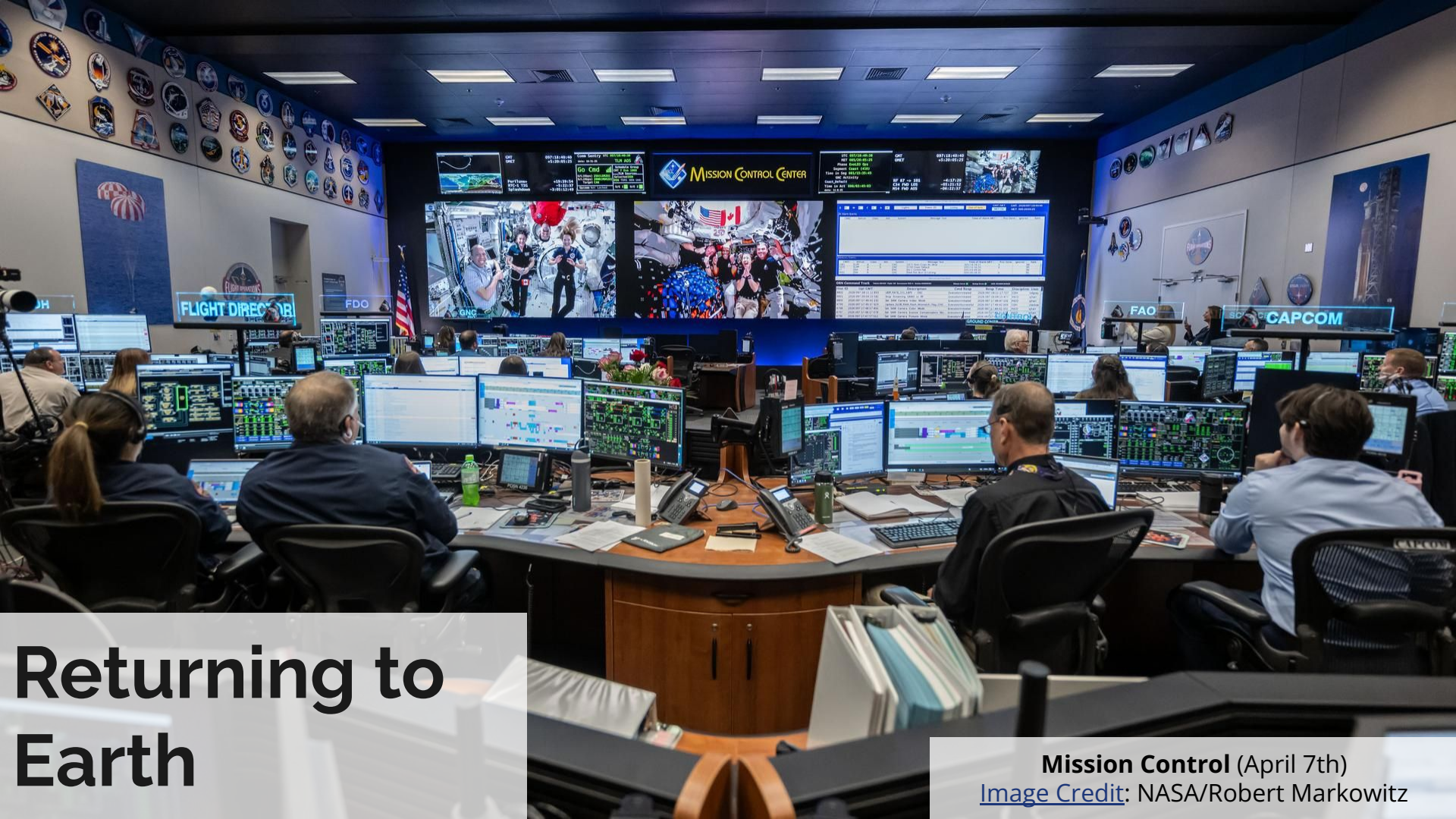Flagella-driven motility is essential for this formation, bacteria without the ability to swim fail to create the column-and-canopy shape.



### INCREASED BIOFILM PROLIFERATION

Spaceflight biofilms show a 3-fold increase in viable cell counts and significantly greater mean thickness compared to Earth controls.





# Returning to Earth

Mission Control (April 7th)  
[Image Credit:](#) NASA/Robert Markowitz

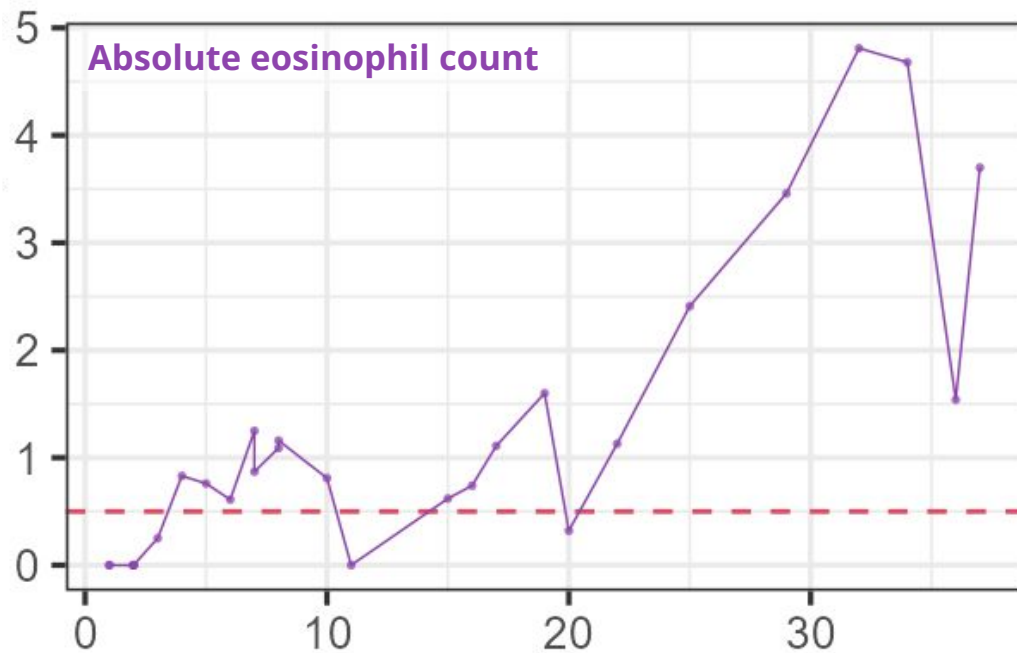
# Case 1: Readmission to OSH



Presents to local hospital due to  
**worsening pruritus** (and ?dyspnea)

# Case 1: Readmission to OSH

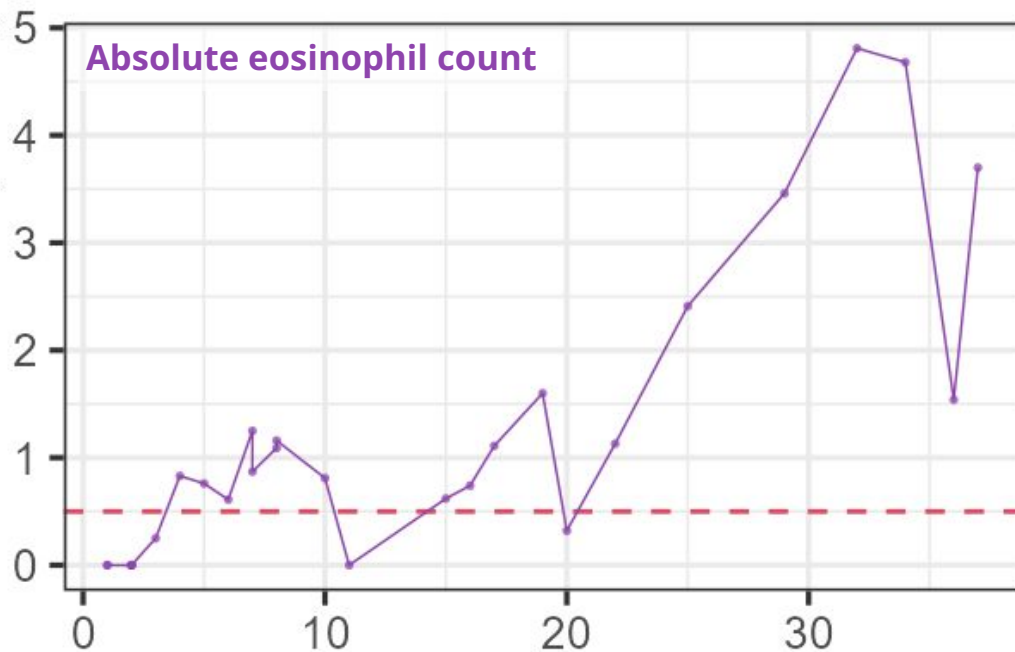
Presents to local hospital due to **worsening pruritus** (and ?dyspnea)



# Case 1: Readmission to OSH

Presents to local hospital due to **worsening pruritus** (and ?dyspnea)

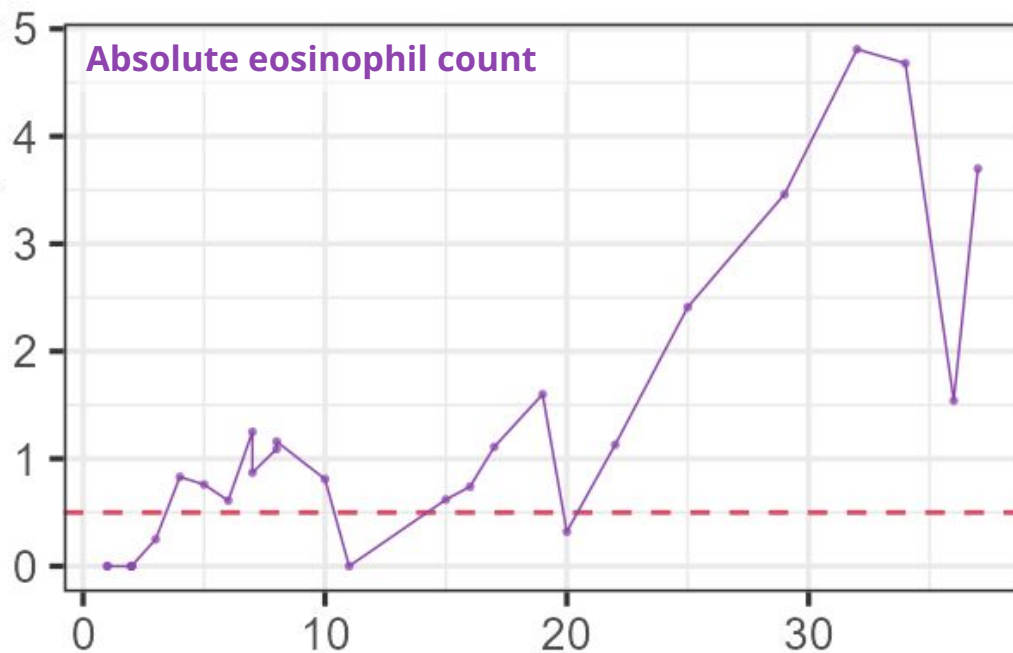
- Gets steroids with improvement
- Seen by **hematology**



# Case 1: Readmission to OSH

Presents to local hospital due to **worsening pruritus** (and ?dyspnea)

- Gets steroids with improvement
- Seen by **hematology**
  - **"Not due to chemo"**
  - ...because **he isn't on chemo**



# Case 1: Readmission to OSH

---

Presents to local hospital due to **worsening pruritus** (and ?dyspnea)

- Gets steroids with improvement
- Seen by **hematology**
  - **"Not due to chemo"**
  - ...because **he isn't on chemo**

Seen by ID there

## **Outside ID note:**

The cause of the eosinophilia is uncertain. I do not suspect this is due to Linezolid

While the steroids have resolved the eosinophils temporarily, **needs workup to determine the etiology** of the eosinophils (and **evaluation for any end organ dysfunction** - **TTE pending**).

# Case 1: Readmission to OSH

Presents to local hospital due to **worsening pruritus** (and ?dyspnea)

- Gets steroids with improvement
- Seen by **hematology**
  - **"Not due to chemo"**
  - ...because **he isn't on chemo**

Seen by ID there

## Outside ID note:

The cause of the eosinophilia is uncertain. I do not suspect this is due to Linezolid

While the steroids have resolved the eosinophils temporarily, **needs workup to determine the etiology** of the eosinophils (and **evaluation for any end organ dysfunction** - TTE pending).

**He is a hunter** and while he does **not report history of red meat allergy**, **alpha gal is a consideration** given **his recent bovine valve**.

# Case 1: Readmission to OSH

---

Presents to local hospital due to **worsening pruritus** (and ?dyspnea)

Seen by ID there

- IgE levels:
- Tryptase:
- Strongyloides:
- Trichinella Ab:
- Alpha gal profile:

## Outside ID note:

The cause of the eosinophilia is uncertain. I do not suspect this is due to Linezolid

While the steroids have resolved the eosinophils temporarily, **needs workup to determine the etiology** of the eosinophils (and **evaluation for any end organ dysfunction** - **TTE pending**).

**He is a hunter** and while he does not report history of red meat allergy, **alpha gal is a consideration** given **his recent bovine valve**.

# Case 1: Readmission to OSH

---

Presents to local hospital due to **worsening pruritus** (and ?dyspnea)

Seen by ID there

- IgE levels: **8.4** (normal)
- Tryptase: **5.0** (normal)
- Strongyloides:
- Trichinella Ab:
- Alpha gal profile:

## Outside ID note:

The cause of the eosinophilia is uncertain. I do not suspect this is due to Linezolid

While the steroids have resolved the eosinophils temporarily, **needs workup to determine the etiology** of the eosinophils (and **evaluation for any end organ dysfunction** - **TTE pending**).

**He is a hunter** and while he does not report history of red meat allergy, **alpha gal is a consideration** given **his recent bovine valve**.

# Case 1: Readmission to OSH

---

Presents to local hospital due to **worsening pruritus** (and ?dyspnea)

Seen by ID there

- IgE levels: **8.4** (normal)
- Tryptase: **5.0** (normal)
- Strongyloides: **negative**
- Trichinella Ab: **negative**
- Alpha gal profile: **negative**

## Outside ID note:

The cause of the eosinophilia is uncertain. I do not suspect this is due to Linezolid

While the steroids have resolved the eosinophils temporarily, **needs workup to determine the etiology** of the eosinophils (and **evaluation for any end organ dysfunction** - TTE pending).

**He is a hunter** and while he does not report history of red meat allergy, **alpha gal is a consideration** given **his recent bovine valve**.

# Case 1: Readmission to OSH

Presents to local hospital due to **worsening pruritus** (and ?dyspnea)

Seen by ID there

- IgE levels: **8.4** (normal)
- Tryptase: **5.0** (normal)
- Strongyloides: **negative**
- Trichinella Ab: **negative**
- Alpha gal profile: **negative**

## Discharged with:

- Steroids
- Allergy referral
- Derm follow up

## Outside ID note:

The cause of the eosinophilia is uncertain. I do not suspect this is due to Linezolid

While the steroids have resolved the eosinophils temporarily, **needs workup to determine the etiology** of the eosinophils (and **evaluation for any end organ dysfunction** - TTE pending).

**He is a hunter** and while he does not report history of red meat allergy, **alpha gal is a consideration** given **his recent bovine valve**.

# Case 1: Going to another system

Opts for a **second opinion** in another hospital system (agreed) and sees:

HemeOnc

Dermatology

Infectious Diseases

# Case 1: Going to another system

Opts for a **second opinion** in another hospital system (agreed) and sees:

## HemeOnc

- **PET/CT** and **bone marrow Bx** to confirm SLL still in remission
- Results **still pending**

## Dermatology

## Infectious Diseases

# Case 1: Going to another system

Opts for a **second opinion** in another hospital system (agreed) and sees:

## HemeOnc

- **PET/CT** and **bone marrow Bx** to confirm SLL still in remission
- Results **still pending**

## Dermatology

- Felt to be **eosinophilic dermatosis of hematologic malignancy**
- **Gets punch Bx**
  - Confirms the Dx
  - Might get Dupixent

## Infectious Diseases

# Case 1: Going to another system

Opts for a **second opinion** in another hospital system (agreed) and sees:

## HemeOnc

- **PET/CT** and **bone marrow Bx** to confirm SLL still in remission
- Results **still pending**

## Dermatology

- Felt to be **eosinophilic dermatosis of hematologic malignancy**
- **Gets punch Bx**
  - Confirms the Dx
  - Might get Dupixent

## Infectious Diseases

- **Do not** think it is infectious
- Order **histoplasmosis & toxocara** (negative)
- Plan to **use PET/CT to guide duration** of the doxy

# Alpha-Gal after bioprosthetic valve

Not that the patient had this, but  
great idea from OSH infectious  
disease team

---



Links to article discussed  
here

# Alpha-gal & bioprosthetic valves [7]

## Mechanism of complication

Presence of alpha-gal epitopes in bovine and porcine bioprosthetic valves

### Potential Responses:

- Eosinophilic infiltration of valve tissue
- Risk of systemic anaphylaxis

## Case report

Patient tolerated pork but reacted to beef.


Management included:

- Pre-treatment with steroids
- Montelukast & Cetirizine
- Diphenhydramine

## Recommendation for "Challenge" Decision

Use an **alpha-gal-specific IgE to total IgE ratio of 5%** as a cutoff threshold to consider bioprosthetic valve challenge.

*Note: Data is currently very limited regarding "challenging" with bioprosthetic valves.*



# MARS call #3

NASA's Orion spacecraft is pictured here from one of the cameras mounted on its solar array wings

April 7th, 2026 on 8:58 a.m. ET (mission day 7)  
Image credit: JSC/NASA

## MARS #3: HPI

---

A **31 y/o F** astronaut presents on **mission day 60** for **erythema + calor** on the skin surrounding a recent **left elbow abrasion**

# MARS #3: HPI

---

A **31 y/o F** astronaut presents on **mission day 60** for **erythema + calor** on the skin surrounding a recent **left elbow abrasion**

- A week ago, noticed a **pimple** over her elbow after a prolonged EVA
  - No *overt lacerations* or skin breakdown
- In following days, noticed
  - **Erythema** developing around the area
  - Mild **pain**

**EVA** = "Spacewalk"  
(Extravehicular Activity)

# MARS #3: HPI

---

A **31 y/o F** astronaut presents on **mission day 60** for **erythema + calor** on the skin surrounding a recent **left elbow abrasion**

- A week ago, noticed a **pimple** over her elbow after a prolonged EVA
  - No *overt lacerations* or skin breakdown
- In following days, noticed
  - **Erythema** developing around the area
  - Mild **pain**
- **3 days ago**, flight surgeon (at mission control) evaluated case
  - Felt to be **skin and soft tissue infection**
  - Recommended **Augmentin**

**EVA** = "Spacewalk"  
(Extravehicular Activity)

# MARS #3: HPI

---

A **31 y/o F** astronaut presents on **mission day 60** for **erythema + calor** on the skin surrounding a recent **left elbow abrasion**

- A week ago, noticed a **pimple** over her elbow after a prolonged EVA
  - No *overt lacerations* or skin breakdown
- In following days, noticed
  - **Erythema** developing around the area
  - Mild **pain**
- **3 days ago**, flight surgeon (at mission control) evaluated case
  - Felt to be **skin and soft tissue infection**
  - Recommended **Augmentin**
- **No improvement** on antibiotics

**EVA** = "Spacewalk"  
(Extravehicular Activity)

## MARS #3: HPI

---

A 31 y/o F astronaut evaluated for **abscess of left elbow** that has been ongoing **after prolonged EVA** on mission **day 60**. On mission **day 64**, flight surgeon started **Augmentin**, with no improvement.

Mission control guides the crew medical officer (not a physician) on **point of care ultrasound (day 67)**

- Identifies a **5mm abscess** limited to SQ tissue
- Performs an **I&D with purulent discharge**

# MARS #3: HPI

---

A **31 y/o F** astronaut evaluated for **abscess of left elbow** that has been ongoing **after prolonged EVA** on mission **day 60**. On mission **day 64**, flight surgeon started **Augmentin**, with no improvement.

Mission control guides the crew medical officer (not a physician) on **point of care ultrasound (day 67)**

- Identifies a **5mm abscess** limited to SQ tissue
- Performs an **I&D with purulent discharge**

Pretend this was somehow available on board (unlikely to be the case)

- Gram stain shows **GPC in clusters**
- **MecA** testing was **negative**

# MARS 3: Summary

A **31 y/o F** astronaut evaluated for **abscess of left elbow** that has been ongoing **after prolonged EVA** on mission **day 60**. On mission **day 64**, flight surgeon started **Augmentin**, with no improvement.

On **day 67**, POCUS shows **5mm abscess**

- I&D with purulent material
- GPC in clusters on gram stain
- MecA negative

T 37.6°C, HR 93, BP 100/64

- What is the suspected pathogen?
- Why isn't she responding to Augmentin?



# MARS: Are the bacteria more virulent? [1]

---

*Early in our ventures into space (Salyut 7), there was a great deal of concern that bacteria transformed into **superbugs** in space*

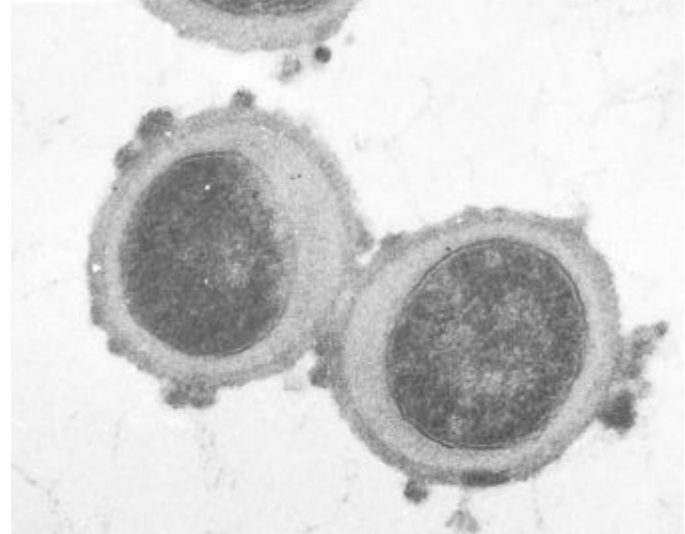
Intuition: **Hypermutations**  
from **radiation** & **stress of**  
**microgravity**

# MARS: Are the bacteria more virulent? [1]

*Early in our ventures into space (Salyut 7), there was a great deal of concern that bacteria transformed into **superbugs** in space*

In 1982, **staph aureus isolates** (seemingly) changed to appear **morphologically similar to VISA**

Intuition: **Hypermutations** from **radiation** & **stress of microgravity**



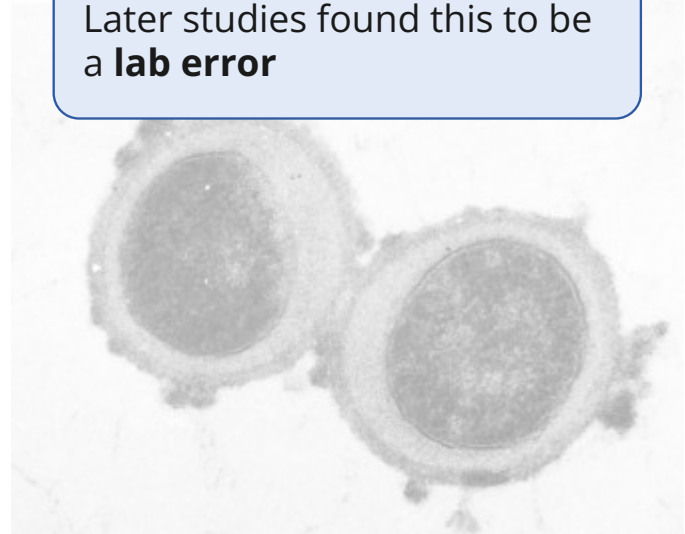
# MARS: Are the bacteria more virulent? [1]

Early in our ventures into space (*Salyut 7*), there was a great deal of concern that bacteria transformed into **superbugs** in space

Intuition: **Hypermutations** from **radiation** & **stress of microgravity**

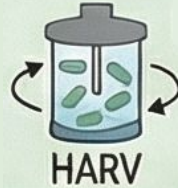In 1982, **staph aureus isolates** (seemingly) changed to appear **morphologically similar to VISA**

Later studies found this to be a **lab error**



# MARS: Are the bacteria more virulent? [1]

We can model microgravity pretty well on Earth using LSMMG



## Low-Shear Modeled Microgravity

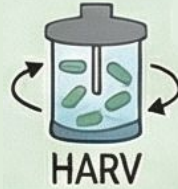Ground based bioreactors (HARVs) simulate the space environment with constant suspension via rotation

# MARS: Are the bacteria more virulent? [1]

We can model microgravity pretty well on Earth using LSMMG

**Mice studies** with **Salmonella** found:

- ↑↑ acid tolerance
- Faster colonization
- ↓↓ LD50



## Low-Shear Modeled Microgravity

Ground based bioreactors (HARVs) simulate the space environment with constant suspension via rotation

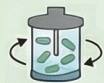# MARS: Are the bacteria more virulent? [1]

We can model microgravity pretty well on Earth using LSMMG

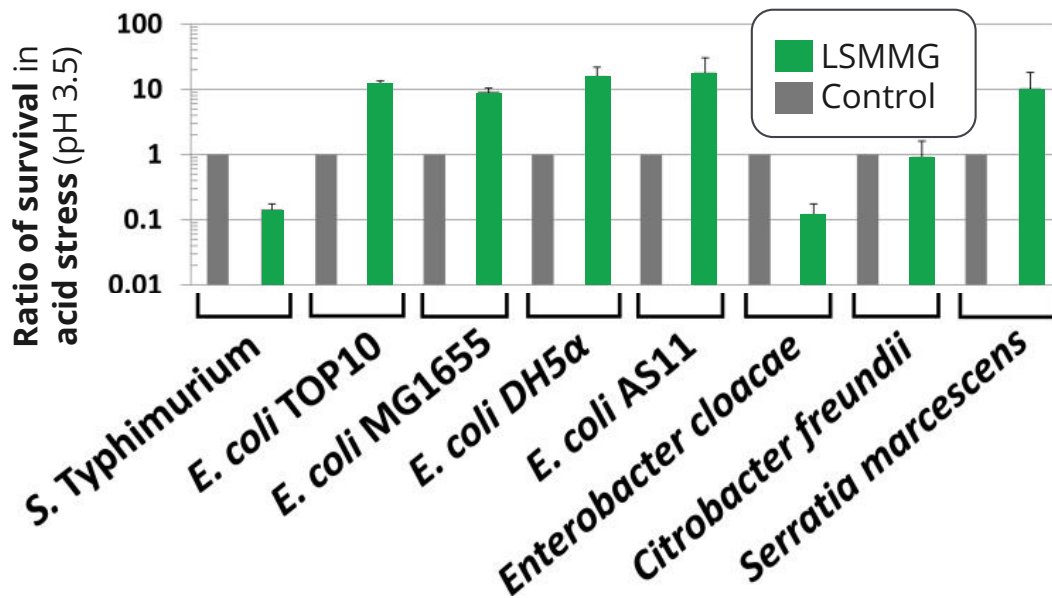
Mice studies with **Salmonella** found:

- ↑↑ acid tolerance
- Faster colonization
- ↓↓ LD50

**Similar findings** for other gram negatives (**Enterobacterales**) [5]



Low-Shear Modeled Microgravity



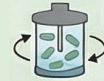# MARS: Are the bacteria more virulent? [1][5]

We can model microgravity pretty well on Earth using LSMMG

- Might make **gram negatives more virulent**

For **gram positives**, microgravity seems to **decrease virulence**

- **Decreased hemolysins** (MRSA)
- Tendency to shift from **planktonic** → **biofilm**



**Low-Shear Modeled Microgravity**

# MARS: Are the bacteria more virulent? [1][5]

We can model microgravity pretty well on Earth using LSMMG

- Might make **gram negatives more virulent**
- For **gram positives**, seems to **decrease virulence**



**Low-Shear Modeled Microgravity**

**Spaceflight is more than microgravity**

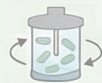Numerous other factors in space, which are **hard to replicate on Earth**

- Acceleration
- Radiation
- Electromagnetism
- Vibration

# MARS: Are the bacteria more virulent? [1][5]

We can model microgravity pretty well on Earth using LSMMG

- Might make **gram negatives more virulent**
- For **gram positives**, seems to **decrease virulence**



Low-Shear Modeled Microgravity

Spaceflight is **more than microgravity**

- Acceleration
- Radiation
- Electromagnetism
- Vibration


**Good microbiology is hard in space**

- Specialized equipment = heavy
- Limited space
- Zero G = No convection
- Astronaut time is at a premium
- Contamination

# MARS: Are the bacteria more virulent? [1][6]

We have studied worms in space

- **Roundworms** brought to **ISS**
- Did *not* make worm holes




AI generated image, but not a bad design for a roundworm (Nano Banana 2)

# MARS: Are the bacteria more virulent? [1][6]

We have studied worms in space

- **Roundworms** brought to ISS
- Did *not* make worm holes





AI generated image, but not a bad design for a roundworm (Nano Banana 2)

(vs ground)	Adult	Larvae
<b>C albicans</b>	↓↓ (p=.06)	↓↓
<b>Listeria</b>	↓↓	↓↓
<b>E faecalis</b>	↓↓	↓↓
<b>MRSA</b>	↓↓	↓↓

# MARS: Are the bacteria more virulent? [1][6]

We have studied worms in space

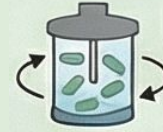- **Roundworms** brought to ISS
- Did *not* make worm holes

(vs ground)	 Spaceflight		 Rotation	
	Adult	Larvae	Adult	Larvae
<b>C albicans</b>	↓↓ (p=.06)	↓↓	---	↓↓
<b>Listeria</b>	↓↓	↓↓	No change	No change
<b>E faecalis</b>	↓↓	↓↓	No change	↓↓
<b>MRSA</b>	↓↓	↓↓	No change	No change

# MARS: If it's not the pathogen, what is it? [1]

Antimicrobials on the ISS (in 2015)

- Amikacin
- Amoxicillin
- Azithromycin
- Bactrim
- Vancomycin tablets
- Cefadroxil
- Cipro
- Flagyl
- Many topicals



## LSMMG on Earth [5]

Gram neg: ↑↑ virulence  
Gram pos: ↓↓ virulence



## Nematodes [6]

**Less susceptible** to MRSA,  
E faecalis, C albicans, and  
listeria

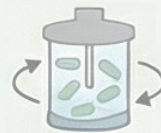# MARS: If it's not the pathogen, what is it? [1]

Antimicrobials on the ISS (in 2015)

- Amikacin
- Amoxicillin
- Azithromycin
- Bactrim
- Vancomycin tablets
- Cefadroxil
- Cipro
- Flagyl
- Many topicals

## 1 in 12 don't work

During the space shuttle program, **8%** of medications were **reported as non-efficacious**



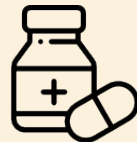## LSMMG on Earth [5]

Gram neg: ↑↑ virulence  
Gram pos: ↓↓ virulence



## Nematodes [6]

**Less susceptible** to MRSA, E faecalis, C albicans, and listeria



## Medication stability

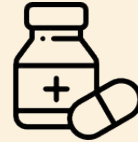Medications don't follow the same rules as on Earth

# MARS: Medication stability in space [1]

---

## The Study

- 35 formulations of medications
- Compared **Earth vs ISS**
- Stored for **28 months**



## Medication stability

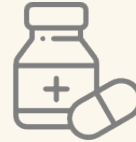Medications don't follow the same rules as on Earth

# MARS: Medication stability in space [1]

## Findings

Substantial **reduction in active ingredients** were found in spaceflight medications compared to those kept on Earth

- **Augmentin**
- **Bactrim**



## Medication stability

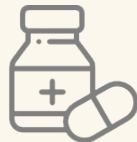Medications don't follow the same rules as on Earth

# MARS: Medication stability in space [1]

## Findings

Substantial **reduction in active ingredients** were found in spaceflight medications compared to those kept on Earth

- **Augmentin**
- **Bactrim**



## Medication stability

Medications don't follow the same rules as on Earth

**Ionizing radiation**

**Trace moisture**  
from within the pill

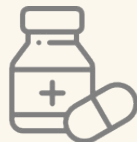Production of  
**reactive oxygen  
species & free  
radicals**

# MARS: Medication stability in space [1]

## Findings

Substantial **reduction in active ingredients** were found in spaceflight medications compared to those kept on Earth

- **Augmentin**
- **Bactrim**



## Medication stability

Medications don't follow the same rules as on Earth

**Ionizing radiation**

**Trace moisture**  
from within the pill

Production of  
**reactive oxygen  
species & free  
radicals**

Oxidative  
**stress**

**Degrades**  
clavulonic  
acid

# MARS: Medication stability in space [1]

## Findings

Substantial **reduction in active ingredients** were found in spaceflight medications compared to those kept on Earth

- **Augmentin**
- **Bactrim**



## Medication stability

Medications don't follow the same rules as on Earth

## Impact

Many of the medications in space **would not pass US testing standards**

Ionizing radiation

Trace moisture  
from within the pill

Production of  
**reactive oxygen  
species & free  
radicals**

Oxidative  
**stress**

**Degrades**  
clavulonic  
acid

# Learning points & take aways

---



# Learning points & take aways



- Spaceflight causes **functional immunocompromise**
  - ↓ T-cell function, lymphoid atrophy
  - ↑ **viral reactivation** (HSV, VZV)
  - **Shift in GI microbiome** (↓ normal flora, ↑ gram-negatives)
- **Spacecraft** can have a **very dirty** microbiome
  - **Gram negatives** (Pseudomonas, **Burkholderia**, Serratia), **Candida**, molds; even **protozoa & spirochetes**
- Space affects both the humans and the pathogens
  - ↓ convection → diffusion-dependent growth → **stange biofilms**
  - Some become **more virulent (gram neg)** but other become **less virulent (gram pos)**
- Standard **infection control processes may be less effective**
  - Biofilms + fluid behavior limit sterilization
- **Outer space degrades medications** (radiation + oxidation), making most ↓ **potency over time**; 1 in 12 are not effective

Slides available on [hunteratliff1.com/talk/](http://hunteratliff1.com/talk/); Citations available via QR code or via the "citations" button on the website