Headaches

CID conference
07/18/2024

Ages, dates, and other less-relevant (and identifying) information may have been changed

Shortcuts

Case 1: Start | Summary slide
Case 2: Start | Summary slide

Discussion start

- **Cryptococcus overview** | epi & risk factors | pathophys
- **2024 guidelines** | treatment (CNS) | ART timing
- **Intrathecal antimicrobials** | Lit review

Case #1

HPI: Outside ED visit

A **31 y/o M** with no PMH presented to OSF ED for **three weeks of frontal headaches**

Had two root canals in recent months. Following the most recent root canal (~3 weeks ago), he had a **headache and fevers**. His dentist prescribed him **a week of Amoxicillin** which resolved his fevers, but headaches have still been worsening

Additionally, his **left ear feels "muffled"** but no pain or discharge. States this feels similar to **sinus infections** he's had in the past. He had one episode of **syncope** since the headache started, which the patient states was from lightheadedness

Positive ROS: fatigue, weakness, lightheadedness, dry cough

Negative ROS: Fevers, chill, dyspnea, bleeding

HPI: Outside ED visit

A **31 y/o M** with no PMH presented to OSF ED for **three weeks of frontal headaches**

Had two root canals in recent months. Following the most recent root canal (~3 weeks ago), he had a **headache and fevers**. His dentist prescribed him **a week of Amoxicillin** which resolved his fevers, but headaches have still been worsening

ED staff also talked with his fiance (been together 8 years) who gave additional context as the fiance is a nurse. He reports patient was seen by a dermatologist a month ago and diagnosed with **self-limiting rash on his forehead**. Can't remember the name of diagnosis*.

Fiance says d/t persistence of headache despite ABX, patient was Rx'ed steroids. Once he **started the steroids**, that's when the fiance thinks **things took a turn for the worse**.

Workup: Outside ED visit

VS: 36.5 C | 92 bpm | 116/74 | 99% | BMI 20

General: Alert, mildly ill appearing, fatigued

Neuro:

- **CN:** II-XII intact
- **Motor:** equal and normal bilaterally
- **Language:** Speech normal

Sodium: 131
Mg: 1.3

WBC: 3.5 (88% neutrophils)
Hgb: 9.0
Plt: 280

CT Head: Unremarkable

Resp Biofire: Negative

Outside ED Visit #1

Headache improved with migraine cocktail

Given IV Mg for electrolyte abnormalities

Was discharged with PCP follow up

- Holter for episode of syncope
- PO iron for anemia

-1 month

Forehead rash

Told by dermatologist it was self limiting
Notes are inconsistent on what exact diagnosis was

-3 weeks

Root canal

Frontal headaches
Fever (resolved with augmentin)
Dizzy, ? syncope

-1 week

Took steroids

Urgent care Rx'ed steroids (unclear why)
Fiance says he got much worse after steroids

Day 0

ED visit #1

Improved with migraine cocktail
Discharged from ED

Outside ED #2

He returns to the ED two days later with further **episodes of syncope**. Per ED note

of continued headache, recurrent syncope. Stable vitals on arrival. Afebrile. No hypoxia. Exam with no focal neurologic deficits. Recent workup showed iron deficiency anemia abnormal head CT. Based on his continued and recurrent symptoms further workup obtained today. Labs/imaging as above. Sodium and chloride low. Potassium low at 2.7. This was replaced both orally and IV. Magnesium slightly low at 1.4. White blood cell count low at 3.1. Anemia stable. Platelets normal. Procalcitonin normal. Troponin normal. Based on his symptoms CTA of the head and neck was performed. No aneurysms, bleeds or other acute abnormalities. CT of the spine revealed no fracture from his fall. There was an incidental right lobe cavitary lesion. CT of the chest was then added on which confirms a large pulmonary cavitary lesion that could either be from infection, aspiration or septic emboli. I personally reviewed images and agree with radiologist findings. Patient does have a male partner. He states he gets tested for HIV regularly. Has never been positive. Based on workup findings HIV panel, blood cultures and lactic acid added on. Patient started on vancomycin and Zosyn and was admitted for further workup

Additional information from H&P / collateral

Social: Works as director of funeral home. Monogamous with partner for past 8 years. No needles, IVDU, etc. No animals besides pet puppies (7 of them, very cute). No birds

From fiance: Was able to find out the rash patient had a month ago was **molluscum contagiosum**. Partner also said since patient started taking steroids, was having **vision problems** and **ataxia**.

From parents: They'd noticed **unintentional weight loss**, ongoing at least past three months

OSH Imaging

CT chest: Lungs: Cavitary nodule in the posterior medial aspect of the right lower lobe measuring 5.5 x 5.0 x 3.9 cm. There is centrilobular nodularity in the anterior mid right upper lobe. Lungs otherwise clear.

MRI brain:

Patchy FLAIR/T2 hyperintense signal within the brainstem, cerebellum, bilateral basal ganglia and thalami, and periventricular/subcortical white matter, showing bilateral but asymmetric involvement. Associated tiny foci of restricted diffusion within the left internal capsule (DWI image 38) and left cerebellar hemisphere (DWI image 45). No associated cerebral edema, intracranial hemorrhage, or abnormal intracranial enhancement. Ventricles are normal in size. Dural venous sinuses are patent. Retention cyst within the bilateral maxillary sinuses. Small effusions in the bilateral mastoid air cells.

Impression: Patchy bilateral supra and infratentorial white matter signal abnormalities, including two small foci of restricted diffusion in the left basal ganglia and left cerebellar hemisphere. Differential includes atypical demyelination such as ADEM, CADASIL, or CNS vasculitis.

Outside Hospital Course

Admitted and found to be hyponatremic (124), overcorrected

Hospital Day 1: Had a **seizure** on hospital day one and went to the ICU

Hospital Day 2:

- Developed **left sided hemiplegia, right gaze deviation, GCS 6** → intubated
- LP done
- Transferred to Ruby

Discussion

What did the blood cultures from the first ED visit grow?

Discussion

A **31 y/o M** with no PMH presented to OSF ED for **three weeks of frontal headaches**

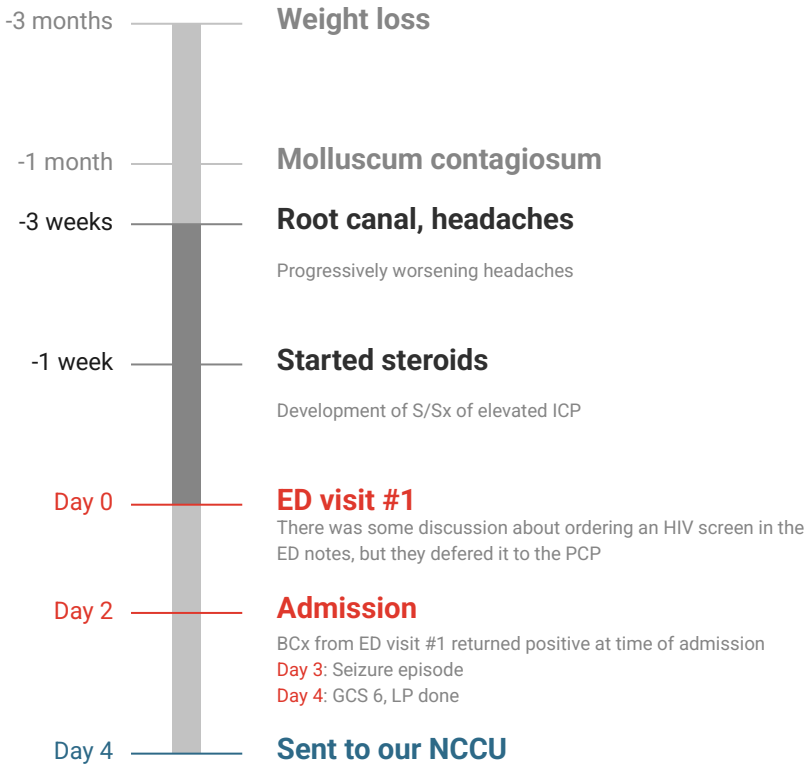

Case #2

HPI

A **66 y/o M** with PMH Afib (warfarin), obesity, polycythemia, AVB s/p PPM, hx of numerous cancers (skin, colon, prostate) presented to ED for **three days of generalized weakness**

- He was recently seen in the ED (**two weeks ago**) where he reported **three weeks of headaches**. Was **diagnosed with sinusitis** and Rx'ed **Augmentin** & **azithromycin**
  - Five days ago @ urgent care: Given **doxy** & **medrol dose pack** but no improvement
- Too sleepy to give much else HPI wise

Positive ROS:

- Left facial droop
- Somnolence
- Dysarthria
- Neck stiffness
- Incontinence

Social History, Exposures, Risk Factors

Geographic & Occupational: Lives in WV with wife. Used to work in maintenance, but retired and spends time woodworking. No foreign travel

Substance: Former heavy smoker, quit 12 years ago. No EtOH or drugs

Environmental exposures: Freshwater (6 months ago)

Animal Exposures: No farm animals, chickens, birds. Keeps bees

Infectious PMH: Remote history of osteomyelitis (30+ years ago). Right foot hardware. No TB

Exam

VS: 37 C | 66 bpm | 140/74 | 94% | BMI 34

Constitutional: **Acutely ill** appearing gentleman.

Neurologic: **Patient difficult to arouse. Requires frequent stimuli. Intermittently follows commands**.

Neck: supple. **Nuchal rigidity present**.

Eyes: Sclera non-icteric, conjunctiva non-injected.

HENT: Buccal mucosa moist. Healthy dentition present.

Respiratory: Respirations are **non labored on 2 L NC**. No crackles or wheeze on auscultation.

Cardiovascular: Heart has a regular rate and rhythm without murmur.

Gastrointestinal: Abdomen is soft and non-distended. Non-tender to palpation. Normoactive bowel sounds present.

Musculoskeletal: No swelling of the upper or lower extremities. Surgical to right ankle well approximated. No erythema.

Integumentary: No diffuse rashes. Skin is warm and non-diaphoretic.

Workup

WBC: **15** (91% neutrophils)

Lactate: **2.2**

ESR: 2

INR: **5.2**

HIV & HCV **negative**

Workup

WBC: **15** (91% neutrophils)

Lactate: **2.2**

ESR: 2

INR: **5.2**

HIV & HCV **negative**

CT Head: No stroke

MRI: Sorry! (he has a pacemaker)

Workup

WBC: **15** (91% neutrophils)

Lactate: **2.2**

ESR: 2

INR: **5.2**

HIV & HCV **negative**

CT Head: No stroke

MRI: Sorry! (he has a pacemaker)

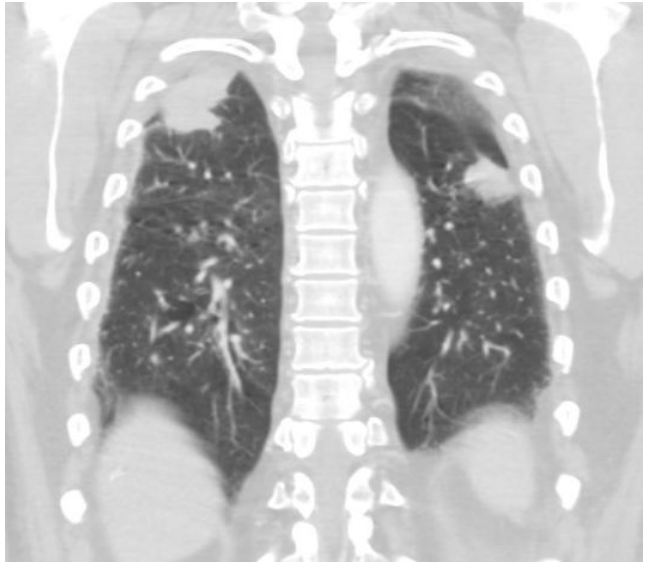

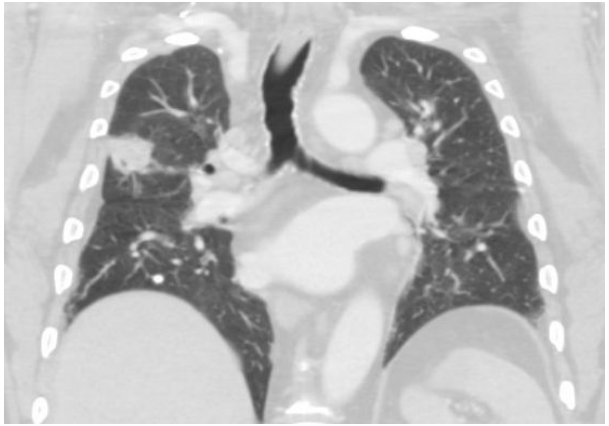

CT chest: bilateral upper lobe consolidations. Mediastinal & bilateral perihilar LAD

Workup

WBC: **15** (91% neutrophils)

Lactate: **2.2**

ESR: 2

INR: **5.2**

HIV & HCV **negative**

CT Head: No stroke

MRI: Sorry! (he has a pacemaker)

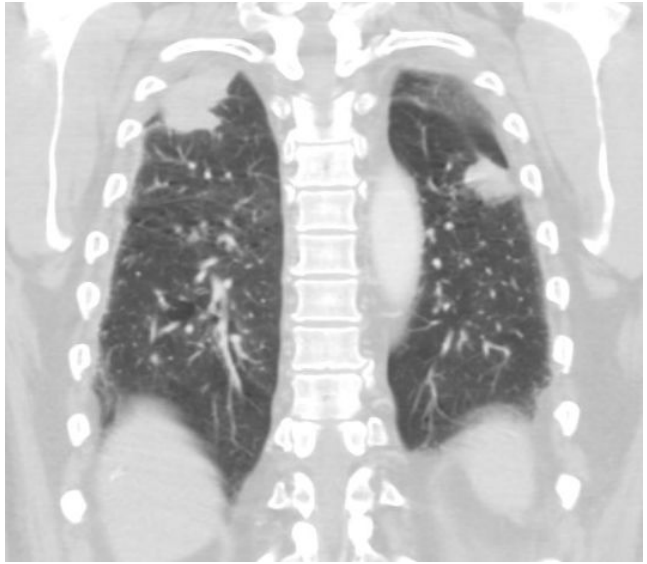

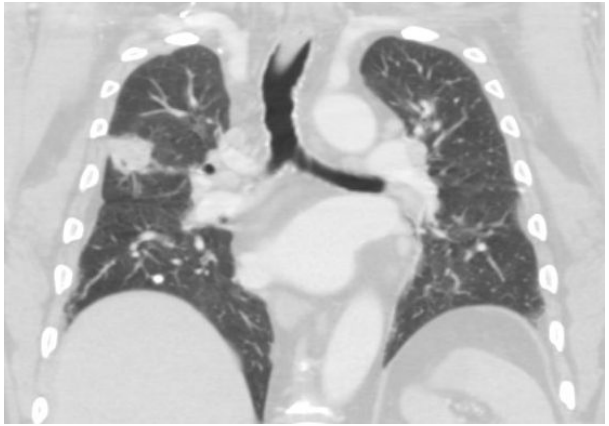

CT chest: bilateral upper lobe consolidations. Mediastinal & bilateral perihilar LAD

Lumbar Puncture?

Oh right, the INR

Hospital Course

ID consulted for possible meningitis

- Started on steroids -*plus*- ceftriaxone, acyclovir, vancomycin, and ampicillin

LP deferred until INR came down

Hospital day 2: LP was done

- ID paged overnight

Discussion

A **66 y/o M** with PMH Afib (warfarin), obesity, polycythemia, AVB s/p PPM, hx of numerous cancers (skin, colon, prostate) presented to ED for **three days of generalized weakness**

Hospital Courses

Case #1

- Opening pressure: ≥55 cmH2O
- On transfer to Ruby, we saw he hadn't seen his HIV doc in years
- EVD placed
  - Started on intrathecal AmBisome
- CD4: 5 (5%), VL 618k
- MTB PCR negative

Case #2

- Opening pressure: ≥45 cmH2O
- Still not clear why immunocompromised, HIV negative
- EVD placed
  - Started on intrathecal AmBisome
- CD4: 281 (CD8 34)
  - Repeat a week later improved to CD4 491; CD8 52

Discussion

Links to articles discussed here

Cryptococcal meningitis

1. **Epidemiology, pathophys**
2. Recent guidelines on management
3. Intrathecal?

All articles

Cryptococcus

HIV associated crypto meningitis accounts for 19% of HIV mortality world wide (highest burden in sub-Saharan Africa)

- *Cryptococcus neoformans*: More often HIV → predilection for CNS
- *Cryptococcus gattii*: immunocompetent → lungs & cryptococcomas

Host factors:

- HIV
- SOT &/or ↓ CMI (e.g. JAK_{inh})
- Cirrhosis
- If no known risk factors, the 2024 guidelines recommend workup for immunodeficiencies (supp table 1)

Exposures:

- Bird poop!
- Decaying wood (case #2)
- Tree hollows
- Soil

CRYPTOCOCCUS

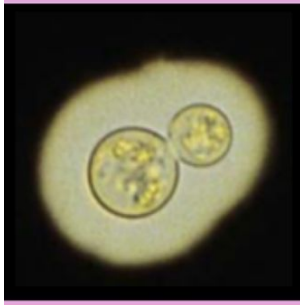

- Asexual form exists as yeast, reproduces by **narrow based budding**, and is the form that has been recovered in human infections
- A few key virulence factors:
  - Antiphagocytic polysaccharide capsule formation
  - Melanin pigment production which helps protect against oxidative stress
  - Thermotolerance (the "yeast that likes it hot")
- Two main spp: *Cryptococcus neoformans, Cryptococcus gattii*

Cryptococcus neoformans

Worldwide distribution

Found in **soil** and **rotting vegetation** from areas frequented by **birds** and **bird guano** (especially pigeons, chickens, turkeys)

Largely affects **immunocompromised** patients

(HIV/AIDS, prolonged corticosteroids, organ transplant, lymphoproliferative disorders and malignancy, cirrhosis, sarcoidosis, monoclonal Ab use, autoantibodies to GM-CSF, idiopathic CD4 lymphocytopenia)

Cryptococcus gattii

Tropical/subtropical regions such as Australia and Papua New Guinea. North American clusters have largely been in British Columbia, Pacific Northwest

Historically associated with **eucalyptus trees**, but has been noted in other trees and soil

Largely affects **immunocompetent** patients

Pathophysiology

- Elevated ICP
  - Crypto gunks up the arachnoid granules → poor CSF resorption → nonobstructive hydrocephalus
  - Cryptococcus also produces D-mannitol within CSF → osmotic effect
  - Altered pro & anti-inflammatory cytokines (part of why steroids worsen outcomes, both cases)

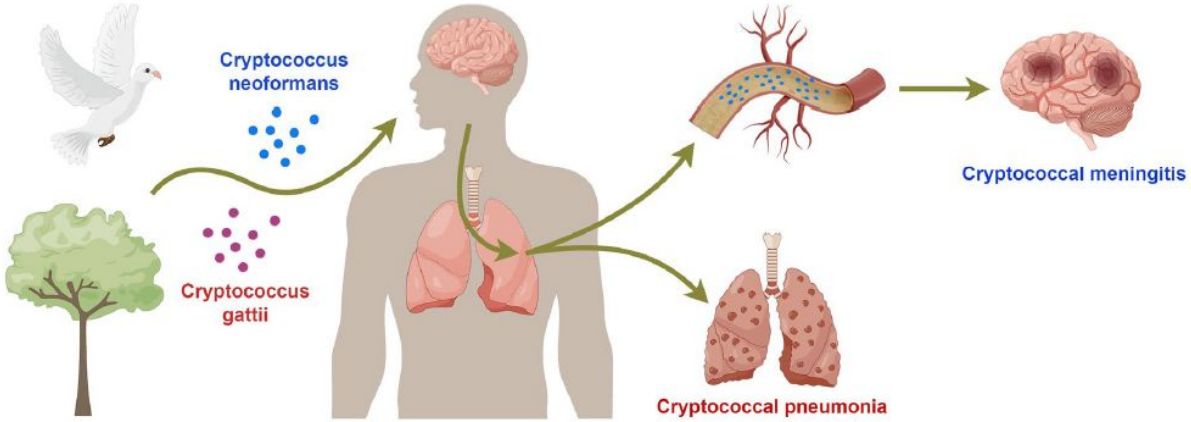

CRYPTOCOCCUS: CLINICAL MANIFESTATIONS

Pulmonary

- Can range from asymptomatic to single pulmonary nodule to acute life-threatening pneumonia
- Abnormalities on chest imaging can be variable! Nodules, LAD, lobar or interstitial infiltrates, pleural effusions, cavities, etc

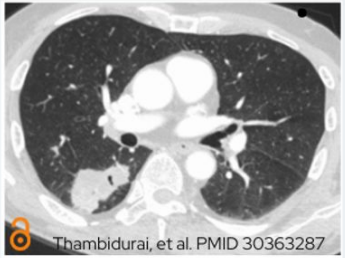

- Serum CrAg may be negative in true isolated pulmonary cryptococcosis

CNS

Critical feature of *Cryptococcus*: propensity for CNS complications

- Cryptococcal meningoencephalitis (acute, subacute, chronic)
  - Classic signs like fever, meningismus, photophobia are present in only about 1/3 of patients
  - Later in course may have cranial nerve palsies (particularly ocular nerve)
- Cerebral cryptococcomas (seen more with *C.gattii*)
- Spinal cord granulomas

Most commonly affects the lung and central nervous system

Cutaneous

- Large variability in possible appearances, but classic = papules with central umbilication (may resemble molluscum contagiosum)
- Most cases of skin lesions represent disseminated disease, although direct inoculation is possible

Others

Cryptococcemia and disseminated disease can occur with severe immunosuppression. Other body sites include:

- Eye involvement, such as papilledema, keratitis, endophthlamitis
- Prostatic infection (can serve as important reservoir for dz relapse)
- Osteoarticular (vertebral osteomyelitis most commonly)
- GI: Peritonitis; nodules or ulcers in stomach/intestines that mimics Crohns disease

CRYPTOCOCCUS: DIAGNOSTICS

Direct examination

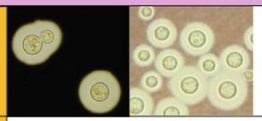

- India ink prep of CSF and direct microscopic exam for encapsulated yeasts where available (less common now)
  - Sensitivity depends on fungal burden
  - False positive might result from intact lymphocytes, other cells, or nonviable yeast forms

Culture

- Can be readily cultured from CSF, sputum, and biopsy on routine fungal and bacterial culture media
  - Usually observed after 3d with white/cream colored colonies (that might be more organ/brown after prolonged incubation)
  - Canavanine-glycine-bromthymol agar turns blue for *C.gattii* but not *C.neoformans*



Histopathology

- Can identify with staining of tissues --> **narrow based budding**
- H&E: **4-10 µm yeasts**, large clearing from capsule that doesn't stain
- Special stains that label the polysaccharide capsule:
  - Mucicarmine: stains capsule pink/red
  - Periodic acid-Schiff (PAS)
  - Alcian blue
- Fontana Masson: identifies melanin in yeast cell wall
- Others can stain cell wall (Calcofluor, Gomori methanine silver/GMS)

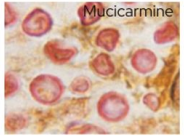

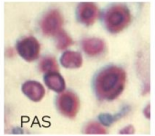

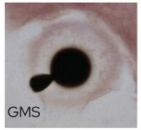

Images from CDC PHIL; Mandell text; Long text

CrAg

- Tests for cryptococcal polysaccharide capsular antigen (CrAg), which can be performed on serum or CSF
- Lateral flow assay (LFA) is preferred over other methods (latex agglutination, enzyme immunoassay) given rapid turnaround, higher sensitivity/specificity, lower cost, minimal requirements for lab infrastructure
- False positive might result from *Trichosporon asahii, Stomatococcus, Capnocytophaga*
- False negative might result from latex agglutination test if large amount of antigen (prozone phenomenon)

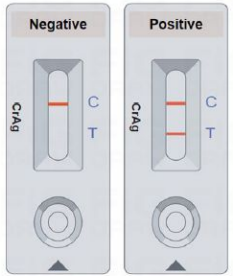

Lateral flow assay (LFA)

PCR

- Multiplex PCR available for CNS infection (such as BioFire FilmArray), but less sensitive if lower burden of CSF yeast

SAW A PIGEON
GOT CRYPTOCOCCAL MENINGITIS?
quickmeme.com

Global guideline for the diagnosis and management of cryptococcosis:

An initiative of the ECMM and ISHAM in cooperation with the ASM

Lancet Infect Dis (2024)
https://doi.org/10.1016/

1. Epidemiology, pathophys
2. **Recent guidelines on management**
   - HIV CM
   - Other CM
   - ICP management
   - ART
3. Intrathecal?

All articles

Really good guidelines!

THE LANCET
Infectious Diseases

So well organized

- Supplemental material dives into lots
- Main manuscript high level & succinct

Topics not covered by me today

- Non-meningitis cryptococcus (pulmonary & otherwise)
- Antifungal resistance
- Relapse (clinical & microbiologic)
- Management of C-IRIS

[1]

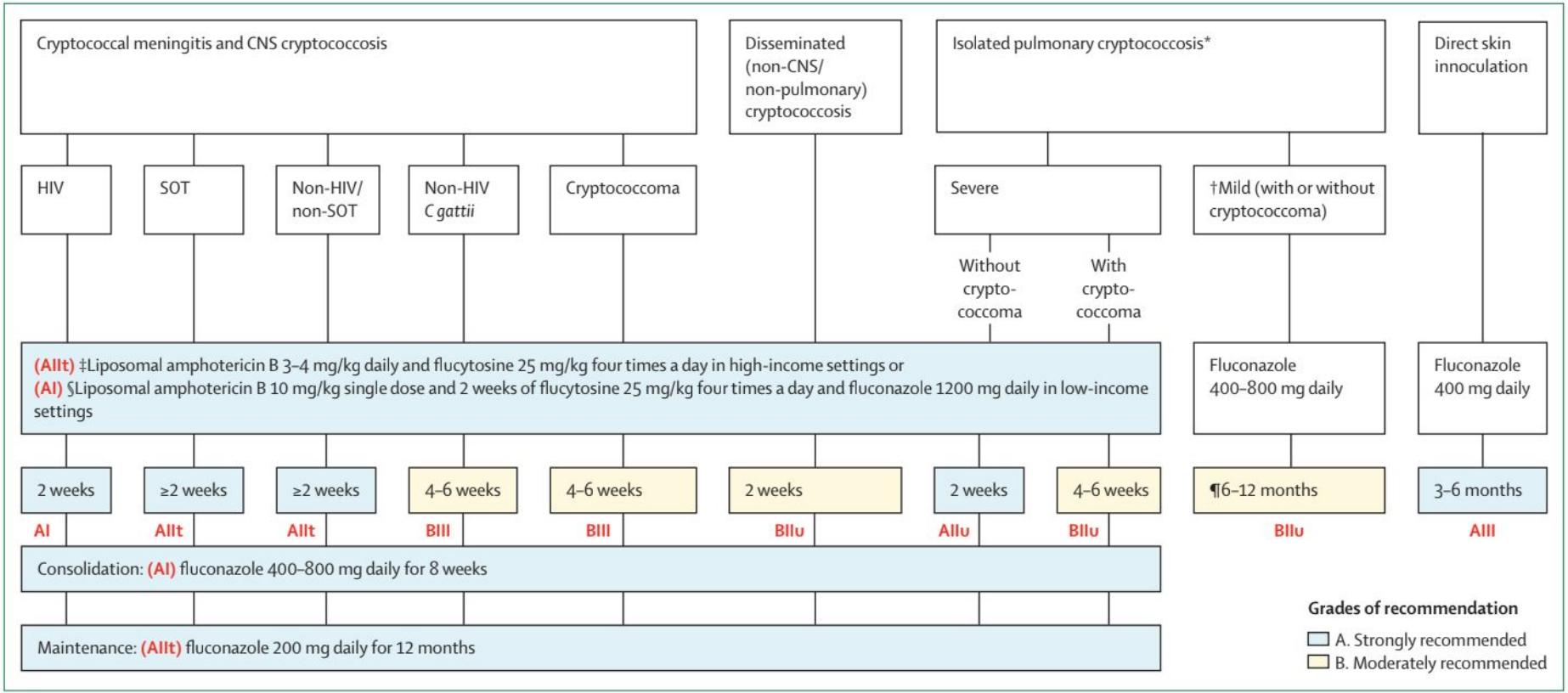

Figure 1 with overview of treatment

HIV associated CM

[1] [2]

A People with HIV

First-line therapies

Induction (2 weeks)
(AIIt) Liposomal amphotericin B 3–4 mg/kg daily plus flucytosine 25 mg/kg four times a day (preferred in high-income settings); or
(AI) Single dose liposomal amphotericin B 10 mg/kg and 14 days of flucytosine 25 mg/kg four times a day and fluconazole 1200 mg daily (recommended in low-income settings)

Alternate **induction** therapies for low incomes settings

- AMBITION-cm (multisite trial in Africa) non-inferior to standard of care
- More problematic in higher resource settings
  - Only 1 **in 3 tolerated 5-FC x14 days** in USA (drug-drug, hepatotoxicity, etc)

HIV associated CM

[1] [2]

A People with HIV

First-line therapies

Induction (2 weeks)	Consolidation (8 weeks)
(AIIt) Liposomal amphotericin B 3–4 mg/kg daily plus flucytosine 25 mg/kg four times a day (preferred in high-income settings); or (AI) Single dose liposomal amphotericin B 10 mg/kg and 14 days of flucytosine 25 mg/kg four times a day and fluconazole 1200 mg daily (recommended in low-income settings)	(AI) Fluconazole 400–800 mg daily (800 mg preferred in low-income settings)

Some advocate for repeat LP to assess CSF before **consolidation**

- Mycologic success a/w better outcomes, ↓ relapse, ↓ C-IRIS
  - **Question for the group:** Does two weeks start from sterile cultures?
- Some suggest fluconazole 800 for consolidation in lower-income settings

HIV associated CM

[1] [2]

A People with HIV

First-line therapies

Induction (2 weeks)
(AIIt) Liposomal amphotericin B 3–4 mg/kg daily plus flucytosine 25 mg/kg four times a day (preferred in high-income settings); or
(AI) Single dose liposomal amphotericin B 10 mg/kg and 14 days of flucytosine 25 mg/kg four times a day and fluconazole 1200 mg daily (recommended in low-income settings)

→

Consolidation (8 weeks)
(AI) Fluconazole 400–800 mg daily (800 mg preferred in low-income settings)

→

Maintenance (12 months or until immune restoration)
(AIIt) Fluconazole 200 mg daily

Move to **maintenance** fluconazole 200 for a year

- Or recovery of immune system (CD4 >100)
- Not much data, some use vori / posa / isavu if concerned for toxicity or interactions

SOT associated CM

[1] [2]

B SOT recipients and people without HIV or SOT

First-line therapies

Induction (minimum 2 weeks)	→	Consolidation (8 weeks)	→	Maintenance (12 months)
(AIIt) Liposomal amphotericin B 3–4 mg/kg daily plus flucytosine 25 mg/kg four times a day		(AIIt) Fluconazole 400–800 mg daily		(AIIt) Fluconazole 200 mg daily

- Highest risk in heart and small bowel transplant
  - Serum crypto Ag may be negative (if mild lung dz or lung transplant)
- No RCTs for SOT, guidelines extrapolated from HIV
- **Fun fact:** Quick reduction of immunosuppression (esp calcineurin inhibitors) can cause C-IRIS

Non-HIV, non-SOT associated CM

[1] [2]

B SOT recipients and people without HIV or SOT

First-line therapies

Induction (minimum 2 weeks)	→	Consolidation (8 weeks)	→	Maintenance (12 months)
(AIIt) Liposomal amphotericin B 3–4 mg/kg daily plus flucytosine 25 mg/kg four times a day		(AIIt) Fluconazole 400–800 mg daily		(AIIt) Fluconazole 200 mg daily

- Presentation varies, risk factors are hematologic malignancies or cirrhosis
  - Other medical conditions: Sarcoidosis, rheumatoid arthritis
  - Immunosuppressants: steroids, JAK inhibitors, CLL meds (Ibrutinib, alemtuzumab), fingolimod, eculizumab
- Workup should include thorough history, HIV screen, T cell flow cytometry (CD4/CD8/NK)
  - Consult with immunologist, especially if history of other infections (case #2)

ICP management

- Paramount aspect of acute management
- Needs to be done by removing CSF (not medical management)
  - **Steroids increase mortality** *unless* being used for C-IRIS (case #2)
- Serial LPs, lumbar drains, or ventriculostomies (depending on resources & patient need)
  - At minimum after 2-3 days &/or at 7 days
  - Later in disease course may become **obstructive** hydrocephalus (scarring/inflammation) → **VPS**

- ICP goals (if ICP ≥ 20 cm)
  - Reduce **closing pressure** to 50% of opening pressure (or to normal)
  - No harm in reducing by >50%, as is the case with EVDs

[1] [2]

ART

Unclear how early is too early for starting ART

- **COAT trial stopped early** due to ↑ **mortality in early ART** arm (1-2 wk) vs deferred (5-6 wk)
  - Folks in this trial were on Amb-D + FLC 800 x2 wk (i.e. not current standard of care)
- But in prospective study, patient who got ART @~15 days (after culture negative CSF, on average) had ↓ neurologic complications, ↓ micro relapse, ↓ C-IRIS, and ***trended towards reduced mortality*** @24 wks
  - These folks were on better antifungal medications than in COAT trial

What's a girl to do?

[1] [2]

ART

Unclear how early is too early for starting ART

- **COAT trial stopped early** due to ↑ **mortality in early ART** arm (1-2 wk) vs deferred (5-6 wk)
  - Folks in this trial were on Amb-D + FLC 800 x2 wk (i.e. not current standard of care)
- But in prospective study, patient who got ART @~15 days (after culture negative CSF, on average) had ↓ neurologic complications, ↓ micro relapse, ↓ C-IRIS, and ***trended towards reduced mortality*** @24 wks
  - These folks were on better antifungal medications than in COAT trial

What's a girl to do?

- Generally, **wait 4-6 weeks**, especially in lower resource settings
- Page S71 of supplemental material has guidance, including for those with prior ART exposure who may need to go on second line therapy (case #1)

[1] [2]

Patient: *gets HIV*
Cryptococcus:

Intrathecal (IT) **antimicrobials**

1. Epidemiology, pathophys
2. Recent guidelines on management
3. **Intrathecal?**

Refresher on stuff neurosurgery does

[3] IDSA 2017

Lumbar drain

- Basically an LP but you put a drain in
- Less patient mobility, maybe less accurate over time

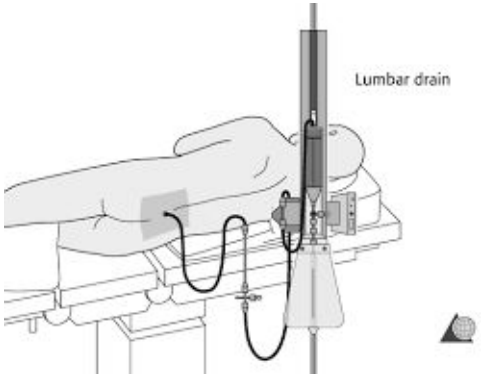

EVD

- Goes in the ventricles, so risk of ventriculitis
  - 1 per 100 EVD days [3]
- Most accurate ICP monitor

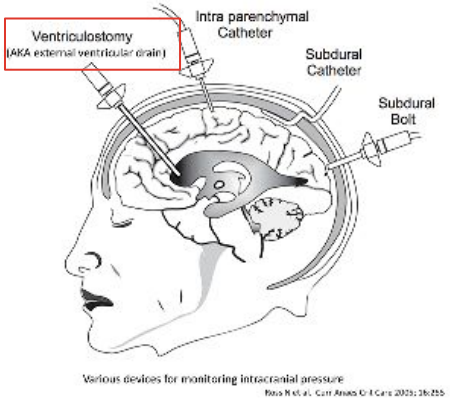

IRRAflow

An EVD capable of irrigating

Maybe higher risk of leak?

Guidelines

Clinical Infectious Diseases
IDSA GUIDELINE

2017 Infectious Diseases Society of America's Clinical Practice Guidelines for Healthcare-Associated Ventriculitis and Meningitis*

Allan R. Tunkel,[1] Rodrigo Hasbun,[2] Adarsh Bhimraj,[3] Karin Byers,[4] Sheldon L. Kaplan,[5] W. Michael Scheld,[6] Diederik van de Beek,[7] Thomas P. Bleck,[8] Hugh J. L. Garton,[9] and Joseph R. Zunt[10]

VII. What is the Role of Intraventricular Antimicrobial Therapy in Patients with Healthcare-Associated Ventriculitis and Meningitis?

Recommendations

55. Intraventricular antimicrobial therapy should be considered for patients with healthcare-associated ventriculitis and meningitis in which the infection responds poorly to systemic antimicrobial therapy alone (strong, low).
56. When antimicrobial therapy is administered via a ventricular drain, the drain should be clamped for 15–60 minutes to allow the agent to equilibrate throughout the CSF (strong, low).
57. Dosages and intervals of intraventricular antimicrobial therapy should be adjusted based on CSF antimicrobial concentrations to 10–20 times the MIC of the causative microorganism (strong, low), ventricular size (strong, low), and daily output from the ventricular drain (strong, low).

[3] IDSA 2017

Guidelines

Ampho specifically

Only mentioned for *Candida* shunt infections that don't respond to IV or shunt removal

Clinical Infectious Diseases

IDSA GUIDELINE

IDSA Infectious Diseases Society of America · hivma hiv medicine association · OXFORD

2017 Infectious Diseases Society of America's Clinical Practice Guidelines for Healthcare-Associated Ventriculitis and Meningitis*

Allan R. Tunkel,[1] Rodrigo Hasbun,[2] Adarsh Bhimraj,[3] Karin Byers,[4] Sheldon L. Kaplan,[5] W. Michael Scheld,[6] Diederik van de Beek,[7] Thomas P. Bleck,[8] Hugh J. L. Garton,[9] and Joseph R. Zunt[10]

VII. What is the Role of Intraventricular Antimicrobial Therapy in Patients with Healthcare-Associated Ventriculitis and Meningitis?

Recommendations

55. Intraventricular antimicrobial therapy should be considered for patients with healthcare-associated ventriculitis and meningitis in which the infection responds poorly to systemic antimicrobial therapy alone (strong, low).
56. When antimicrobial therapy is administered via a ventricular drain, the drain should be clamped for 15–60 minutes to allow the agent to equilibrate throughout the CSF (strong, low).
57. Dosages and intervals of intraventricular antimicrobial therapy should be adjusted based on CSF antimicrobial concentrations to 10–20 times the MIC of the causative microorganism (strong, low), ventricular size (strong, low), and daily output from the ventricular drain (strong, low).

[3] IDSA 2017

Intraventricular antimicrobials: The literature

Not a whole lot there!

- Recent review of all antimicrobials (Clin Microbiol Rev, 2020) [4]
- **RTCs**: Two studies (both bacterial meningitis), no evidence for routine use in meningitis / meningoencephalitis
- **Meta-analysis**: One for GN ventriculitis/meningitis (World Neurosurgery, 2018) [5]
  - 11 studies, 348 patients
  - Promising for carbapenem-resistant bacteria (OR mortality: 0.22; OR eradication 10.06)
  - Not superior for other situations

- For amphotericin specifically
  - No RTCs or systematic reviews on pubmed
  - Only a few cohorts

[4] [5]

Situations to (maybe?) **use IT antimicrobials**

Maybe use in CNS infections with

- Drugs that don't get into CNS easily +/- have systemic toxicity
  - Aminoglycosides, colistin, daptomycin, tigecycline, and vancomycin
- MRD pathogens
  - MRSA, VRE, CRE, CRAB
  - Often seen in external / internal ventricular shunt infections

Maybe don't use if

- Antibiotics has risk for seizures when given IV (beta lactams)
  - Please don't give imipenem in the CNS
  - Some data to indicate increased risk of seizures from IT therapy generally
- Doesn't have an EVD for other reasons
  - Procedure has risks, IT catheters can cause nosocomial infections themselves
- Authors of the review point out some of the historic toxicity may have been from inappropriate dosing

[4] [3]

IT amphotericin

Dosing: 0.1 - 0.5 mg q24h (1mg q24h for AmBisome)

- Complicated pharmacology
- Authors suggest co-administration of systemic antimicrobials to prevent selection pressure for MDRs in the other compartments

Side effects: Fever, **arachnoiditis**, nausea/emesis, **Parkinson syndrome**, tinnitus, encephalopathy

Effectiveness: One study from 1986

	Systemic + IT (n=6)	**Systemic alone** (n=7)	**P value**
Death	1 (16%)	6 (86%)	P=0.025
CSF sterilized	6 (100%)	3 (43%)	P=0.049

[4]

Thoughts? Questions?

https://febrilepodcast.com/episode-17-yeastie-boys/