



A visit to the dentist

- Part 2 -

CLINID conference

Hunter Ratliff

05/15/2025

*Ages, dates, and other identifying information may have been changed
I have no conflict of interest in relation to this presentation*

Shortcuts



Case 3: [Start](#) | [Summary slide](#) (legionella in immunosuppressed)

Case 4: [Start](#) | [Summary slide](#) (same patient, now nocardia)

Case 5: [Start](#) (staph aureus after flu)

Case 6: [Start](#) | [Summary slide](#) (strep anginosus)

Discussion: [Objectives](#)

- **Legionella** | testing | treatment
- **Does it cause hyponatremia**

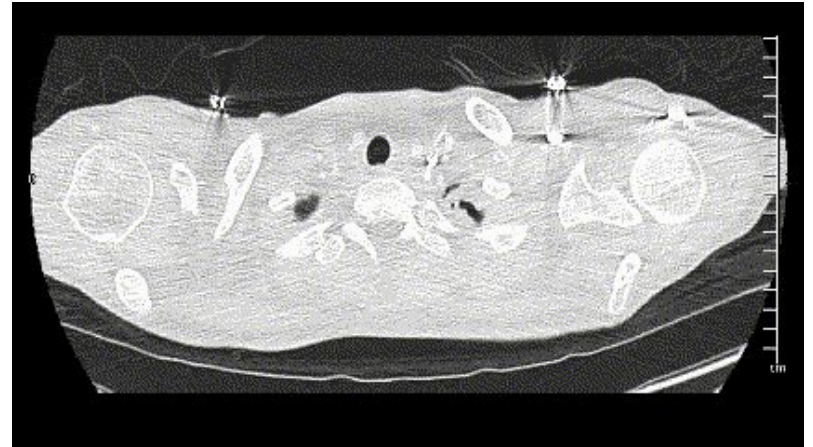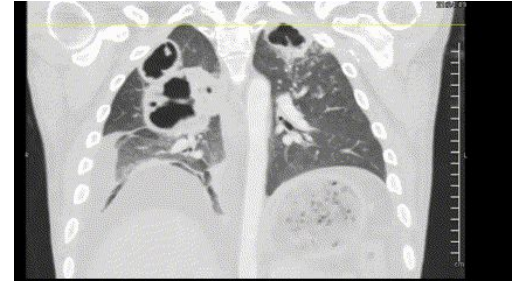
[Takeaway slide](#)

Updates on prior cases

Case #1

Case 1: Kleb/Crypto

A **27 y/o M** with PMH including **poorly controlled DM**, recent NSTI of groin p/w chronic groin **wound drainage** & productive cough and found to have **numerous cavitary lesions**

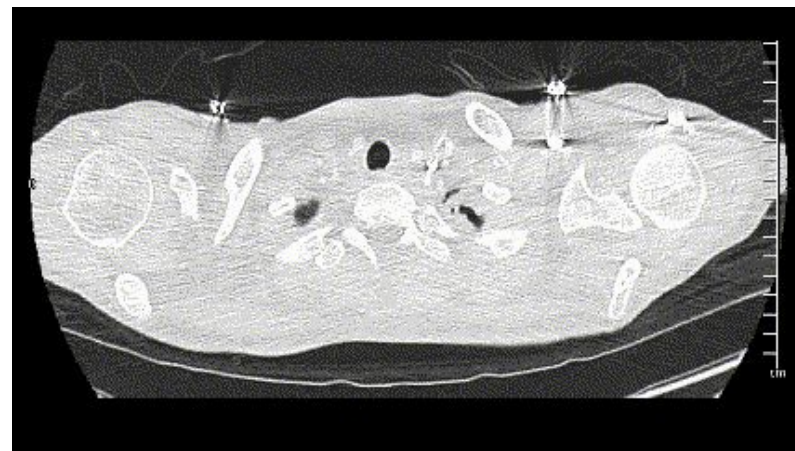
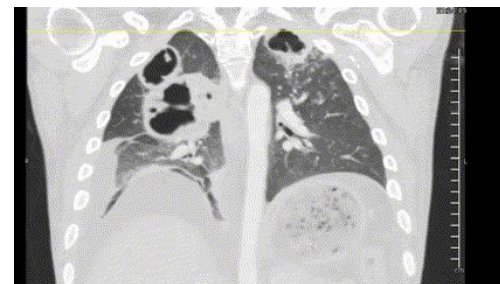


Case 1: Kleb/Crypto

A **27 y/o M** with PMH including **poorly controlled DM**, recent NSTI of groin p/w chronic groin **wound drainage** & productive cough and found to have **numerous cavitary lesions** that have grown mucoid **kleb pneumo**, but **serum CrAG** was also strongly positive

Micro	Result
BAL (routine)	>100k mucoid kleb pneumo

Date	CrAG
Day 2	1 : 1280
Day 3	1 : 320



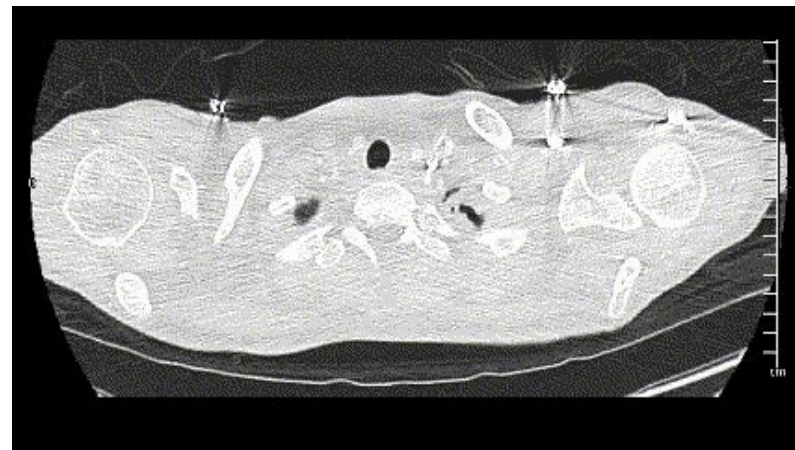
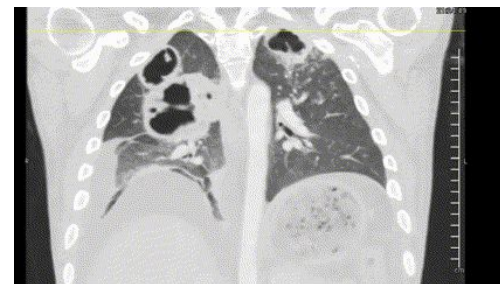
Case 1: Kleb/Crypto

A **27 y/o M** with PMH including **poorly controlled DM**, recent NSTI of groin p/w chronic groin **wound drainage** & productive cough and found to have **numerous cavitary lesions** that have grown mucoid **kleb pneumo**, but **serum CrAG** was also strongly positive

- ❖ **Augmentin** (6 weeks)
 - Repeat CT
- ❖ **Fluconazole** (6 months?)

Micro	Result
BAL (routine)	>100k mucoid kleb pneumo

Date	CrAG
Day 2	1 : 1280
Day 3	1 : 320



Case 1: Updates since conference



Telephone Visit

Case 1: Updates since conference



Telephone



Patient Message



Appointment

WVU RUBY CT CAP..



Appointment

WVU RUBY CT CAP..



Telephone Visit


Plan:

- Will obtain repeat CT chest to assess radiographic response to treatment
- Ordered repeat labs (CBC, CMP, CRP) as we don't have any labs since he left WVUH
- Appears he has been lost to pulm follow up, will refer to Wheeling pulm clinic
- Prefers to follow with ID closer to home, so will refer to Wheeling ID as well
- Refilled fluconazole, anticipate duration of 6-12 months
- Given clinical stability (admittedly, only able to base this off HPI) will hold off further antibacterials until CT chest is back

RTC: 1 mo (Prefers Wheeling)

Hunter Ratliff, MD


Case 1: Updates since conference

 Telephone

 Patient Message

 Appointment WVU RUBY CT CAP..


 Appointment WVU RUBY CT CAP..


 Telephone Visit

- Hopelessly lost to follow up
- No imaging
- Does refill his fluconazole

Case 1: Updates since conference

 Hospital Encounter

 Telephone

 Patient Message

× Appointment WVU RUBY CT CAP..












× Appointment WVU RUBY CT CAP..

 Telephone Visit

Admitted to Ruby

- Admitted with..?

Case 1: Updates since conference

 Admission (Discharged)	Inpatient	Uncontrolled type 1 diabet...
 Admission (Discharged)	Inpatient	Cavitory lung disease
 ED to Hosp-Admission (Dis...	Inpatient	DKA (diabetic ketoacidosis)
<hr/>		
 ED to Hosp-Admission (Dis...	Inpatient	Hyperglycemia
 ED to Hosp-Admission (Dis...	Observation	DKA (diabetic ketoacidosis)
 Admission (Discharged)	Observation	DKA (diabetic ketoacidosis)
 ED to Hosp-Admission (Dis...	Inpatient	Acute metabolic encephal...
<hr/>		
 ED to Hosp-Admission (Dis...	Inpatient	DKA (diabetic ketoacidosis)
 ED to Hosp-Admission (Dis...	Observation	DKA (diabetic ketoacidosis)
 ED to Hosp-Admission (Dis...	Inpatient	DKA (diabetic ketoacidosis)
 ED to Hosp-Admission (Dis...	Inpatient	DKA (diabetic ketoacidosis)
<hr/>		
 Admission (Discharged)	Inpatient	DKA (diabetic ketoacidosis)

Admitted to Ruby (DKA)

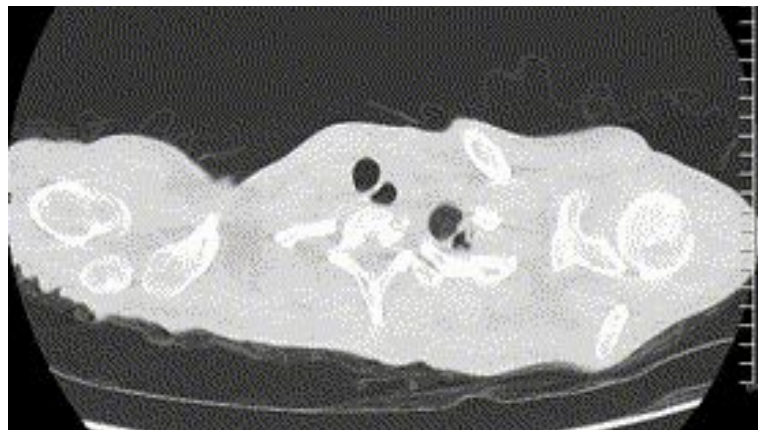
- No real infectious concerns
- They get a CT chest (as one does for DKA)

Case 1: Updates since conference

Admission (Discharged)	Inpatient	Uncontrolled type 1 diabet...
Admission (Discharged)	Inpatient	Cavitary lung disease
ED to Hosp-Admission (Dis...	Inpatient	DKA (diabetic ketoacidosis)
ED to Hosp-Admission (Dis...	Inpatient	Hyperglycemia
ED to Hosp-Admission (Dis...	Observation	DKA (diabetic ketoacidosis)
Admission (Discharged)	Observation	DKA (diabetic ketoacidosis)
ED to Hosp-Admission (Dis...	Inpatient	Acute metabolic encephal...
ED to Hosp-Admission (Dis...	Inpatient	DKA (diabetic ketoacidosis)
ED to Hosp-Admission (Dis...	Observation	DKA (diabetic ketoacidosis)
ED to Hosp-Admission (Dis...	Inpatient	DKA (diabetic ketoacidosis)
ED to Hosp-Admission (Dis...	Inpatient	DKA (diabetic ketoacidosis)
Admission (Discharged)	Inpatient	DKA (diabetic ketoacidosis)

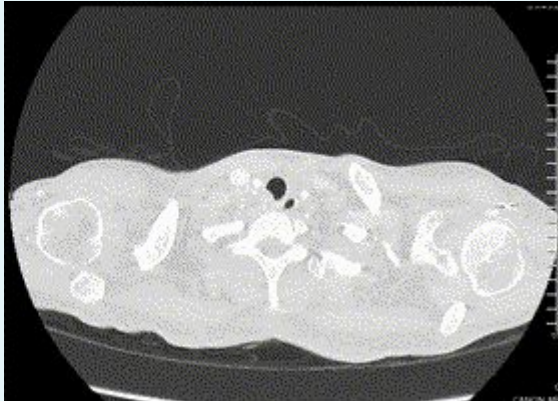
Admitted to Ruby (DKA)

- No real infectious concerns
- They get a CT chest (as one does for DKA)



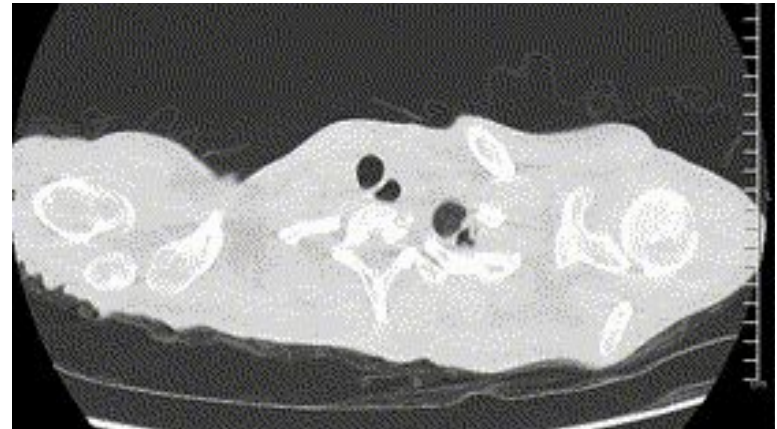
Case 1: Updates since conference

Last conference (2 months ago)



Admitted to Ruby (DKA)

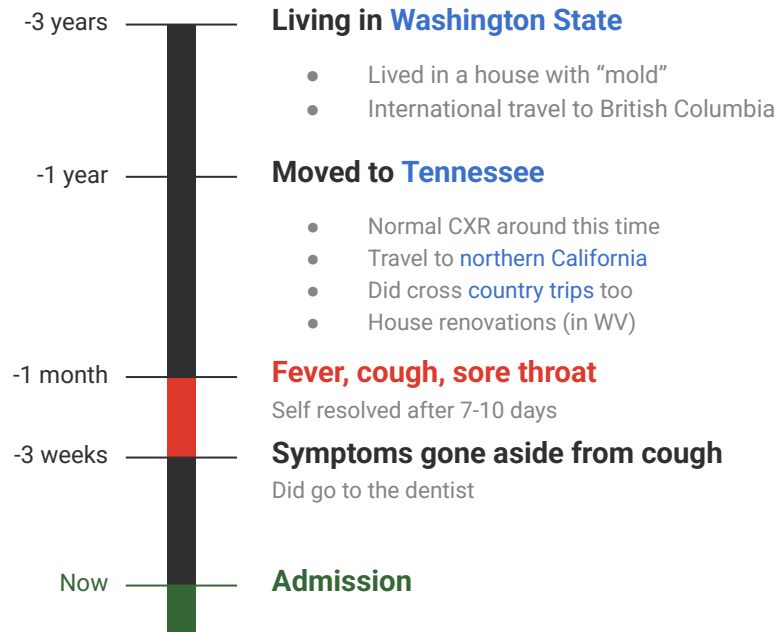
- No real infectious concerns
- They get a CT chest (as one does for DKA)



Case #2

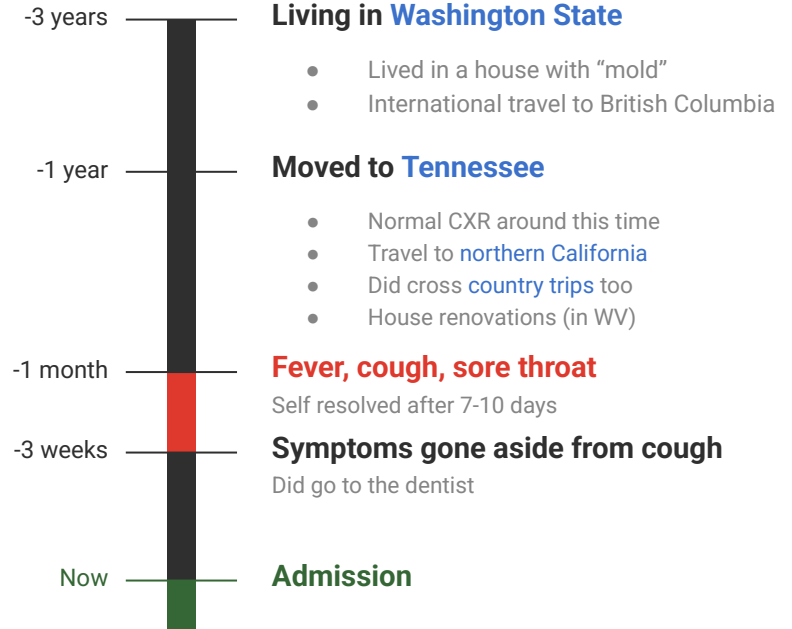
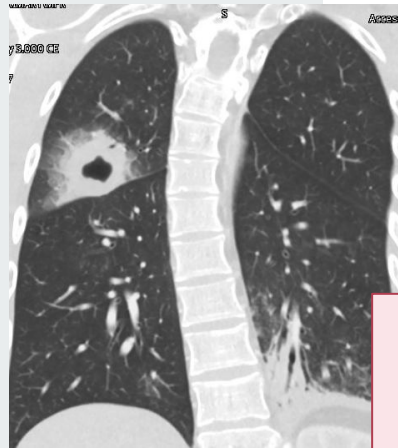
Case 2: Coccidioides

A **22 y/o M** with no PMH who p/w **subacute cough** x 1 month. Found to have a new 4cm RUL cavity, 1cm LLL nodule (vs XR 14 mo ago)



Case 2: Coccidioides

A **22 y/o M** with no PMH who p/w **subacute cough** x 1 month. Found to have a new 4cm RUL cavity, 1cm LLL nodule (vs XR 14 mo ago)



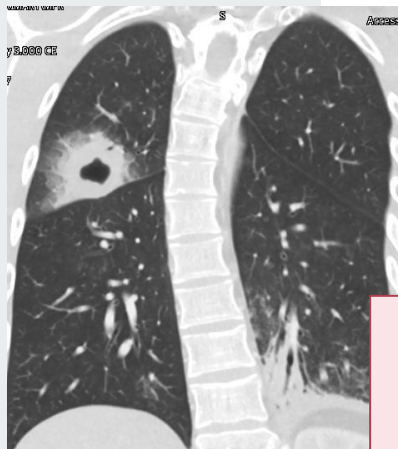
Coccidioides antibody, serum

Complement fixation
Antibody detected (**1:2**)

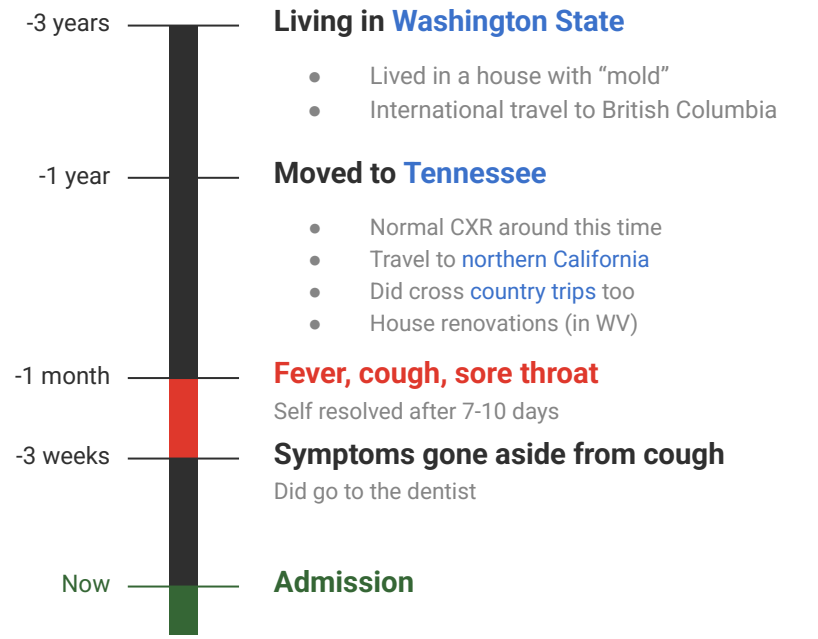
Immunodiffusion
Antibody not detected

Case 2: Coccidioides

A **22 y/o M** with no PMH who p/w **subacute cough** x 1 month. Found to have a new 4cm RUL cavity, 1cm LLL nodule (vs XR 14 mo ago)









Augmentin (4 weeks)



Coccidioides antibody, serum

Complement fixation Antibody detected (1:2)	Immunodiffusion Antibody not detected
--	---

Case 1: Updates since conference

	Office Visit	O.. N.. PULMONARY-POC
	CT Scan	H.. W.. CT RUBY
	Nurse Triage	PULMONARY-POC
	Documentation ...	INFECTIOUS DISEA
	Documentation ...	INFECTIOUS DISEA
	ED to Hosp-Ad...	I... 8ESD - Decicco, Dar

Spoke with patient on [REDACTED] Reviewed lab results with the patient. Patient denies antibiotic side effects. States he still has to clear his throat sometimes and has an occasional cough. Denies further symptoms. Overall feels improved since hospitalization. Patient inquired about stopping antibiotics at this time since he's completed almost 3 weeks of therapy. Explained discussion with Dr. Juskowich - okay to stop at this time per patient request. Encouraged patient to keep ID follow up appointment and reach out to the clinic if he develops any new symptoms or clinically worsens in any way. Patient displayed understanding. He denied any further questions.

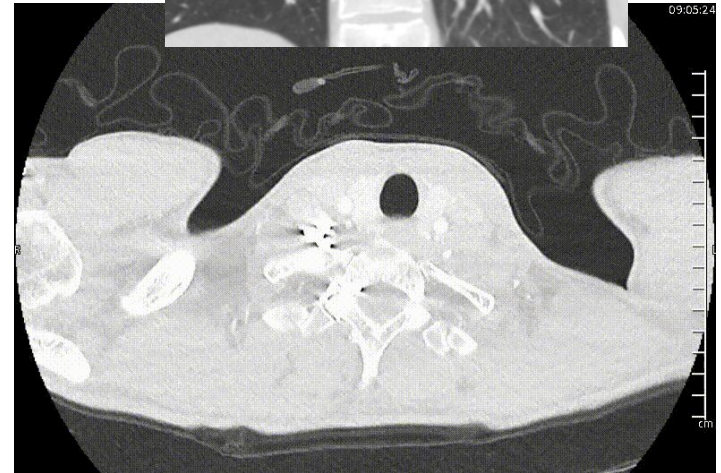
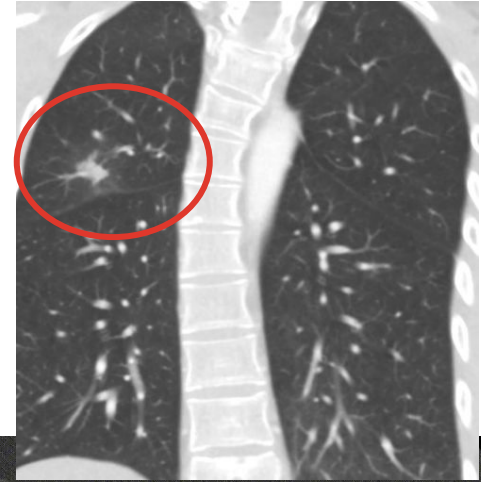
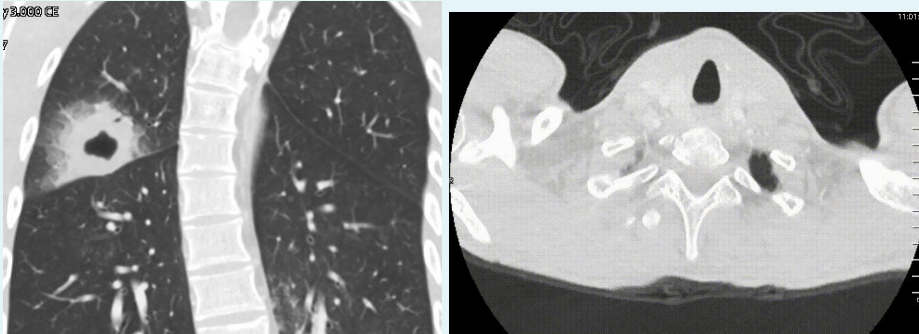
Of note, patient stated he would need to reschedule ID follow up. Patient to request adjustment via MyChart.

Amy Spigelmyer, PharmD, BCIDP
Infectious Diseases Clinical Pharmacist







Case 1: Updates since conference

👤 Office Visit	O.. N.. PULMONARY-POC
👤 CT Scan	H.. W.. CT RUBY
📞 Nurse Triage	PULMONARY-POC
📄 Documentation ...	INFECTIOUS DISEA

Last conference (1.5 months ago)



Case 1: Updates since conference

	Office Visit	O.. N.. PULMONARY-POC
	CT Scan	H.. W.. CT RUBY
	Nurse Triage	PULMONARY-POC
	Documentation ...	INFECTIOUS DISEA
	Documentation ...	INFECTIOUS DISEA
	ED to Hosp-Ad...	I... 8ESD - Decicco, Dar

Pulmonology clinic

- Doing great
- RTC: PRN

New cases!

Case #3

Case 3: HPI

A **60 y/o M** with PMH including untreated large granular lymphocytic leukemia, TTP (on pred 20) p/w

- **Hypoxia**
- **AMS**
- **Hyponatremia**

Case 3: HPI

A **60 y/o M** with PMH including untreated large granular lymphocytic leukemia, TTP (on pred 20) p/w **AMS, hyponatremia, & hypoxia**

- Generally feeling weak for **past week**
- **Productive** cough
- Unable to ascertain further symptoms

Case 3: HPI

A **60 y/o M** with PMH including untreated large granular lymphocytic leukemia, TTP (on pred 20)
p/w **AMS, hyponatremia, & hypoxia**

- Generally feeling weak for past week
- Productive cough
- Unable to ascertain further symptoms

Medical Hx / medications

Leukemia: Not on meds / chemo

Admission one **month ago** for non-ID reasons

Case 3: HPI

A **60 y/o M** with PMH including untreated large granular lymphocytic leukemia, TTP (on pred 20) p/w **AMS, hyponatremia, & hypoxia**

- Generally feeling weak for past week
- Productive cough
- Unable to ascertain further symptoms

Medical Hx / medications

Leukemia: Not on meds / chemo

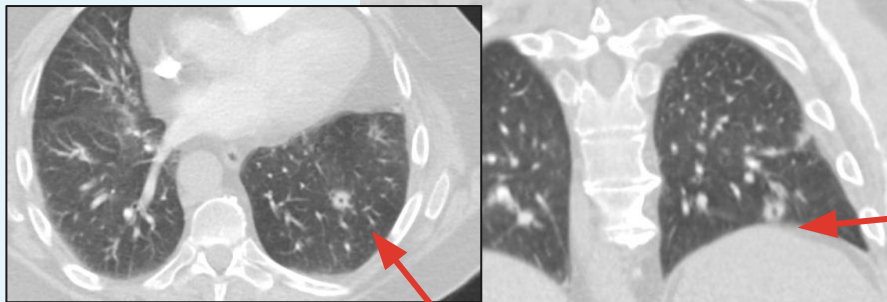
Admission one **month ago** for non-ID reasons

- Dx with **hyperviscosity syndrome**, perhaps MGUS?
- Also had w/up for *thrombocytopenia*, favored to be **TTP**
 - Start prednisone 20
 - No PJP ppx

Case 3: HPI

A **60 y/o M** with PMH including untreated large granular lymphocytic leukemia, TTP (on pred 20) p/w **AMS, hyponatremia, & hypoxia**

1.5 months ago



Medical Hx / medications

Leukemia: Not on meds / chemo

Admission one **month ago** for non-ID reasons

- Dx with **hyperviscosity syndrome**, perhaps MGUS?
- Also had w/up for *thrombocytopenia*, favored to be **TTP**
 - Start prednisone 20
 - No PJP ppx
- Incidental **left lower lobe** lung mass
 - 10 x 12 mm

Case 3: Exposure History



Geographic & Travel	<ul style="list-style-type: none">• Lives in West Virginia• Never international travel
Occupational	<ul style="list-style-type: none">• Cattle farmer
Substance & needles	<ul style="list-style-type: none">• No EtOH, tobacco, drugs• No needle exposures
Animals	<ul style="list-style-type: none">• Cattle
Exposures & hobbies	<ul style="list-style-type: none">• Does work outdoors, namely with the cattle• No known TB risk factors

Case 3: Exam (per MICU note)

Vitals: 36.5 | 71 | **101/63** | 96%

General: appears chronically ill

Eyes: Conjunctiva clear, Pupils equal and round, Sclera non-icteric

HENT: Head atraumatic and normocephalic. **Vesicular/blisters under lower lip.** Two ulcers on lower lip that is blood filled but contained.

Neck: Trachea Midline

Lungs: Clear to auscultation bilaterally

Cardiovascular: Regular rate and rhythm, no murmur, click, rub or gallop

Abdomen: Soft, non-tender, Bowel sounds normal, non-distended

Extremities: No cyanosis or edema

Skin: Skin warm and dry

Neurologic: Alert and oriented x 3. **Answers questions but has confusion.**

Case 3: Labs

CBC	Result
WBC	23.7
Hgb	9.5
Platelets	113
Neut %	25%
Lymph %	72%
Eos %	0%

Chem7	Result
Na	107
K	2.9
Cl	82
HCO3	12
Cr	1.16

Misc	Result
sOsm	288
Lactate	5.3
LFTs	WNL

Case 3: Labs

CBC	Result
WBC	23.7
Hgb	9.5
Platelets	113
Neut %	25%
Lymph %	72%
Eos %	0%

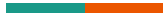Chem7	Initial
Na	107
K	2.9
Cl	82
HCO3	12
Cr	1.16

5 hour repeat


Chem7	Repeat	VBG
Na	127	131
K	3.4	3.8
Cl	102	99
HCO3	16	20
Cr	1.32	---

Misc	Initial	Repeat
sOsm	288	281
Lactate	5.3	2.6
LFTs	WNL	

[Q3.1] DDx



free response, vote



Mentimeter

We will vote on these

[3.1] What is the differential diagnosis?

Legionella

5

Popular

Cryptococcus

3

PJP

2

legionella lung abcess endemic
mycosis

2

Strep

2

[Q3.2] Additional work up?



Word cloud



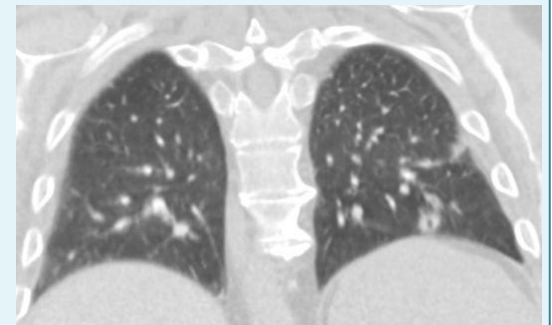
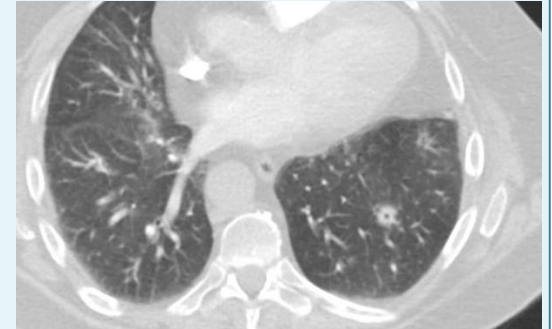
[3.2] Additional workup?

urine histo serum crypto
urinary ag serum crypto antigen
urine legionella ag lp bal legio strep antigen
bal cultures gms
legionella urine antigen

Case 3: Imaging

A **60 y/o M** with PMH including untreated large granular lymphocytic leukemia, TTP (on pred 20) p/w **AMS, hyponatremia, & hypoxia**

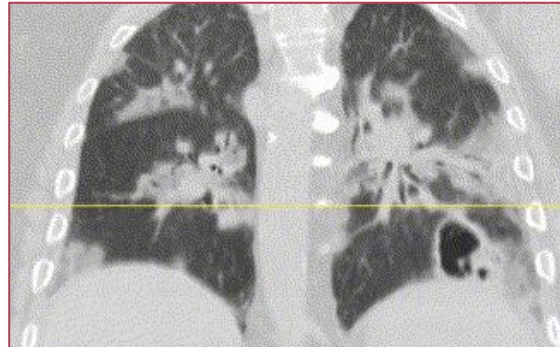
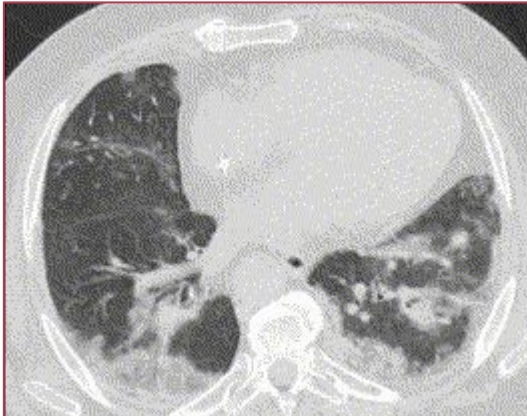1.5 months ago



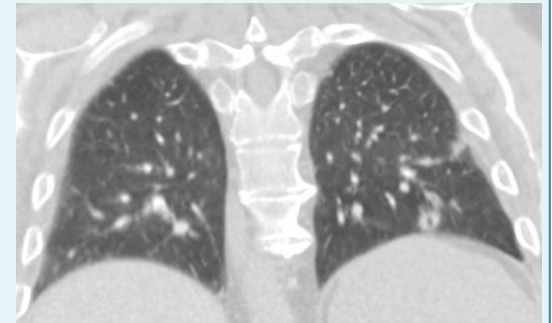
Case 3: Imaging

Interval increased size of a LLL lesion with cavitation (1.2 → 2.8 cm).
A halo of groundglass opacity surrounds this consolidation

Impression: Constellation of findings are compatible with fungal infection in the lung, with concern for focal invasive aspergillosis



1.5 months ago



[Q3.3] invasive aspergillosis or something else?



Slider response (disagree vs agree)


This is invasive aspergillosis (specifically)

This is a fungal infection

This is a cavitory pneumonia

Strongly disagree

Strongly agree



Mentimeter

Is this invasive aspergillosis or something else?

[3.3] Do we agree with radiology?

This is invasive aspergillosis (specifically)

2.6

This is a fungal infection

3.4

This is a cavitary pneumonia

4.4

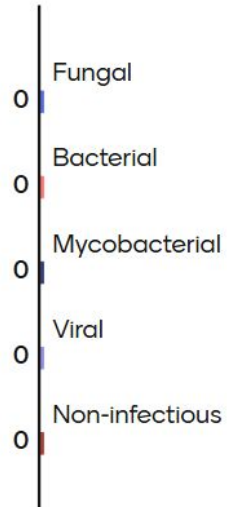
Strongly disagree

Strongly agree

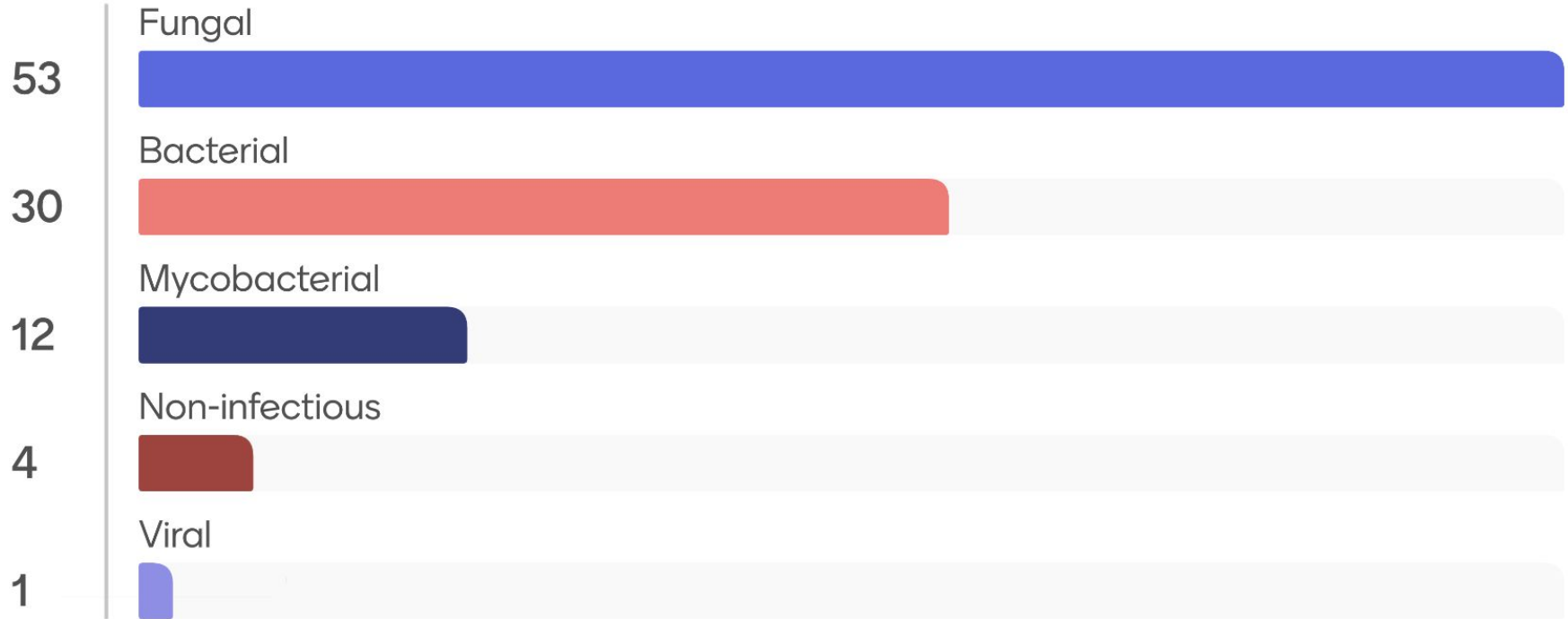
[Q3.4] What's going on?



Distribute responses (on 100pt scale)



[3.4] What kind of process is going on?



Case 3: Workup

Serum / Urine	Result
Histo Ag	
Blasto Ag	
Crypto Ag	
Fungitell	
Asp GM	
Legionella Ag	
QuantGOLD	

BAL	Result
Asp GM	
Asp PCR	
MTB PCR	
PJP PCR	
Legionella DNA	

Resp Biofire	Result
...	

Micro	Result
Blood	
Urine	
BAL (routine)	
BAL (AFB)	
BAL (fungal)	

Case 3: Workup

Serum / Urine	Result
Histo Ag	Neg
Blasto Ag	Neg
Crypto Ag	Neg
Fungitell	<31
Asp GM	Neg
Legionella Ag	Pos
QuantGOLD	Neg

BAL	Result
Asp GM	
Asp PCR	
MTB PCR	
PJP PCR	
Legionella DNA	

Resp Biofire	Result
...	

Micro	Result
Blood	
Urine	
BAL (routine)	
BAL (AFB)	
BAL (fungal)	

Case 3: Workup

Serum / Urine	Result
Histo Ag	Neg
Blasto Ag	Neg
Crypto Ag	Neg
Fungitell	<31
Asp GM	Neg
Legionella Ag	Pos
QuantGOLD	Neg

BAL	Result
Asp GM	Neg
Asp PCR	Neg
MTB PCR	Neg
PJP PCR	Neg
Legionella DNA	Neg

Resp Biofire	Result
...	

Micro	Result
Blood	
Urine	
BAL (routine)	
BAL (AFB)	
BAL (fungal)	

Case 3: Workup

Serum / Urine	Result
Histo Ag	Neg
Blasto Ag	Neg
Crypto Ag	Neg
Fungitell	<31
Asp GM	Neg
Legionella Ag	Pos
QuantGOLD	Neg

BAL	Result
Asp GM	Neg
Asp PCR	Neg
MTB PCR	Neg
PJP PCR	Neg
Legionella DNA	Neg

Micro	Result
Blood	
Urine	
BAL (routine)	
BAL (AFB)	
BAL (fungal)	

Resp Biofire	Result
Metapneumovirus	Pos
Parainfluenza 4	Pos

Case 3: Workup

Serum / Urine	Result
Histo Ag	Neg
Blasto Ag	Neg
Crypto Ag	Neg
Fungitell	<31
Asp GM	Neg
Legionella Ag	Pos
QuantGOLD	Neg

BAL	Result
Asp GM	Neg
Asp PCR	Neg
MTB PCR	Neg
PJP PCR	Neg
Legionella DNA	Neg

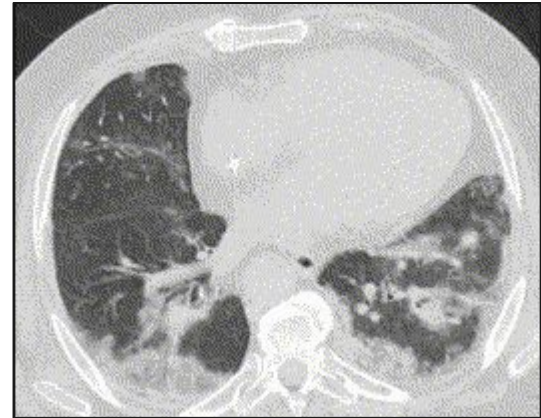
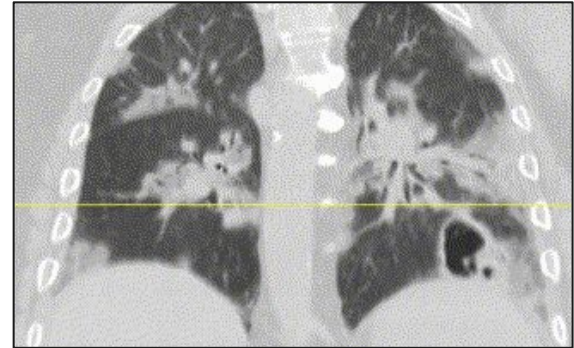
Resp Biofire	Result
Metapneumovirus	Pos
Parainfluenza 4	Pos

Micro	Result
Blood	Neg
Urine	Neg
BAL (routine)	NG
BAL (AFB)	NG
BAL (fungal)	C. tropicalis

Case 3: Summary

A **60 y/o M** with PMH including untreated T-cell LGL, ITP/TTP (on pred 20) p/w AMS, ~~hyponatremia~~, & hypoxia found to have expanding LLL cavitory lesion w/ halo sign

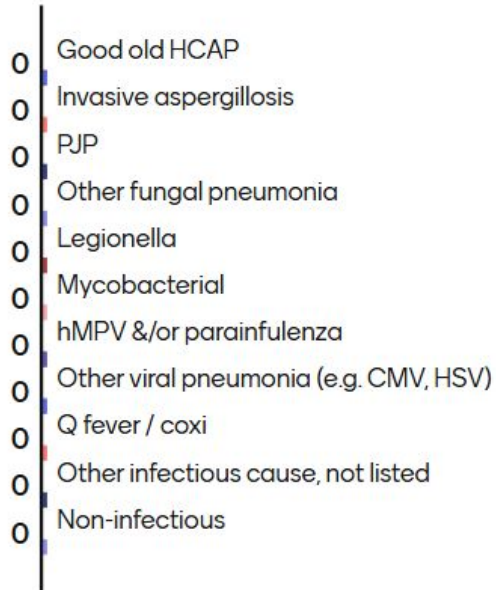
- Biofire: **hMPV, paraflu**
- Urine legionella: positive
- BAL: normal



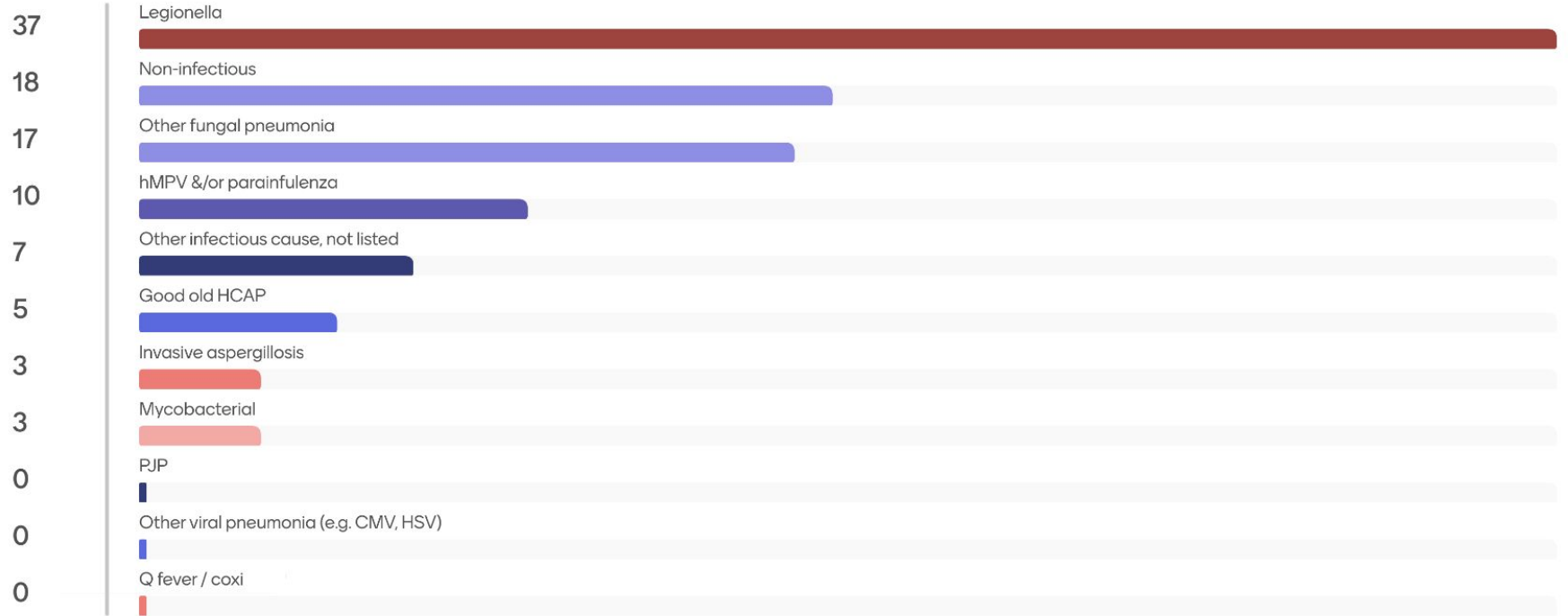
[Q3.5] DDX now?

What is driving his pulmonary process?

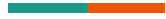Distribute responses (on 100pt scale)




[3.5] What is driving his pulmonary process?



[Q3.6] How long to treat for legionella



Guess the number



Mentimeter

Using levofloxacin, in days

[3.6] How long would you treat the legionella?

✓ 14 Accepted: 10-18



Case 3: Hospital course

Legionella

- Improved with 2 weeks of **levofloxacin**

Fungal pneumonia?

- Initially on AmBisome
- Transitioned to **voriconazole** once all the studies came back normal
- Plan for **3+ month** course with reimaging

Case 3: Hospital course

Legionella

- Improved with 2 weeks of **levofloxacin**
- Quickly **worsened after stopping**
 - Improved with resuming
- Extended course to total of **4 weeks**

Fungal pneumonia?

- Initially on AmBisome
- Transitioned to **voriconazole** once all the studies came back normal
- Plan for **3+ month** course with reimaging

Case 3: Hospital course

Legionella

- Improved with 2 weeks of **levofloxacin**
- Quickly **worsened after stopping**
 - Improved with resuming
- Extended course to total of **4 weeks**

Fungal pneumonia?

- Initially on AmBisome
- Transitioned to **voriconazole** once all the studies came back normal
- Plan for **3+ month** course with reimaging

CMV viremia (skipped over this)
Treated with **Valcyte** until virally suppressed
PCR: 15k → 544

Herpes labialis: Treated with Valcyte (due to above)

Case 3: Hospital course

Legionella

- Improved with 2 weeks of **levofloxacin**
- Quickly **worsened after stopping**
 - Improved with resuming
- Extended course to total of **4 weeks**

Fungal pneumonia?

- Initially on AmBisome
- Transitioned to **voriconazole** once all the studies came back normal
- Plan for **3+ month** course with reimaging

CMV viremia (skipped over this)
Treated with **Valcyte** until virally suppressed
PCR: 15k → 544

Herpes labialis: Treated with Valcyte (due to above)

Steroids/PJP
Remained on steroids so started **atovaquone** 1500 q24h

Case 3: Hospital course

Legionella

- Improved with 2 weeks of **levofloxacin**
- Quickly **worsened after stopping**
 - Improved with resuming
- Extended course to total of **4 weeks**

Fungal pneumonia?

- Initially on AmBisome
- Transitioned to **voriconazole** once all the studies came back normal
- Plan for **3+ month** course with reimaging

Some concerns for drug interactions, so **switched vori to Cresemba**

CMV viremia (skipped over this)
Treated with **Valcyte** until virally suppressed
PCR: 15k → 544

Herpes labialis: Treated with Valcyte (due to above)

Steroids/PJP
Remained on steroids so started **atovaquone** 1500 q24h

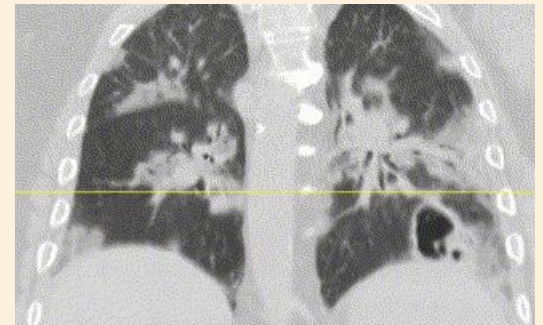
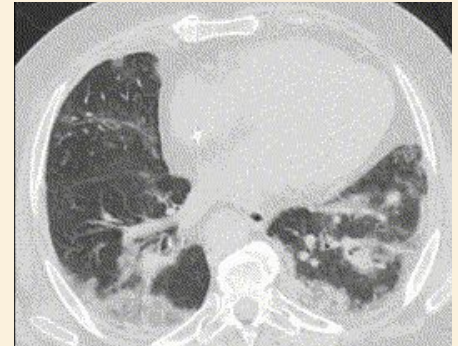Case #3.5

He's back...

Case 4: HPI

A **60 y/o M** with PMH including untreated large granular lymphocytic leukemia, **TTP** (on **pred 20** for past two months), recent admission for legionella p/w **worsening respiratory status**

Recent admission

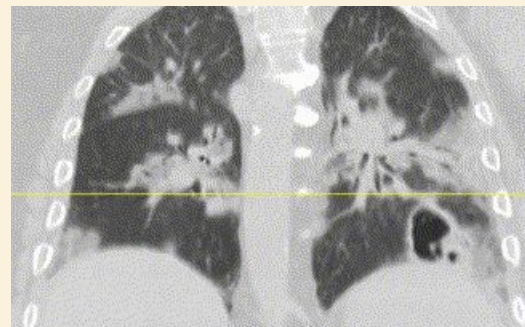
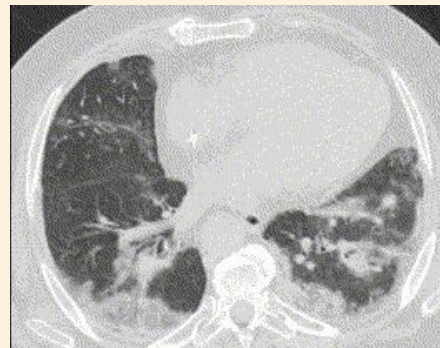

Case 4: HPI

A **60 y/o M** with PMH including untreated large granular lymphocytic leukemia, **TTP** (on **pred 20** for past two months), recent admission for legionella p/w **worsening respiratory status**

Only was out of the **hospital for 1-2 days**, now **intubated**

Recent admission



Case 4: HPI

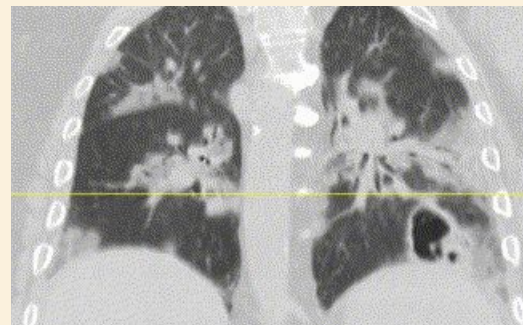
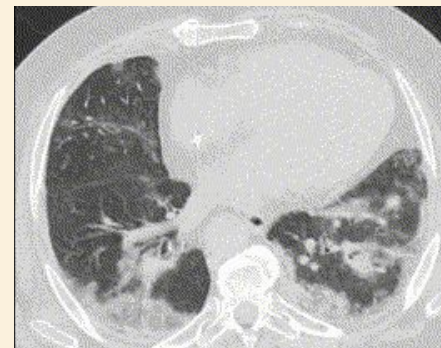A **60 y/o M** with PMH including untreated large granular lymphocytic leukemia, **TTP** (on **pred 20** for past two months), recent admission for legionella p/w **worsening respiratory status**

Only was out of the **hospital for 1-2 days**, now **intubated**

Respiratory status has declined **despite:**


- Negative workup (aside from legionella & viruses)
- Levofloxacin
- Cresemba
- Valcyte
- Atovaquone ppx

Recent admission

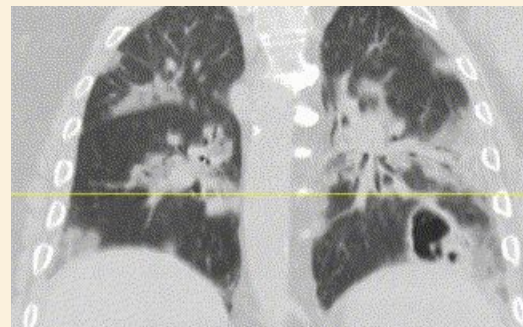
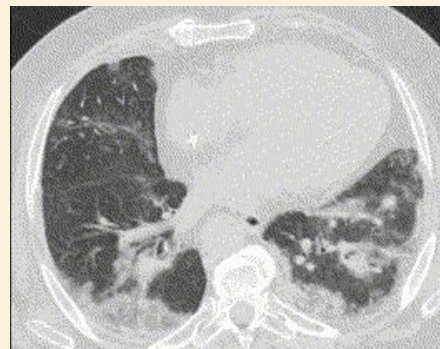

Case 4: HPI

A **60 y/o M** with PMH including untreated large granular lymphocytic leukemia, **TTP** (on **pred 20** for past two months), recent admission for legionella p/w **worsening respiratory status**




Recent admission



Case 4: Summary

A **60 y/o M** with PMH including untreated large granular lymphocytic leukemia, **TTP** (on **pred 20** for past two months), recent admission for legionella p/w **worsening respiratory status**


Only was out of the **hospital for 1-2 days**, now **intubated** despite levofloxacin, Cresemba, Valcyte, & atovaquone



[Q4.1] DDx now? Why is he getting worse?



Free response



Mentimeter

[4.1] Why is the patient getting worse?

Legionella

Fusarium

Mucor

Histo

Case 4: Prior workup (last admission)

Serum / Urine	Result
Histo Ag	Neg
Blasto Ag	Neg
Crypto Ag	Neg
Fungitell	<31
Asp GM	Neg
Legionella Ag	Pos
QuantGOLD	Neg

BAL	Result
Asp GM	Neg
Asp PCR	Neg
MTB PCR	Neg
PJP PCR	Neg
Legionella DNA	Neg

Micro	Result
Blood	Neg
Urine	Neg
BAL (routine)	NG
BAL (AFB)	NG
BAL (fungal)	C. tropicalis

Case 4: Prior workup (last admission)

Serum / Urine	Result
Histo Ag	Neg
Blasto Ag	Neg
Crypto Ag	Neg
Fungitell	<31
Asp GM	Neg
Legionella Ag	Pos
QuantGOLD	Neg

BAL	Result
Asp GM	Neg
Asp PCR	Neg
MTB PCR	Neg
PJP PCR	Neg
Legionella DNA	Neg

Micro	Result
Blood	Neg
Urine	Neg
BAL (routine)	NG
BAL (AFB)	NG
BAL (fungal)	C. tropicalis Nocardia nova

24 days after
BAL

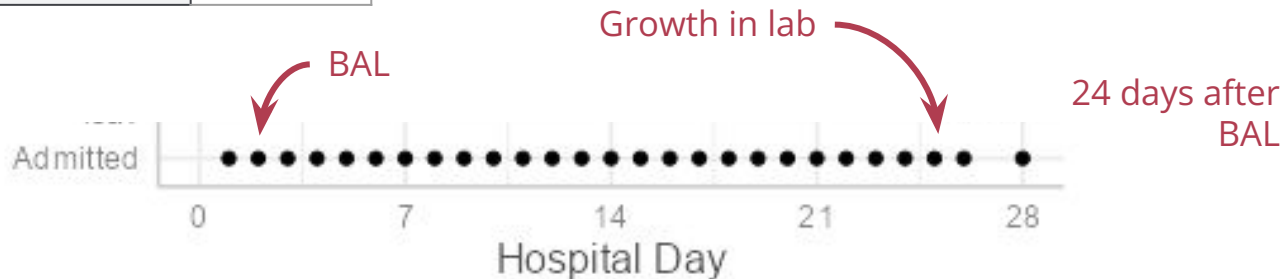

Case 4: Prior workup (last admission)

Serum / Urine	Result
Histo Ag	Neg
Blasto Ag	Neg
Crypto Ag	Neg
Fungitell	<31
Asp GM	Neg
Legionella Ag	Pos
QuantGOLD	Neg

BAL	Result
Asp GM	Neg
Asp PCR	Neg
MTB PCR	Neg
PJP PCR	Neg
Legionella DNA	Neg

Micro	Result
Blood	Neg
Urine	Neg
BAL (routine)	NG
BAL (AFB)	NG
BAL (fungal)	C. tropicalis Nocardia nova



Cases 3-4: Nocardia nova

- Very, **very late growth** of Nocardia (24 days after BAL)

Tobramycin	32 (R)
Linezolid	1 (S)
Bactrim	.25/4.8 (S)
Doxycycline	8 (R)
Ciprofloxacin	16 (R)
Augmentin	128 (R)
Moxifloxacin	4 (R)
Amikacin	<0.5 (S)
Imipenem	2 (S)
Ceftriaxone	32 (I)
Clarithromycin	<.03 (S)
Minocycline	4 (I)

Cases 3-4: Nocardia nova

- Very, **very late growth of Nocardia** (24 days after BAL)
- Missed during prior admission
 - To be fair, he was discharged the next day and readmitted 2 days later
 - So while Nocardia Tx wasn't started until 28 days after BAL, only went 4 days without treatment (from time of results)

Tobramycin	32 (R)
Linezolid	1 (S)
Bactrim	.25/4.8 (S)
Doxycycline	8 (R)
Ciprofloxacin	16 (R)
Augmentin	128 (R)
Moxifloxacin	4 (R)
Amikacin	<0.5 (S)
Imipenem	2 (S)
Ceftriaxone	32 (I)
Clarithromycin	<.03 (S)
Minocycline	4 (I)

Cases 3-4: Nocardia nova

- Very, **very late growth of Nocardia** (24 days after BAL)
- Missed during prior admission
 - To be fair, he was discharged the next day and readmitted 2 days later
 - So while Nocardia Tx wasn't started until 28 days after BAL, only went 4 days without treatment (from time of results)
- Multiple other (non-infectious issues) developed while in MICU (stokes, CRRT, etc)
- Went CMO after palliative consult

Tobramycin	32 (R)
Linezolid	1 (S)
Bactrim	.25/4.8 (S)
Doxycycline	8 (R)
Ciprofloxacin	16 (R)
Augmentin	128 (R)
Moxifloxacin	4 (R)
Amikacin	<0.5 (S)
Imipenem	2 (S)
Ceftriaxone	32 (I)
Clarithromycin	<.03 (S)
Minocycline	4 (I)

Case #5

Case 5: HPI

A **37 y/o M** with PMH including poorly controlled DM (A1c **9.7**), TBI, sacral decubitus ulcer p/w **DKA & hypoxia**

Case 5: HPI

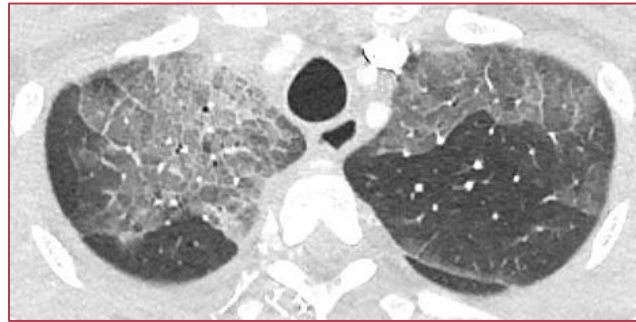
A **37 y/o M** with PMH including poorly controlled DM (A1c 9.7), TBI, sacral decubitus ulcer p/w **DKA & hypoxia**

- **Influenza A positive** on admission
- Respiratory status improved a little, but then worsened

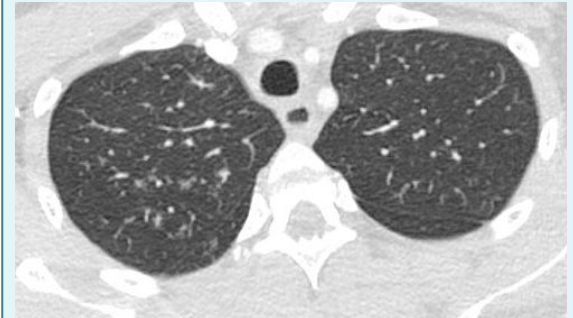
Case 5: HPI

A **37 y/o M** with PMH including poorly controlled DM (A1c 9.7), TBI, sacral decubitus ulcer p/w **DKA & hypoxia**

- **Influenza A positive** on admission
- Respiratory status improved a little, but then worsened



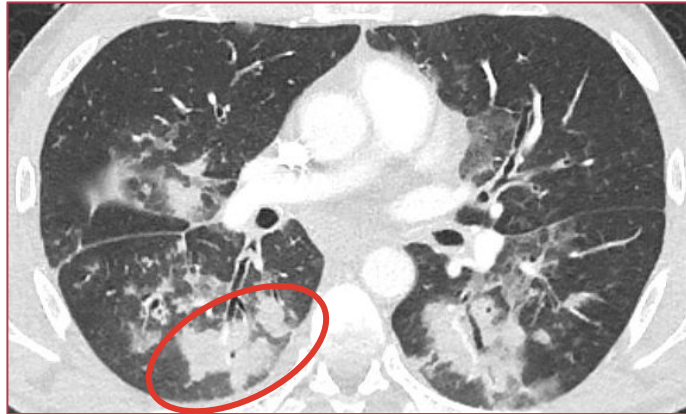
A week ago (admission)



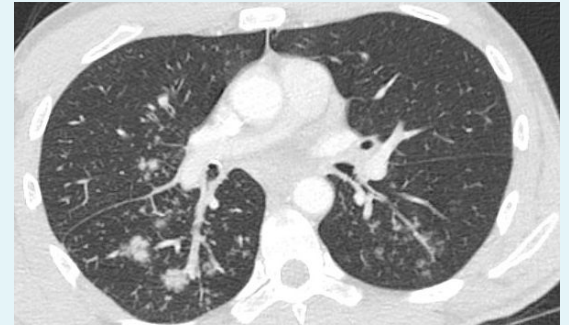Case 5: HPI

A **37 y/o M** with PMH including poorly controlled DM (A1c 9.7), TBI, sacral decubitus ulcer p/w **DKA & hypoxia**

- **Influenza A positive** on admission
- Respiratory status improved a little, but then worsened



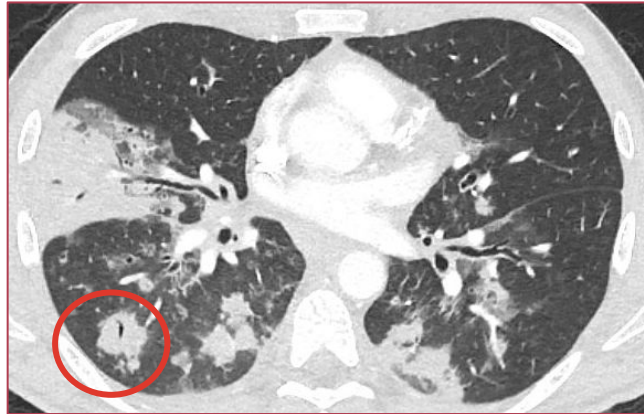
A week ago (admission)



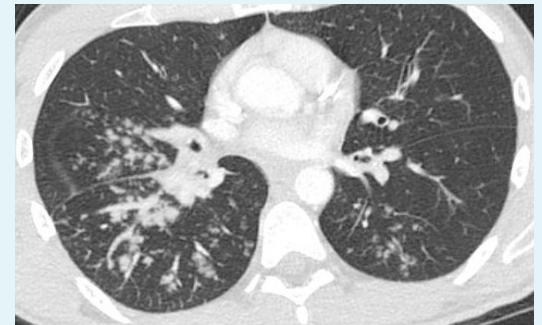
Case 5: HPI

A **37 y/o M** with PMH including poorly controlled DM (A1c 9.7), TBI, sacral decubitus ulcer p/w **DKA & hypoxia**

- **Influenza A positive** on admission
- Respiratory status improved a little, but then worsened



A week ago (admission)



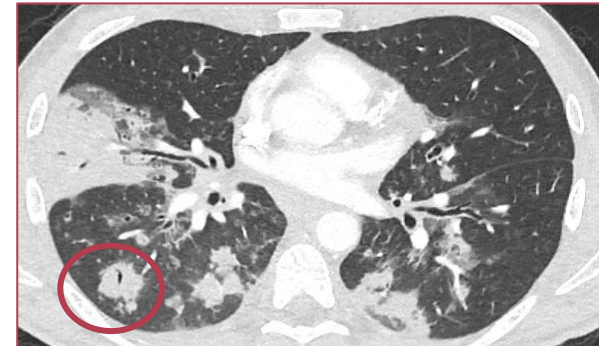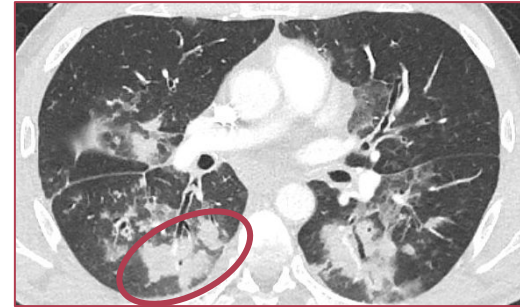
Case 5: HPI

A **37 y/o M** with PMH including poorly controlled DM (A1c 9.7), TBI, sacral decubitus ulcer p/w **DKA & hypoxia**

- **Influenza A positive** on admission
- Respiratory status improved a little, but then worsened

DDx?

(No MentiMeter for this one)

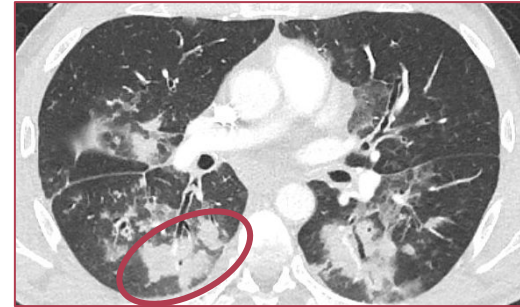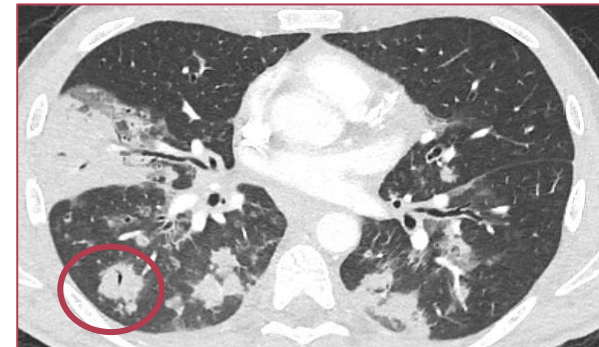


Case 5: HPI

A **37 y/o M** with PMH including poorly controlled DM (A1c 9.7), TBI, sacral decubitus ulcer p/w **DKA & hypoxia**

- **Influenza A positive** on admission
- Respiratory status improved a little, but then worsened

- Initial BCx: **MRSA** (1 of 2 sets)

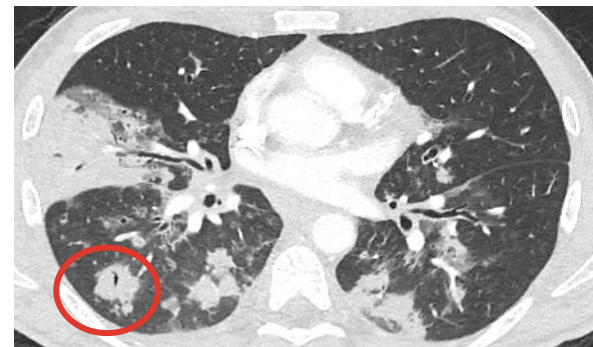
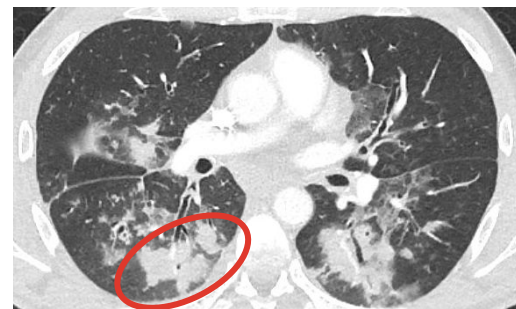


Case 5: HPI

A **37 y/o M** with PMH including poorly controlled DM (A1c 9.7), TBI, sacral decubitus ulcer p/w **DKA & hypoxia**

- **Influenza A positive** on admission
- Respiratory status improved a little, but then worsened

- Initial BCx: **MRSA** (1 of 2 sets)
- TTE: No valvular pathology
- Couldn't produce sputum

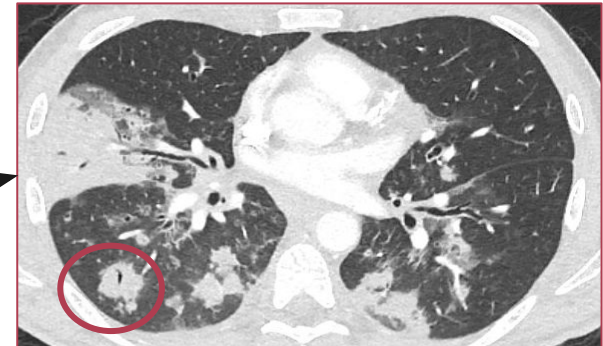
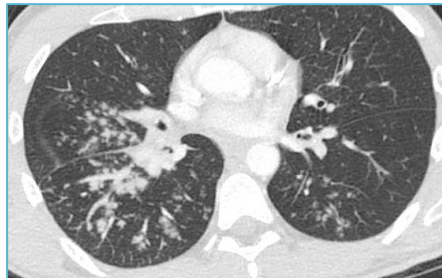
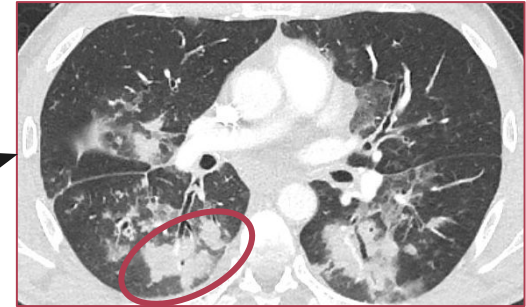
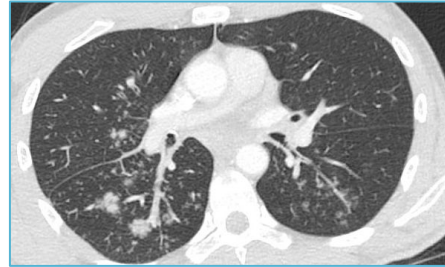
Case 5: Staph aureus *

Risk factors / clues

- Recent **influenza**
- Immunocompromise (DM)
- **Necrotizing pneumonia**

* Presumed to be from *Staph aureus*, since he improved on Zyvox (but took his time to get better)



Case #6

Case 6: HPI



A **30 y/o F** with PMH including tobacco use p/w **worsening cough**

Case 6: HPI

A **30 y/o F** with PMH including tobacco use p/w **worsening cough**

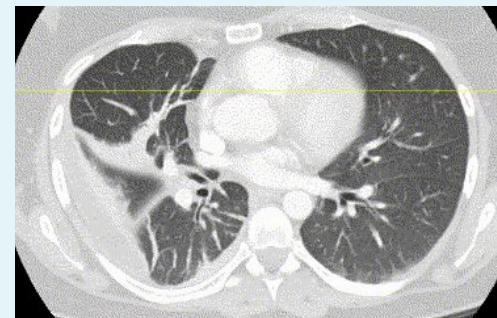
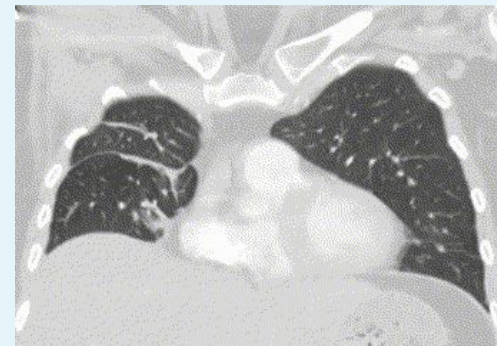
- Chronic, nonproductive cough for past year
 - Worsened in **past two months**
 - Now some **dyspnea, chronic leukocytosis**

Case 6: HPI

A **30 y/o F** with PMH including tobacco use p/w **worsening cough**

- Chronic, nonproductive cough for past year
 - Worsened in **past two months**
 - Now some dyspnea, chronic leukocytosis
- Two months ago, CT in ED showed **right pleural effusion**
 - Symptoms not improved with **doxycycline & cefpodoxime**

Two months ago

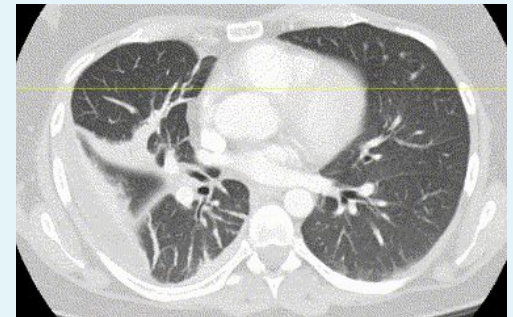
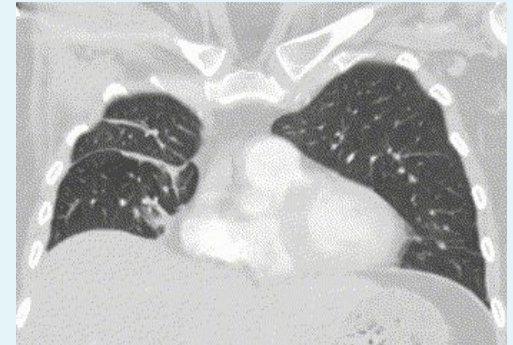


Case 6: HPI

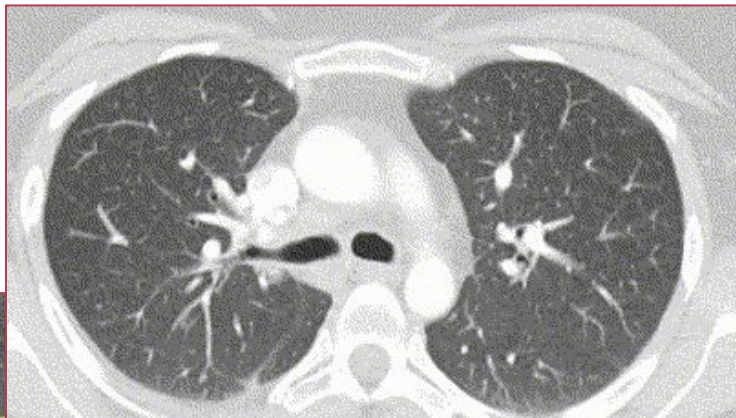
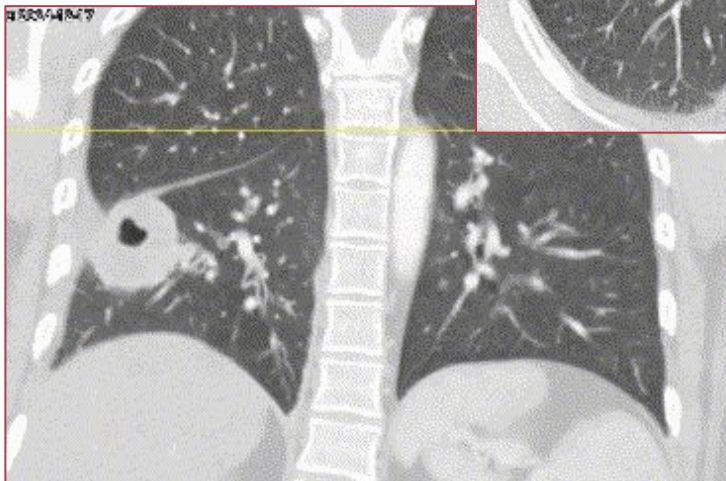
A **30 y/o F** with PMH including tobacco use p/w **worsening cough**

- Chronic, nonproductive cough for past year
 - Worsened in **past two months**
 - Now some dyspnea, chronic leukocytosis
- Two months ago, CT in ED showed **right pleural effusion**
 - Symptoms not improved with **doxycycline & cefpodoxime**
- No overt fevers, but **chills & anorexia** for **past month**
- Had seen CT surgery a month ago, who ordered repeat CT
 - Repeat CT prompted this admission

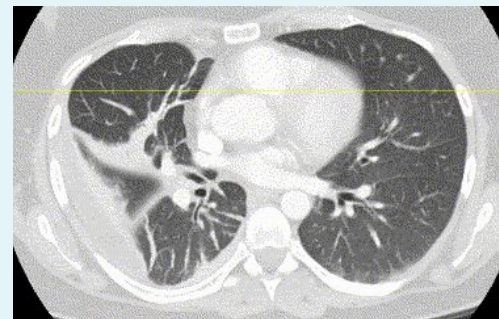
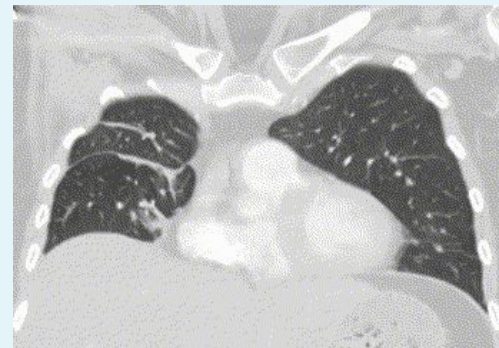
Two months ago



Case 6: Imaging



Two months ago



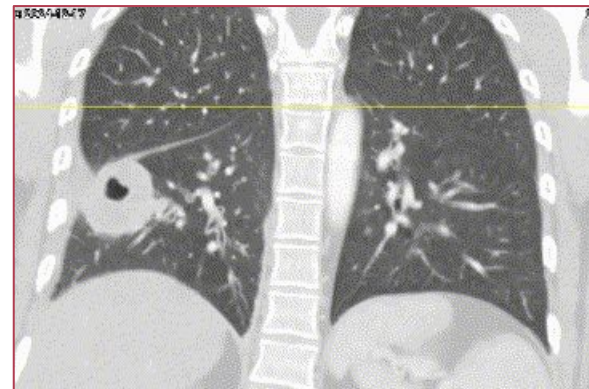
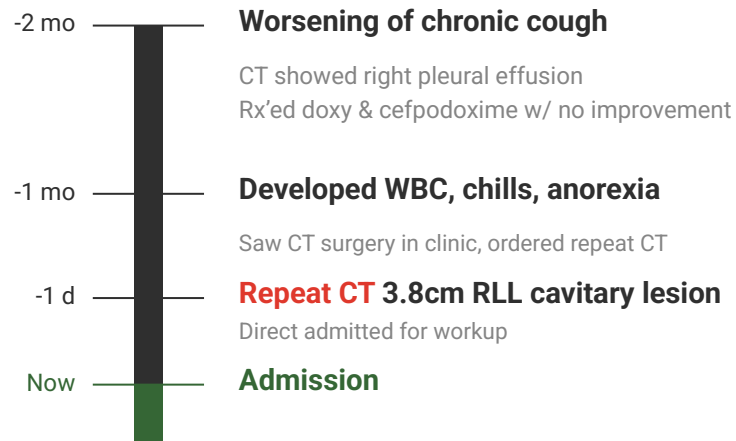
Case 6: Social & Exposure History

Geographic & Travel	<ul style="list-style-type: none">• Resides in in house a mile out of town (in the woods)• Lives with boyfriend and two kids• No recent foreign or domestic travel. Never international travel
Occupational	<ul style="list-style-type: none">• Not working, takes care of the kids (6 & 8 years old)
Substance & needles	<ul style="list-style-type: none">• Social use of EtOH• Smokes 1 ppd• Used to smoke weed (many years ago); never IVDU• Remote hx of unprofessional tattoos
Animals	<ul style="list-style-type: none">• Cats, dogs, snakes at home• No frequent bird exposures, but has cared for her parents chickens in the past
Exposures & hobbies	<ul style="list-style-type: none">• No known TB risk factors, including incarceration, homelessness, healthcare exposures, known contacts with TB, international travel• In the past year, she has gone in caves (unclear if there were bats)

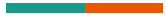Case 6: Summary

A **30 y/o F** with PMH including tobacco use p/w **worsening cough** x2 months after **right pleural effusion** that was unimproved with doxy & cefpodoxime.


- **Systemic symptoms** x1 month
- CT chest now with 3.8cm RLL cavitory lesion
- Smoker, birds, caves



[Q6.1] DDx



free response, vote



Mentimeter

We will vote on these

[6.1] What is the differential diagnosis?

Fungal

5

Popular

lung abcess

4

Histo

3

TB

1

[Q6.2] Additional work up?



Word cloud



[6.2] What additional workup do you want?

urine histo serum cr ag
crypto antigen **bal** histo ag
afb smear bal cultures ct aspirate
histo urinary ag urine histo blasto

Case 6: D Dx?

Serum / Urine	Result
Histo Ag	
Blasto Ag	
Crypto Ag	
Fungitell	---
Asp GM	
Legionella Ag	---
Strep pneumo Ag	
QuantGOLD	---

BAL	Result
Asp GM	
Asp PCR	
MTB PCR	---
PJP PCR	
Legionella DNA	---

Micro	Result
Blood	
BAL (routine)	
BAL (AFB)	
BAL (fungal)	

Case 6: DDX?

Serum / Urine	Result
Histo Ag	Neg
Blasto Ag	Neg
Crypto Ag	Neg
Fungitell	---
Asp GM	Neg
Legionella Ag	---
Strep pneumo Ag	Neg
QuantGOLD	---

BAL	Result
Asp GM	Neg
Asp PCR	Neg
MTB PCR	---
PJP PCR	Neg
Legionella DNA	---

Micro	Result
Blood	
BAL (routine)	
BAL (AFB)	
BAL (fungal)	

Additional HPI

Extensive **dental work**
six months ago

Case 6: DDx?

Serum / Urine	Result
Histo Ag	Neg
Blasto Ag	Neg
Crypto Ag	Neg
Fungitell	---
Asp GM	Neg
Legionella Ag	---
Strep pneumo Ag	Neg
QuantGOLD	---

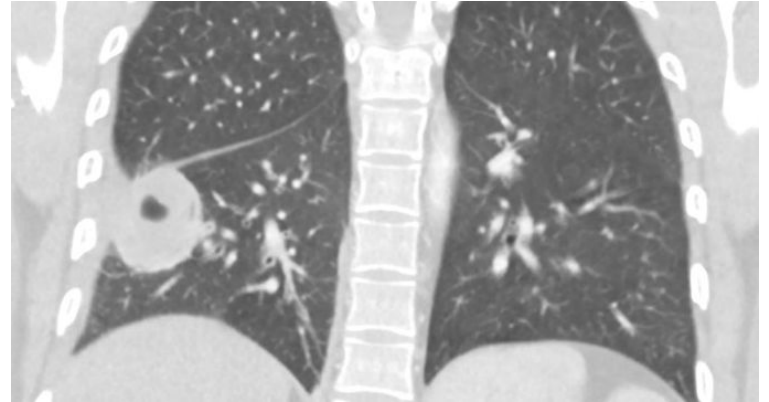
BAL	Result
Asp GM	Neg
Asp PCR	Neg
MTB PCR	---
PJP PCR	Neg
Legionella DNA	---

Micro	Result
Blood	NG
BAL (routine)	4+ Strep anginosus
BAL (AFB)	NG
BAL (fungal)	NG

Case 6: Strep anginosus

Hospital course

- TTE normal
- Rx: **ceftriaxone & flagyl (4 weeks)**
- Repeat CT outpatient



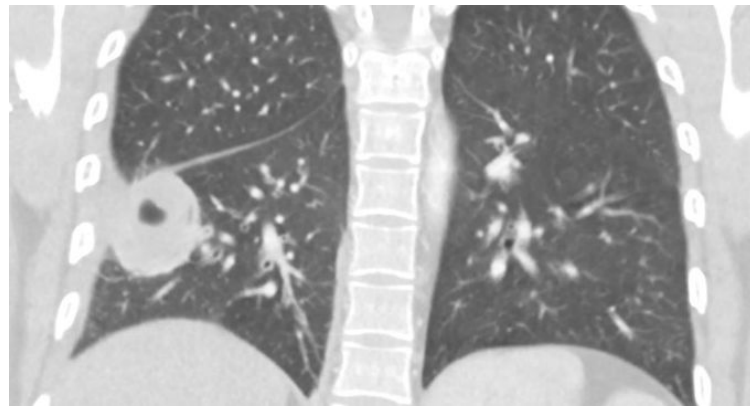
Case 6: Strep anginosus

Hospital course

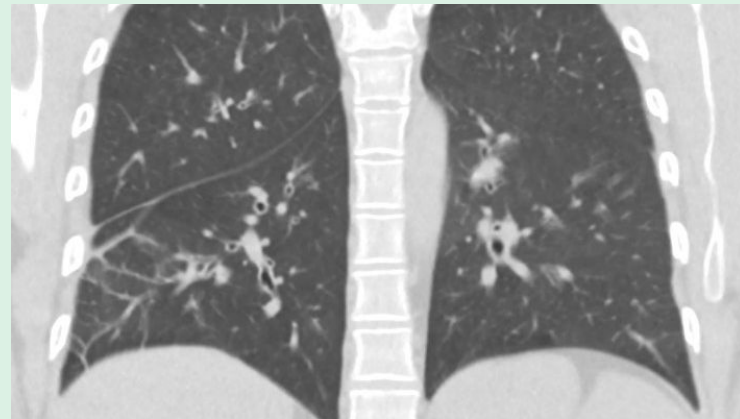
- TTE normal
- Rx: **ceftriaxone & flagyl (4 weeks)**
- Repeat CT outpatient

Clinic

- Doing well after 4 weeks of OPAT
- Hadn't gotten repeat CT, so extended duration by **2 weeks** with **cefpodoxime & flagyl**
- CT (at 7 weeks) **near complete resolution**



After treatment



Discussion



Links to articles discussed
here



Legionella & Hyponatremia

Learning objectives

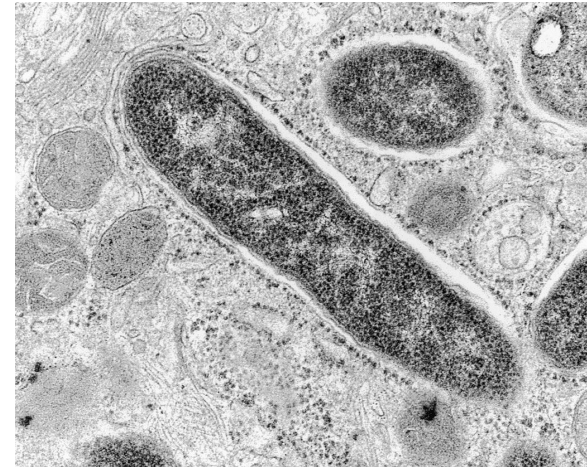


- Recognize the spectrum of **clinical manifestations** seen in Legionella infections
- Discuss the various **testing modalities** used to diagnose Legionella
- Compare the **common treatments** used in Legionnaires' disease, including duration of treatment
- Appraise the literature regarding **hyponatremia in Legionella** (& critique what I learned in medical school)

Legionnaires' disease [1]

Bacterial pneumonia caused by Legionella

- Intracellular small gram-negative bacilli
 - Fun fact: *Coxiella burnetii* (Q fever) is closest living relative to Legionella
- Classically associated with pulse temperature dissociation, pulmonary symptoms, hyponatremia, elevated LFTs [5]
 - More on this later
- Often associated with altered mental status, with a normal neurologic exam



Legionella cavitation? [9]

Cavitary disease is quite **rare**, but has been described (2009 review of 79 cases) [9]

- 90% are **immunosuppressed** at baseline (35% SOT)
 - 70% were on **steroids** at time of diagnosis
- **One in four** died

Solid organ transplantation	22	35.5%
Hematological malignancy	7	11.3% *
Collagen vascular diseases	6	9.7%
Neoplasms	6	9.7%
HIV infection	3	4.8% *
Alcoholism	1	1.6% **
COPD	3	4.8% **
Others	10	16.1%
No known underlying diseases	6	9.7%
Outcome		
survived	45	72.6%
dead	17	27.4%

*: B lymphoma in HIV infection

** : co-morbidity of COPD and alcoholism

Legionella cavitation? [9]

Cavitary disease is quite **rare**, but has been described (2009 review of 79 cases) [9]

- 90% are **immunosuppressed** at baseline (35% SOT)
 - 70% were on **steroids** at time of diagnosis
- **One in four** died

Unclear if they looked at co-infections
(more on this later)

Solid organ transplantation	22	35.5%
Hematological malignancy	7	11.3% *
Collagen vascular diseases	6	9.7%
Neoplasms	6	9.7%
HIV infection	3	4.8% *
Alcoholism	1	1.6% **
COPD	3	4.8% **
Others	10	16.1%
No known underlying diseases	6	9.7%

Outcome	survived	45	72.6%
	dead	17	27.4%

*: B lymphoma in HIV infection

** : co-morbidity of COPD and alcoholism

Legionella: Testing

Urine antigen

- Urine antigen is ideal test (in terms of sensitivity & specificity)
 - Only for serogroup 1
- Antigenuria may persist for weeks, even after pneumonia has resolved

DFA

- Less sensitive, and prone to false positives if lab is inexperienced
- Can be done of fixed lung tissue

Test / Specimen	Sensitivity	Specificity
Culture	20 - 95%	100%
Urine antigen	60 - 95%	>99%
Immunofluorescence microscopy	20 - 50%	99%
PCR (sputum, urine)	70 - 95%	95 - 99%

Optimal approach

Some authors [1] suggest more than one test (e.g. urine antigen + PCR) to increase yield

Legionella: Treatment

- Generally, fluoroquinolones (FQ) are about as effective as macrolides
- Little head-to-head comparisons of FQ vs azithromycin
- Retrospective study of critically ill patients found reduced mortality for levoflox vs non-azithro macrolides [2]
- Propensity matched analyses showed similar outcomes between levofloxacin & azithro [3][4]



Legionella: Treatment [1]

- Duration is normally similar to that of other forms of CAP
 - Similar principles apply for lung abscesses (may need prolonged extension)
 - Relapse has been described in immunocompromise
- No benefit to combo therapy, even in severe disease / immunosuppression [2]



Legionella: Treatment [1]

- Up to **10%** of patients with Legionella may have **co-infections with other pathogens**
 - Includes typical respiratory bacteria (H flu, pneumococcus), staph aureus
 - Also PJP, **nocardia**, aspergillus, tuberculosis, cryptococcus
 - More common in immunosuppression & severe disease

Legionella: Treatment [1]

- Up to **10%** of patients with Legionella may have **co-infections with other pathogens**
 - Includes typical respiratory bacteria (H flu, pneumococcus), staph aureus
 - Also PJP, nocardia, aspergillus, tuberculosis, cryptococcus
 - More common in immunosuppression & severe disease
- Generally, patients respond well to therapy
 - Within **hours to days**
 - Radiographic findings may lag

Legionella: Treatment [1]

- Up to **10%** of patients with Legionella may have **co-infections with other pathogens**
 - Includes typical respiratory bacteria (H flu, pneumococcus), staph aureus
 - Also PJP, nocardia, aspergillus, tuberculosis, cryptococcus
 - More common in immunosuppression & severe disease
- Generally, patients respond well to therapy
 - Within **hours to days**
 - Radiographic findings may lag
- Failure to respond to therapy should prompt **search for alternative causes**

Legionella & hyponatremia

Classically, legionella is associated with hyponatremia...

- I thought it might be interesting to look up why
- Then I remembered why I don't like sodium



Why the low sodium?

Multiple choice

Trick question: It dk

SIADH

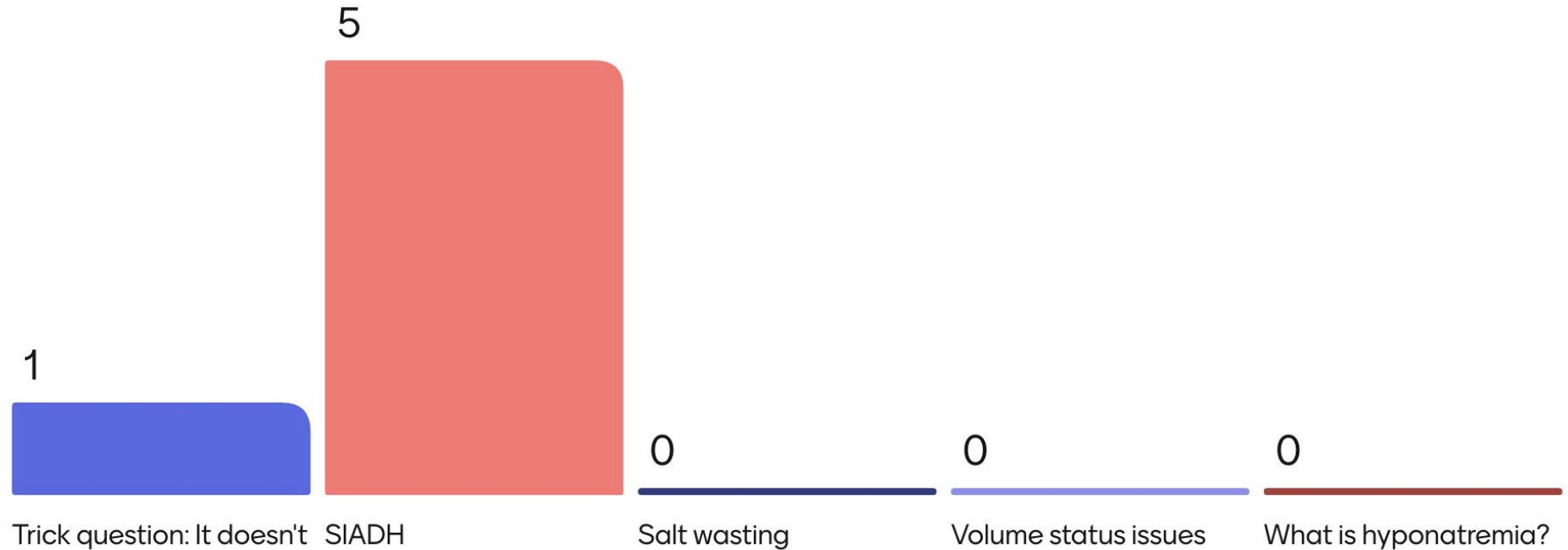
Salt wasting

Volume status issue

What is hyponatremia



Why does hyponatremia occur with Legionella?



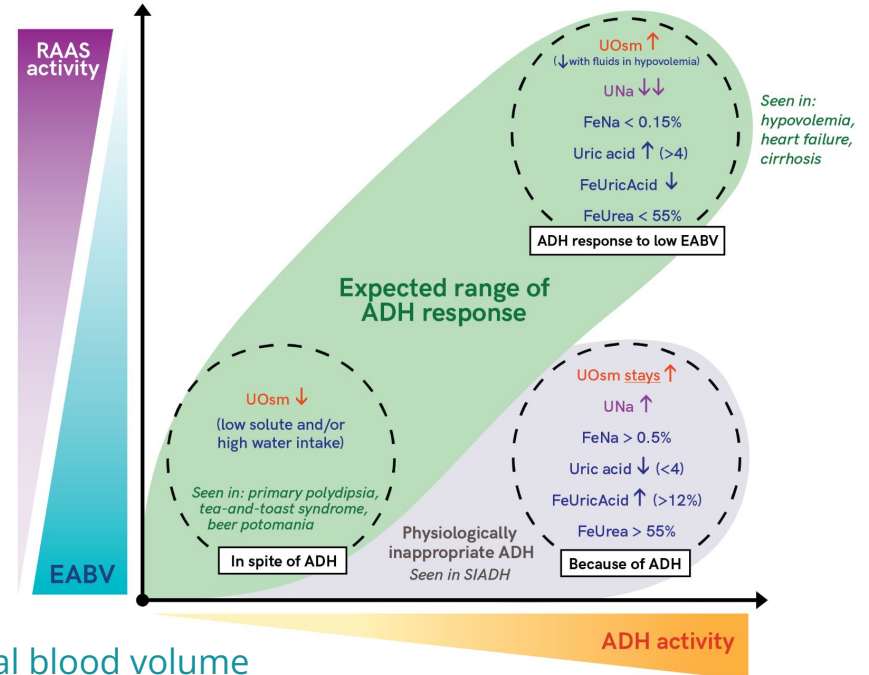
Quick refresher

- Hyponatremia is a problem with water retention, not salt *per se*
- ADH makes the kidneys hold on to water

CORE
IM

VISUALIZING HYPOTONIC HYPONATREMIA

UNa reveals RAAS activity. UOsm reveals ADH activity.
ADH secretion is appropriate only when RAAS is active.



EABV = Effective arterial blood volume

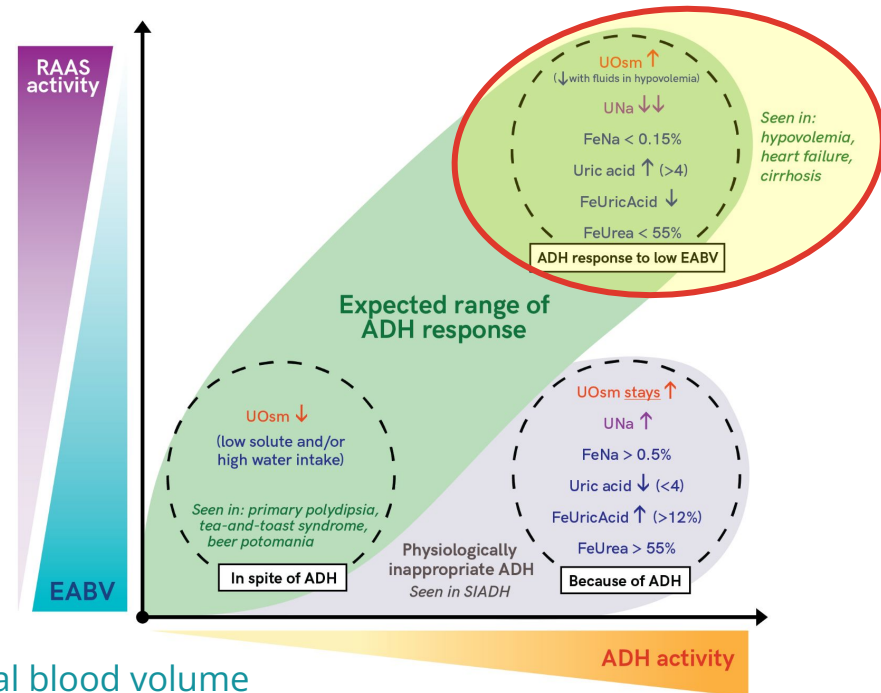
Quick refresher

- Hyponatremia is a problem with water retention, not salt *per se*
- ADH makes the kidneys hold on to water
- ↑↑ ADH makes sense when kidneys think there is low blood volume (**EABV**)
 - Includes states like CHF, cirrhosis

CORE
IM

VISUALIZING HYPOTONIC HYPONATREMIA

UNa reveals RAAS activity. UOsm reveals ADH activity.
ADH secretion is appropriate only when RAAS is active.



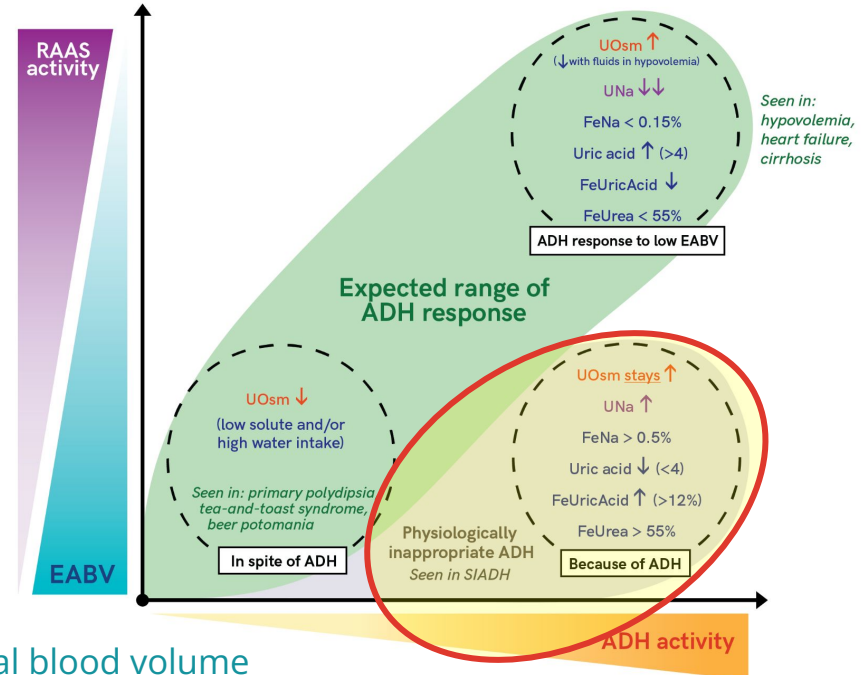
Quick refresher

- Hyponatremia is a problem with water retention, not salt *per se*
- ADH makes the kidneys hold on to water
- $\uparrow\uparrow$ ADH makes sense when kidneys think there is low blood volume (**EABV**)
 - Includes states like CHF, cirrhosis
- SIADH: $\uparrow\uparrow$ ADH disproportionate to \downarrow **EABV**

CORE
IM

VISUALIZING HYPOTONIC HYPONATREMIA

UNa reveals RAAS activity. UOsm reveals ADH activity.
ADH secretion is appropriate only when RAAS is active.



EABV = Effective arterial blood volume

Quick refresher

- Hyponatremia is a problem with **water retention**, not salt *per se*
- ADH makes the kidneys hold on to water
- $\uparrow\uparrow$ ADH makes sense when kidneys think there is low blood volume (**EABV**)
- SIADH: $\uparrow\uparrow$ ADH disproportionate to \downarrow **EABV**

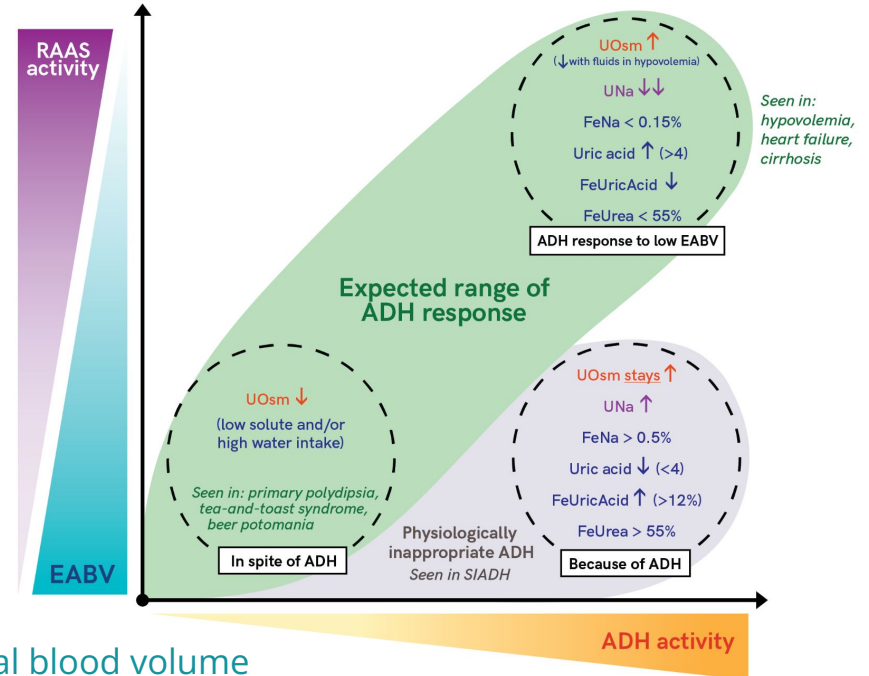
There is also **renal salt wasting** (formerly cerebral salt wasting), *too complicated* to discuss here

- Appears similar to SIADH but *better* with normal saline (not water restriction)

CORE
IM

VISUALIZING HYPOTONIC HYPONATREMIA

UNa reveals RAAS activity. UOsm reveals ADH activity.
ADH secretion is appropriate only when RAAS is active.



EABV = Effective arterial blood volume

Does Legionella cause hyponatremia?

- Pneumonia (of all types) have been associated with SIADH
- Legionella ***disproportionately*** causes hyponatremia

Does Legionella cause hyponatremia?

- Pneumonia (of all types) have been associated with SIADH
- Legionella *disproportionately* causes hyponatremia

Highlighted by a large, multicenter prospective study (**Schuetz et al**, 2013) [5]

- Post-hoc analysis of **873 patients** enrolled in a **pneumonia trial** looking at procalcitonin

Does Legionella cause hyponatremia?

- Pneumonia (of all types) have been associated with SIADH
- Legionella *disproportionately* causes hyponatremia

Highlighted by a large, multicenter prospective study (**Schuetz et al**, 2013) [5]

- Post-hoc analysis of **873 patients** enrolled in a **pneumonia trial** looking at procalcitonin

They compared:

Legionnaires' dz
(n=27)

vs

Other form of CAP
(n=846)

Does Legionella cause hyponatremia?

- Pneumonia (of all types) have been associated with SIADH
- Legionella *disproportionately* causes hyponatremia

Highlighted by a large, multicenter prospective study (**Schuetz et al**, 2013) [5]

- Post-hoc analysis of **873 patients** enrolled in a **pneumonia trial** looking at procalcitonin

They compared: Legionnaires' dz
(n=27) vs Other form of CAP
(n=846)

- Used left over blood to measure **copeptin**, in addition to serum sodium levels (on admission)

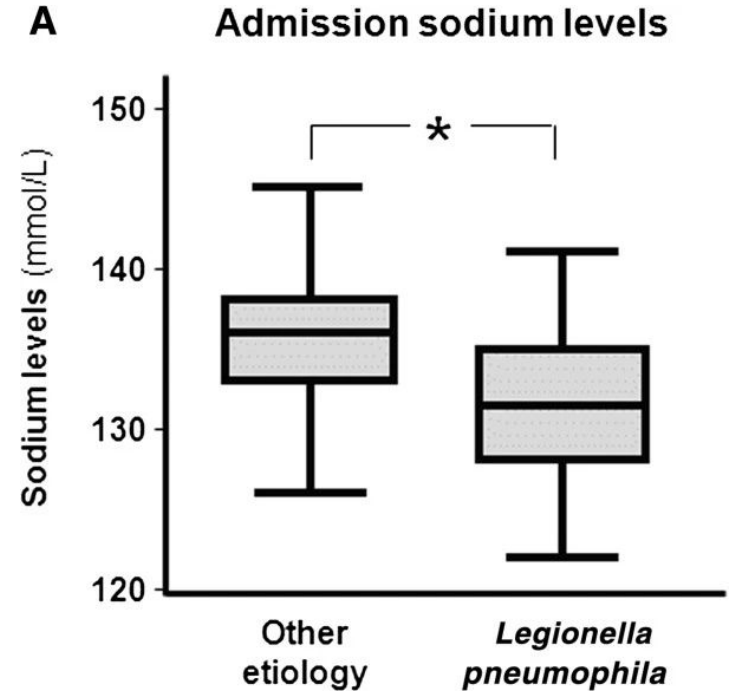
Copeptin / CT-ProVasopressin

C terminal provasopressin (referred to as **CT-ProVasopressin** in the article) is a stable laboratory surrogate of ADH levels

Schuetz et al (2013) [5]

Patients with **Legionnaires' disease**

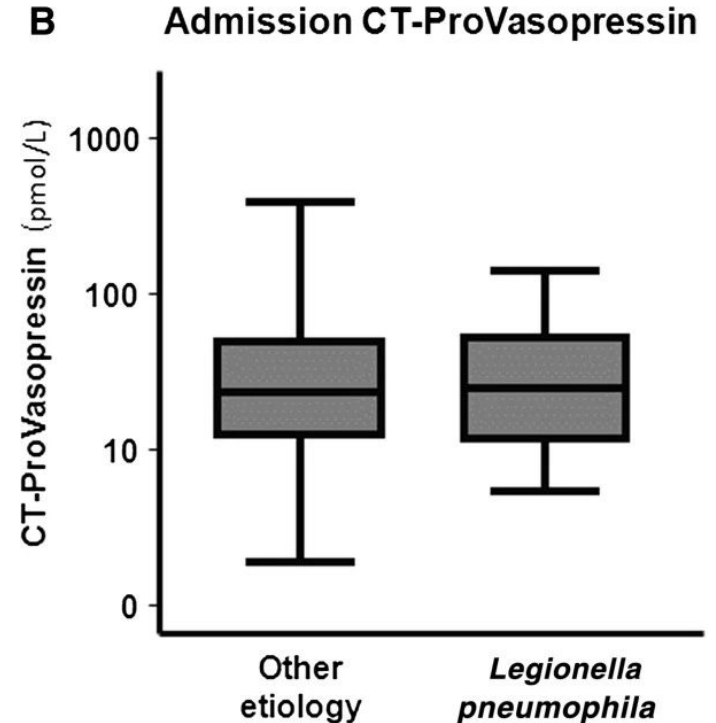
- More frequently had **low sodium levels**
 - Defined as $\text{Na} < 130$ (mmol/L)
 - 44.4% vs 8.2% ($p < 0.01$)



Schuetz et al (2013) [5]

Patients with Legionnaires' disease

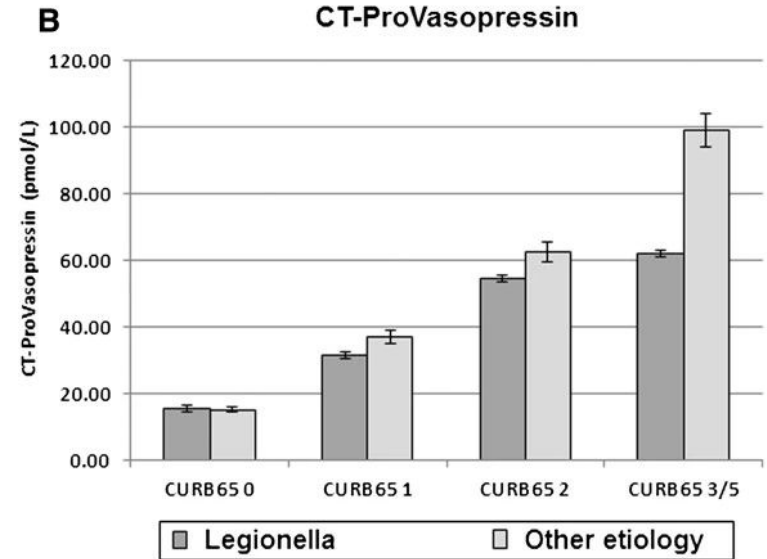
- More frequently had **low sodium levels**
 - 44.4% vs 8.2% ($p < 0.01$)
- Had **similar levels** of CT-ProVasopressin/copeptin
 - 39.4 ± 7 vs 51.2 ± 2.7 ($p = 0.43$)



Schuetz et al (2013) [5]

Patients with Legionnaires' disease

- More frequently had **low sodium levels**
 - 44.4% vs 8.2% ($p < 0.01$)
- Had **similar levels** of CT-ProVasopressin/**copeptin**
 - 39.4 ± 7 vs 51.2 ± 2.7 ($p = 0.43$)
- Interestingly, **copeptin** levels were associated with **increased severity of pneumonia**, just not with the etiology of the pneumonia



Schuetz et al (2013) [5]

Patients with **Legionnaires' disease**

- More frequently had **low sodium levels**
 - 44.4% vs 8.2% ($p < 0.01$)
- Had **similar levels** of CT-ProVasopressin/**copeptin**
 - 39.4 ± 7 vs 51.2 ± 2.7 ($p = 0.43$)
- Interestingly, **copeptin** levels were associated with **increased severity of pneumonia**, just not with the etiology of the pneumonia

Author's conclusions

Although legionella is associated with hyponatremia, there is **no evidence that ADH is driving this process.**

Rather, an **ADH-independent process** may be driving hyponatremia, such as **direct renal effects** of cytokines or toxins, as well as **natriuretic hormones**

Why it matters?

Volume management with sepsis & ARDS is challenging

- Fluid restricting when it's not ADH makes things worse

If not SIADH, then what *does* cause hyponatremia?

- Not a whole lot on the pathophysiology that I could find on PubMed
- A few interesting case reports on **acquired Fanconi syndrome** in Legionella

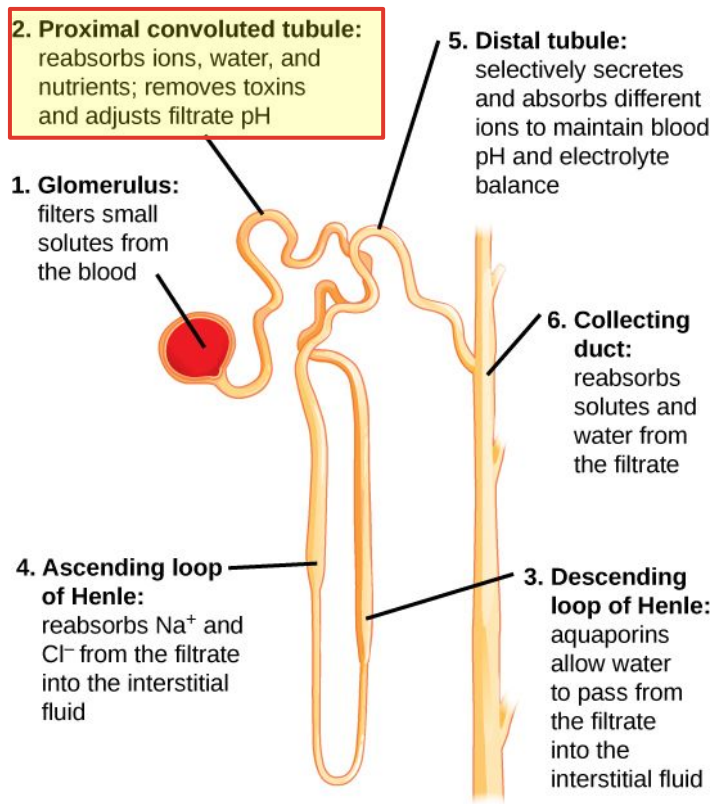
Author's conclusions

Although legionella is associated with hyponatremia, there is **no evidence that ADH is driving this process.**

Rather, an **ADH-independent process** may be driving hyponatremia, such as **direct renal effects** of cytokines or **toxins**, as well as **natriuretic hormones**

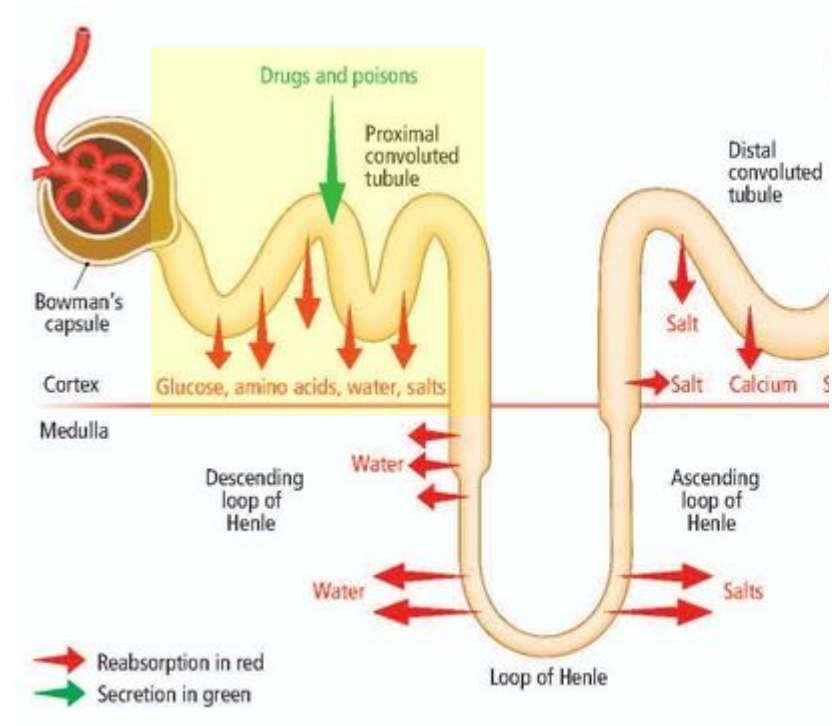
Fanconi syndrome (more nephrology)

- **Fanconi syndrome** is generalized dysfunction of the PCT
- Same syndrome that occurs with **aminoglycosides**, **tenofovir**, **tetracyclines**



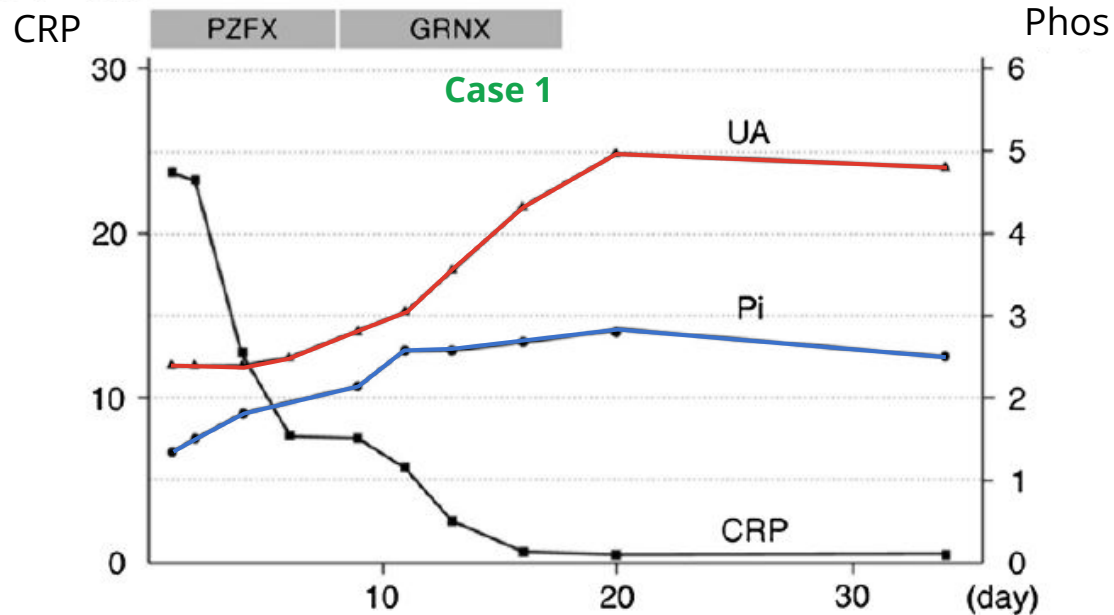
Fanconi syndrome (more nephrology)

- **Fanconi syndrome** is generalized dysfunction of the PCT
- PCT reabsorbs key nutrients, such as phosphate, glucose, and amino acids
- **Results in:**
 - Hypokalemia
 - **Hypophosphatemia**
 - **Hypouricemia**
 - Metabolic acidosis
- +/- hyponatremia (collecting duct can compensate, with use of ADH)



Kinoshita-Katahashi et al (2013) [6]

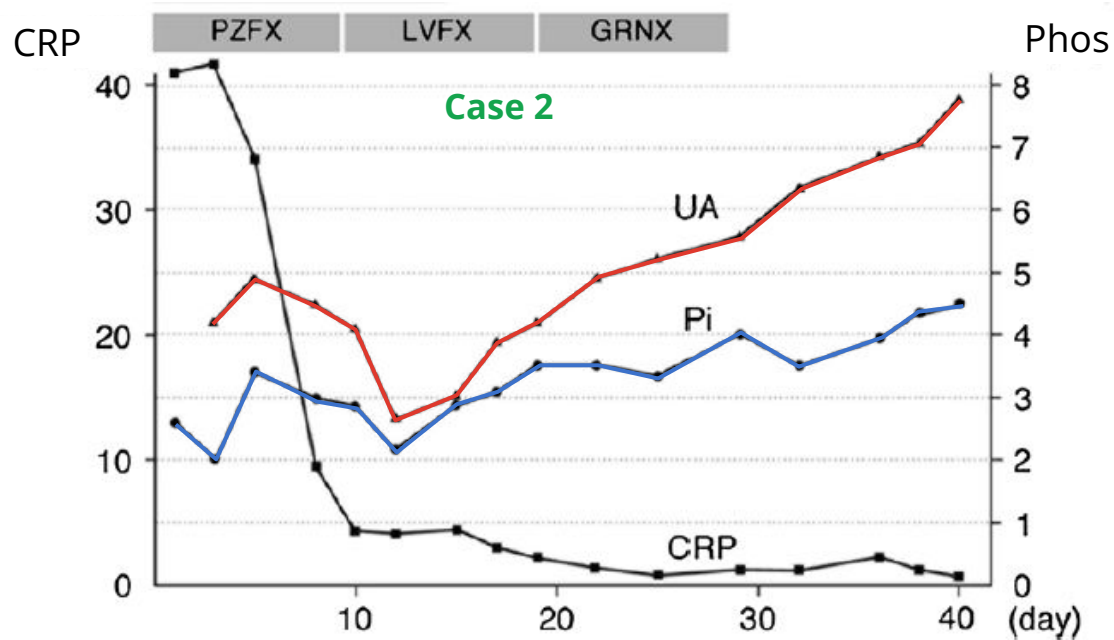
Case report of 2 cases of acquired Fanconi syndrome + Legionella out of Japan



Key
Serum **uric acid**
Serum **phosphate**

Kinoshita-Katahashi et al (2013) [6]

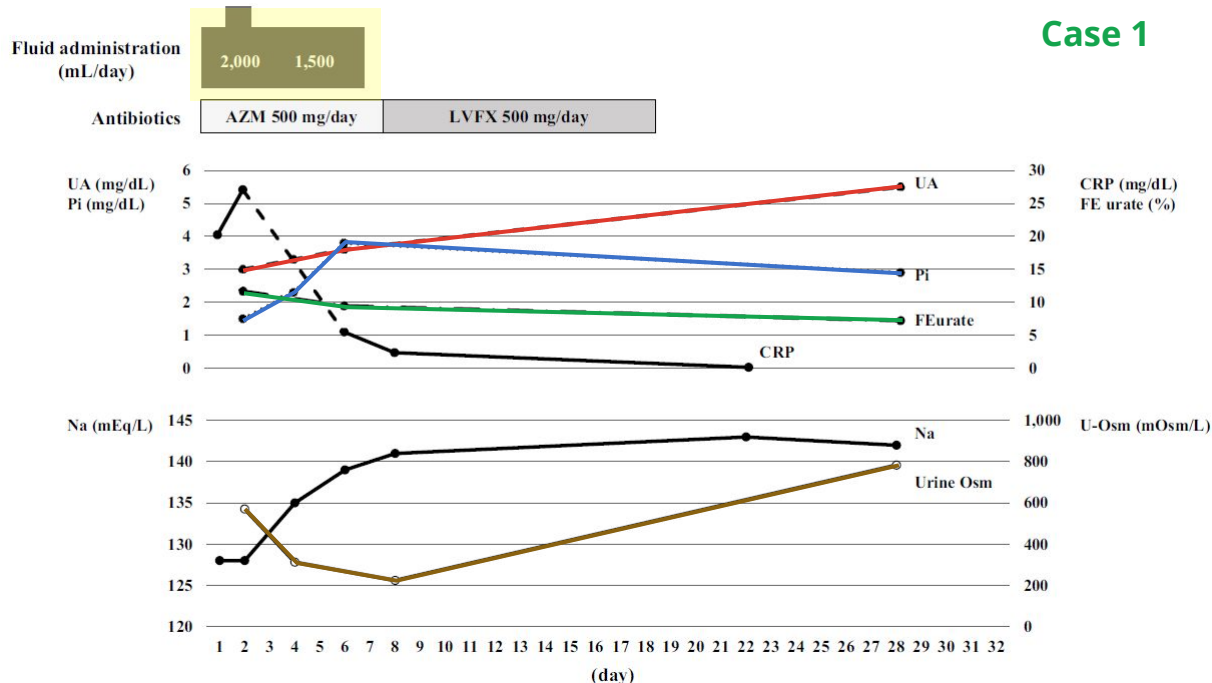
Case report of 2 cases of acquired Fanconi syndrome + Legionella out of Japan



Key
Serum **uric acid**
Serum **phosphate**

Ryuge et al (2016) [7]

Another 2 cases of acquired Fanconi syndrome + Legionella out of Japan

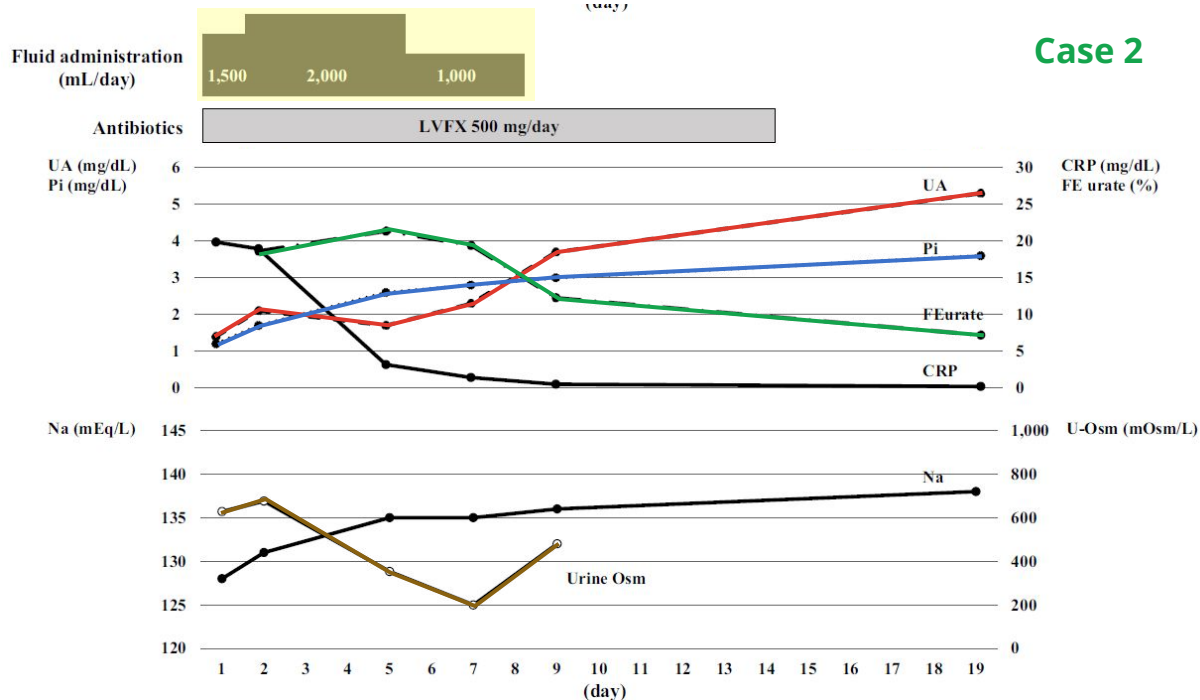


Key

- Serum **uric acid**
- Serum **phosphate**
- Urine **FE urea**
- Urine **Osm**

Ryuge et al (2016) [7]

Another 2 cases of acquired Fanconi syndrome + Legionella out of Japan



Key
Serum **uric acid**
Serum **phosphate**
Urine **FE urea**
Urine **Osm**

Speculation

An additional case report [8] discusses evidence of **Legionella involvement in the kidneys** themselves

- Specifically, an autopsy case report showed **positive immunofluorescence** in the renal **proximal tubules**

Schuetz et al (2013) [5]

Although legionella is associated with hyponatremia, there is **no evidence that ADH is driving this process.**

Rather, an **ADH-independent process** may be driving hyponatremia, such as **direct renal effects** of cytokines or **toxins**, as well as **natriuretic hormones**

Speculation

An additional case report [8] discusses evidence of **Legionella involvement in the kidneys** themselves

- Specifically, an autopsy case report showed **positive immunofluorescence** in the renal **proximal tubules**

Some authors [10] include **hypophosphatemia** as a diagnostic clue for Legionella

- This may imply that the kidneys (PCT specifically) are taking more of a hit than previously expected

Table Legionnaire's Disease: Six Clinical Predictors and Diagnostic Eliminators in Adults Admitted with Pneumonia*

Diagnostic Predictors	Diagnostic Eliminators
Clinical Predictors <ul style="list-style-type: none">• Fever (>102°F)	Clinical Eliminators <ul style="list-style-type: none">• Sore throat• Severe myalgias
Laboratory Predictors † <ul style="list-style-type: none">• Highly elevated ESR (>90 mm/h) or CRP (>180 mg/L)• Highly elevated ferritin levels (>2 × normal)• Hypophosphatemia (on admission/early)• Highly elevated CPK (>2 × normal)• Microscopic hematuria (on admission)	Laboratory Eliminators <ul style="list-style-type: none">• Leukopenia• Thrombocytopenia• Negative chest x-ray (no infiltrates)
Legionnaire's disease very likely if >3 predictors present	Legionnaire's disease very unlikely if <3 predictors or >3 diagnostic eliminators present

CPK = creatinine phosphokinase test; CRP = C-reactive protein; ESR = erythro sedimentation rate.

*Pulmonary symptoms: shortness of breath, cough, and so forth with fever and a new focal/segmental infiltrate on chest x-ray.

†Otherwise unexplained. If finding is due to an existing disorder, it should not be used as a clinical predictor.

Speculation

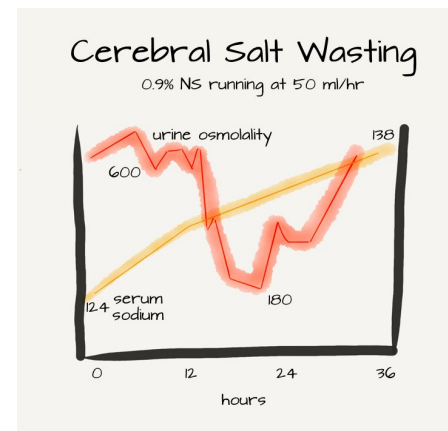
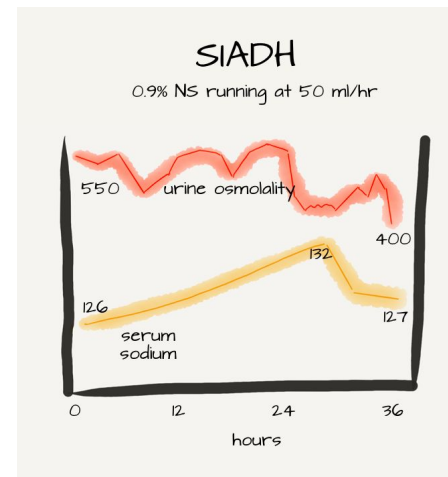
An additional case report [8] discusses evidence of **Legionella involvement in the kidneys** themselves

- Specifically, an autopsy case report showed **positive immunofluorescence** in the renal **proximal tubules**

Some authors [10] include **hypophosphatemia** as a diagnostic clue for Legionella

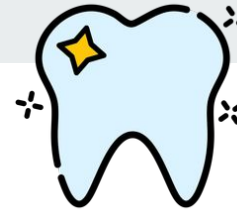- This may imply that the kidneys (PCT specifically) are taking more of a hit than previously expected

Renal salt wasting?

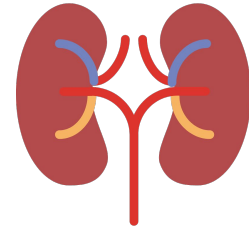


Learning points & take aways

Learning points & take aways



- When testing for legionella, combination testing (e.g. uAg + PCR) is best
- Legionella rarely causes cavitory disease (though can happen in immunocompromise)
- Up to 10% of patients with Legionella will have co-infections with other pathogens
 - May be typical respiratory bacteria (H flu, pneumococcus), staph aureus
 - But don't forget about PJP, **nocardia**, aspergillus, tuberculosis, cryptococcus
- Legionella can cause hyponatremia
 - Traditionally thought to be from SIADH
 - An analysis of trial data (Schuetz et al [5]) suggests it is *not* from SIADH
 - Possibly mediated by direct injury to the kidney?
- Prior talks
 - Nocardia: www.hunterrattliff1.com/talk/cid-2024-09/
 - Hyponatremia (for ABIM): www.hunterrattliff1.com/talk/acp_prep/



Slides available on hunterrattliff1.com/talk/; Citations available via QR code or via the “citations” button on the website