



Rash decisions

CLINID conference
Hunter Ratliff
07/10/2025

*Ages, dates, and other identifying information may have been changed
I have no conflict of interest in relation to this presentation*

Shortcuts



[Jump to discussion](#) about HSV antivirals and mechanisms of resistance

- Key unique long regions (UL) of HSV
- **Acyclovir**: mechanism | molecular mechanism
- TK deficient HSV: **Ganciclovir** | **Cidofovir** | **Foscarnet**
- Helicase-Primase Inhibitors: **Pritelivir** | **Amenamevir**
- **“natural” treatments**: oyster mushrooms | topical olive leaf extract

Takeaway slide

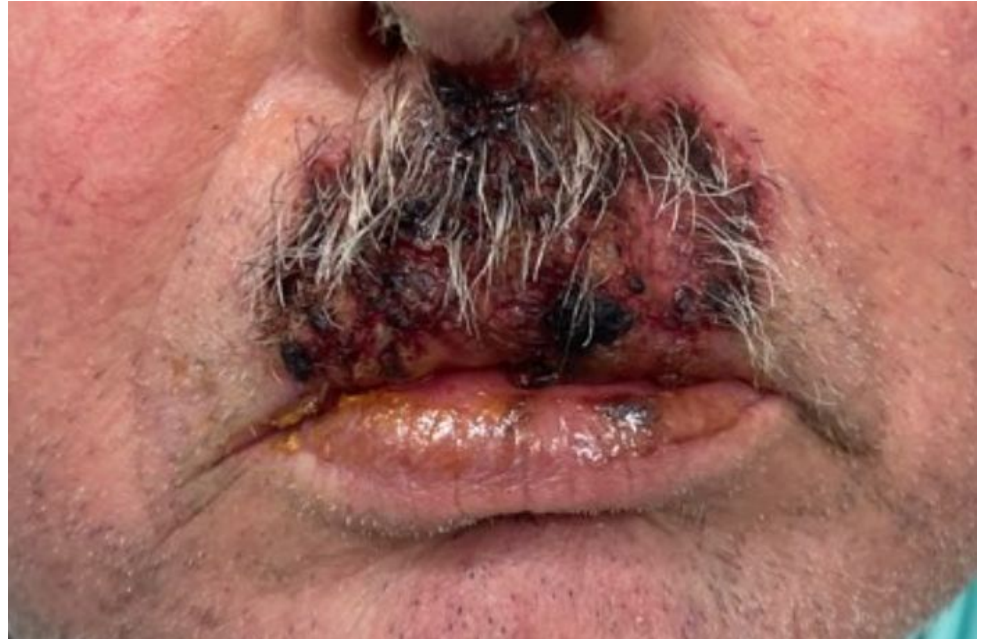HPI



A **71 y/o M** with PMH including T-cell PLL s/p alloSCT (-14 mo ago) c/b cutaneous GVHD (currently on pred & Jakafi) p/w **2 month history of...**

HPI

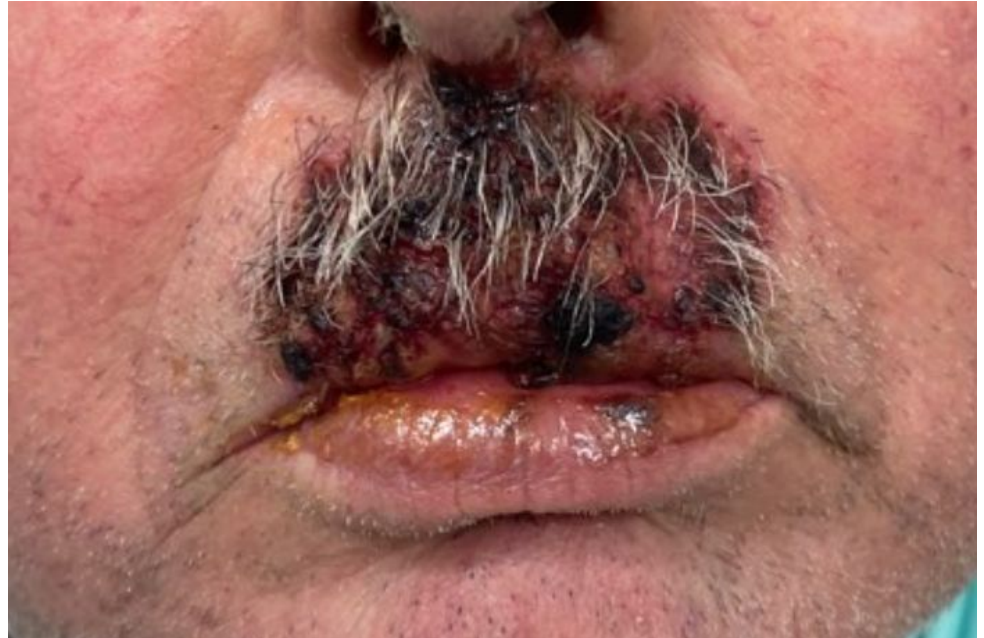A **71 y/o M** with PMH including T-cell PLL s/p alloSCT (-14 mo ago) c/b cutaneous GVHD (currently on pred & Jakafi) p/w **2 month history of...**



HPI at time of consult

A **71 y/o M** with PMH including T-cell PLL s/p alloSCT (-14 mo ago) c/b cutaneous GVHD (currently on pred & Jakafi) p/w **2 month history of...**

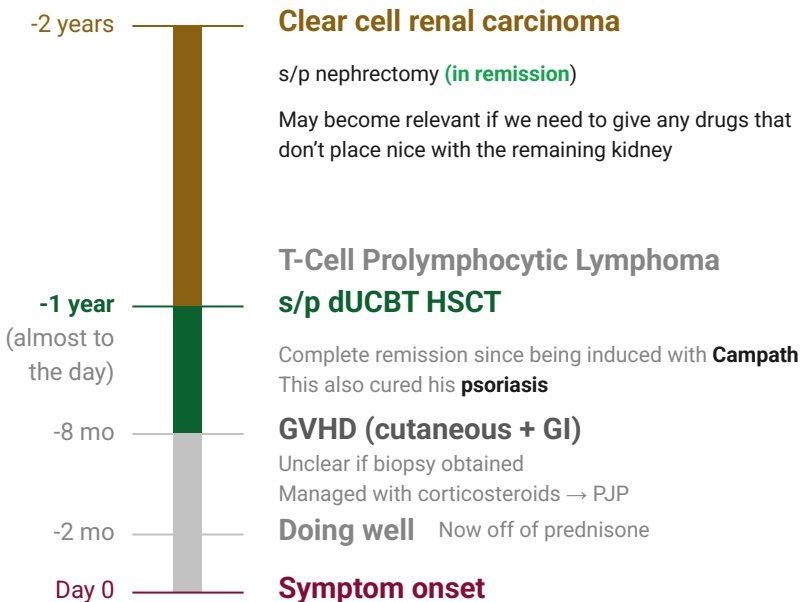
- Often, but not always painful
- Has not improved with PO meds (which is why we are seeing him!)
- No other painful spots elsewhere
 - Has had another rash...



The backstory

A **71 y/o M** with PMH including T-cell PLL s/p alloSCT (-1 yr ago), GVHD, Hx PJP, psoriasis, PMR, renal cancer s/p nephrectomy (-2 years)

Convention/notation for timing
Day "zero" = onset of symptoms
ID was consulted around day 65



Week 1



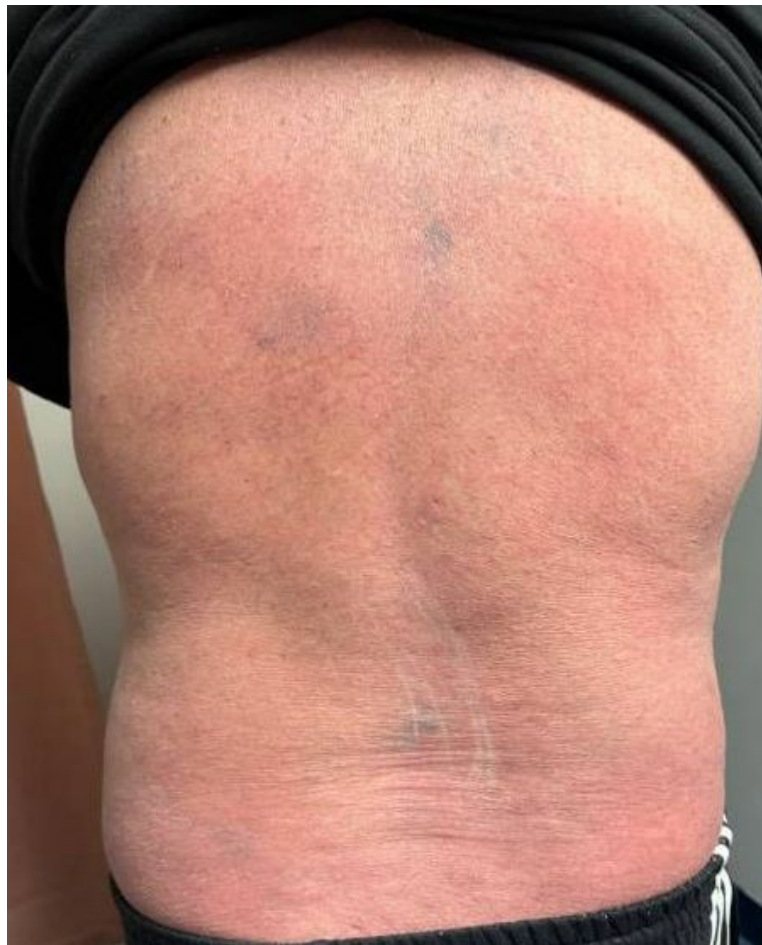PCP note says patient noted a **pruritic rash** “**everywhere**” for past **few months**. Has been applying **topical triamcinolone**.

Med list

- Budesonide 3mg TID
- Beclomethasone 2mg QID
- Acyclovir 400 BID
 - Topical acyclovir
- Isavuconazole 372 daily
- Letermovir 480 daily
- SMX/TMP SS qMWF

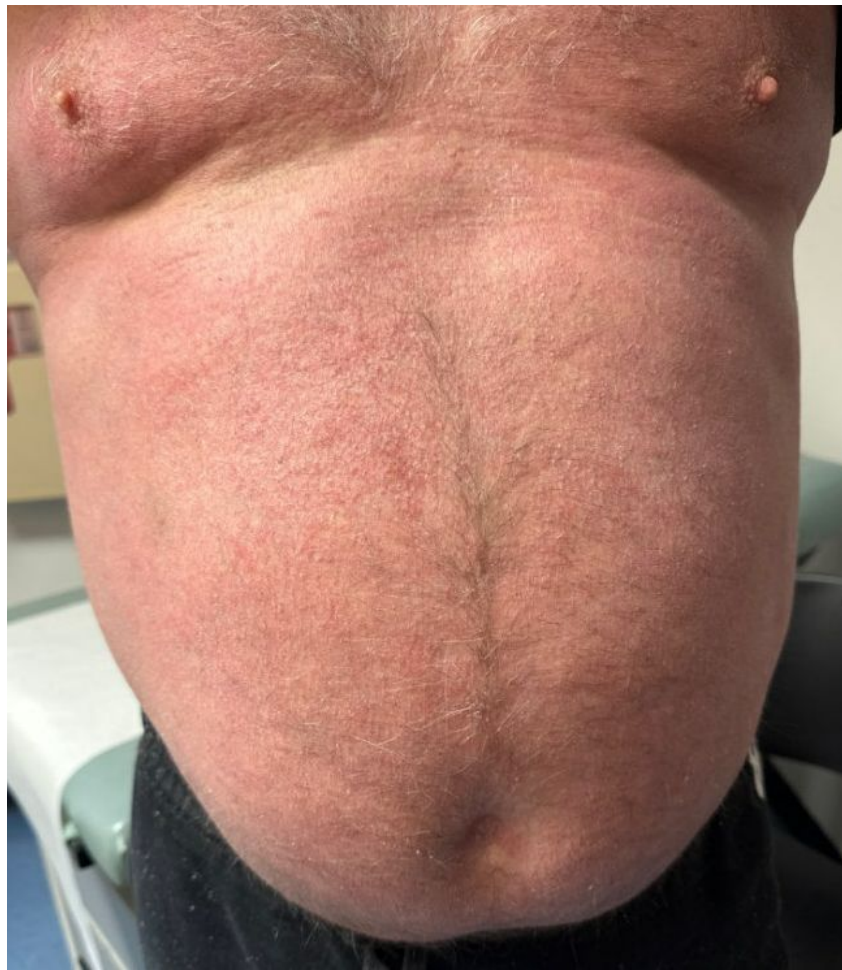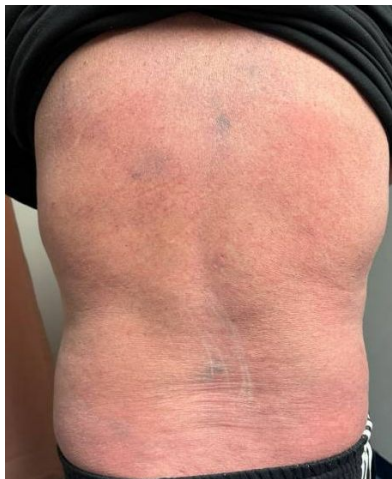Week 1

PCP note says patient noted a **pruritic rash** "everywhere" for past **few months**. Has been applying **topical triamcinolone**.



Week 1

PCP note says patient noted a **pruritic rash** "everywhere" for past **few months**. Has been applying **topical triamcinolone**.



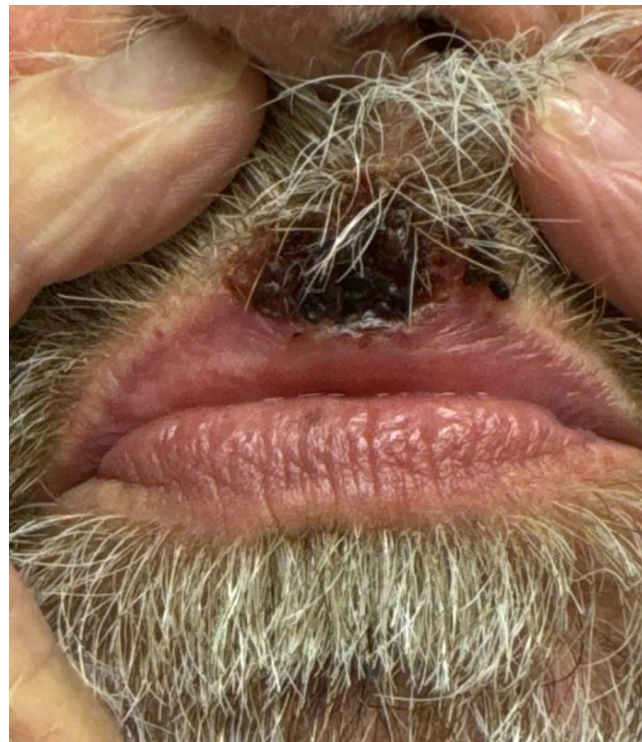Week 1

PCP note says patient noted a **pruritic rash** “everywhere” for past **few months**. Has been applying topical triamcinolone

Separately, has had a **cold sore** develop on the **upper lip** and has been applying **topical acyclovir**. Area is getting **larger** and **scabbed**

Med list

- Budesonide 3mg TID
- Acyclovir 400 BID
 - Topical acyclovir
- Isavuconazole 372 daily
- Letemovir 480 daily
- SMX/TMP SS qMWF

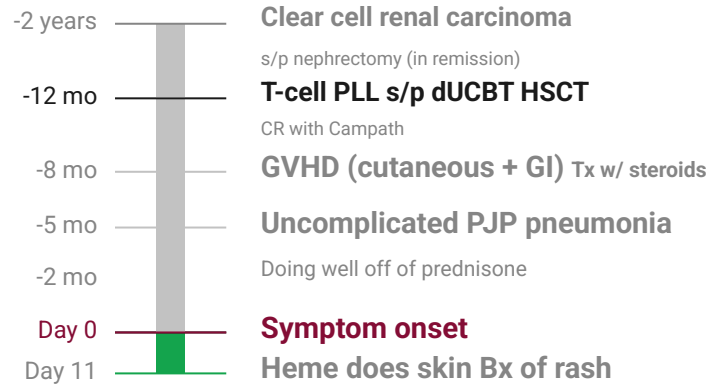


Week 2 (day 11)



Heme onc clinic: **Skin biopsy** of arm to evaluate for cGVHD

No medication changes made



Med list

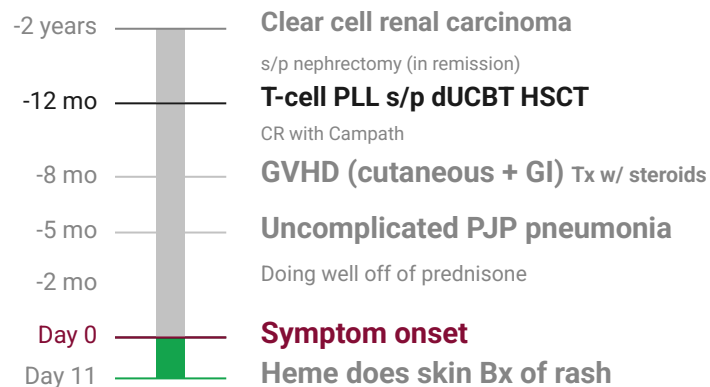
- Budesonide 3mg TID
- Acyclovir 400 BID
 - Topical acyclovir
- Isavuconazole 372 daily
- Letermovir 480 daily
- SMX/TMP SS qMWF

Week 2 (day 11)

Heme onc clinic: **Skin biopsy** of arm to evaluate for cGVHD

No medication changes made

Pathology report: Mild subacute spongiotic dermatitis with superficial lymphomononuclear cell infiltrates with occasional eosinophils



Med list

- Budesonide 3mg TID
- Acyclovir 400 BID
 - Topical acyclovir
- Isavuconazole 372 daily
- Letermovir 480 daily
- SMX/TMP SS qMWF

Week 2 (day 11)

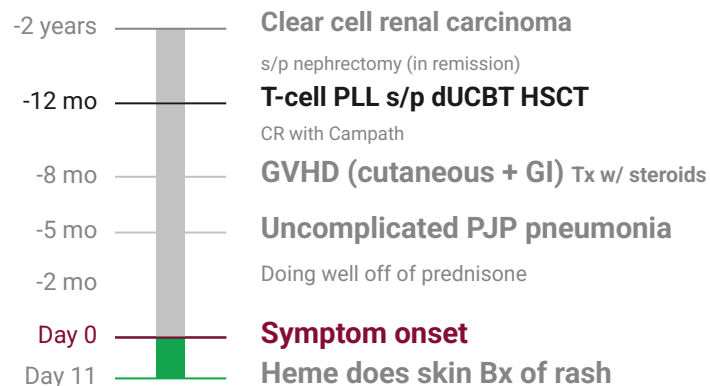
Heme onc clinic: **Skin biopsy** of arm to evaluate for cGVHD

No medication changes made

Pathology report: Mild **subacute spongiotic dermatitis** with **superficial lymphomononuclear cell infiltrates** with **occasional eosinophils**

The histologic profile shows irregular hyperkeratosis with serum protein exudates, irregular acanthosis, spongiosis, and superficial perivascular lymphocytic infiltrates with occasional eosinophils.

The **presence of occasional eosinophils** may indicate an **underlying hypersensitivity mechanism** and a **spongiotic drug eruption** may be considered. At least objectively certain viral exanthems, urticarial reaction patterns, or other unknown systemic allergen.



Med list

- Budesonide 3mg TID
- Acyclovir 400 BID
 - Topical acyclovir
- Isavuconazole 372 daily
- Letermovir 480 daily
- SMX/TMP SS qMWF

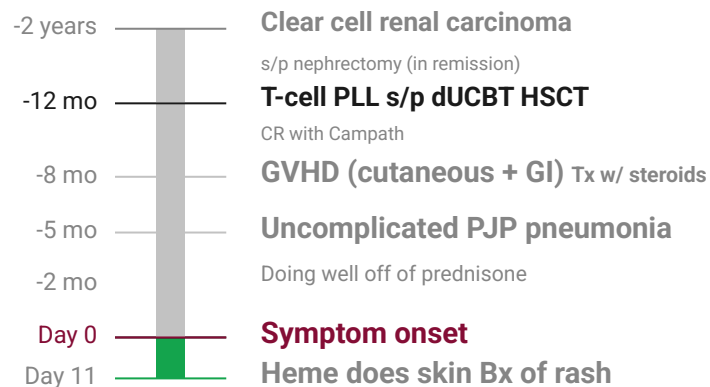
Week 2 (day 11)

Heme onc clinic: **Skin biopsy** of arm to evaluate for cGVHD

No medication changes made

Pathology report: Mild **subacute spongiotic dermatitis** with **superficial lymphomononuclear cell infiltrates** with **occasional eosinophils**

The **lymphomononuclear cell infiltrate is particularly sparse** raising **significant doubt** for the possibility of **leukemia cutis**. Migration of lymphocytes into the epidermis is focal and minimal likely to be a feature of lymphocytic spongiosis rather than epidermotropism in the setting of erythrodermic mycosis fungoides at least objectively. However, this disease may initiate within the setting of a spongiotic or eczematous process. Additional biopsies may be needed in the future

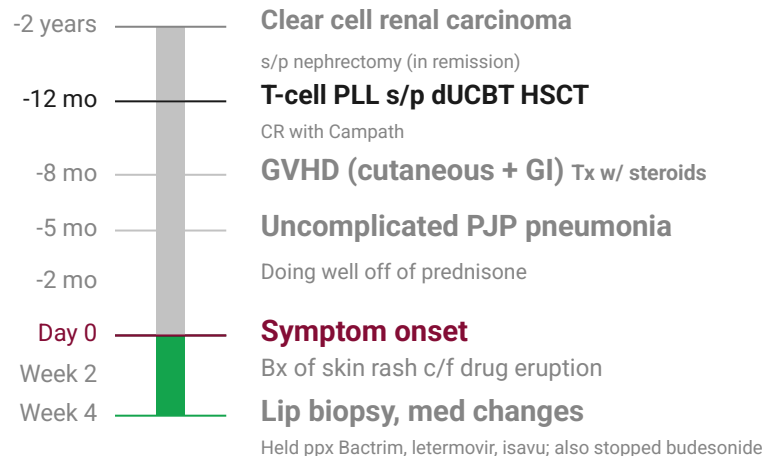


Med list

- Budesonide 3mg TID
- Acyclovir 400 BID
 - Topical acyclovir
- Isavuconazole 372 daily
- Letermovir 480 daily
- SMX/TMP SS qMWF

Week 4 (day 25)

Heme onc clinic: Worried about **drug eruption** causing skin rash → **discontinued many of his meds**



Med list

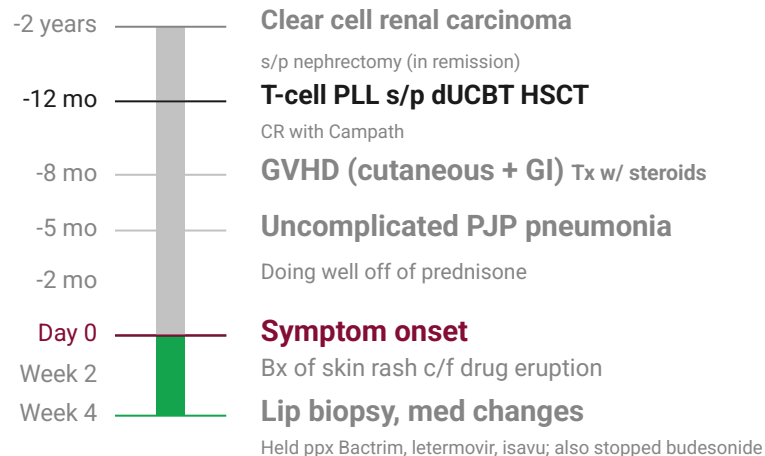
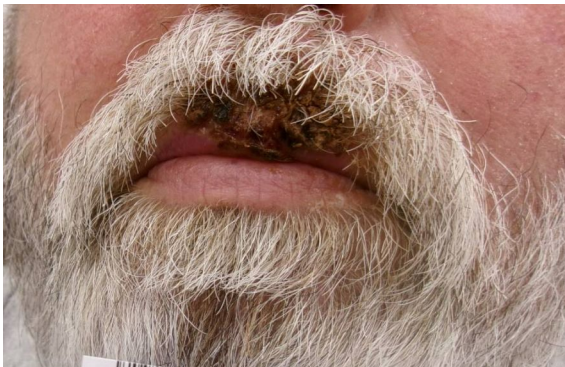
- ~~Budesonide 3mg TID~~
- Acyclovir 400 BID
 - Topical acyclovir
- ~~Isavuconazole 372 daily~~
- ~~Letermovir 480 daily~~
- ~~SMX/TMP SS qMWF~~

Week 4 (day 25)

Heme onc clinic: c/f drug eruption → d/c many of his meds

Derm clinic:

- Worried about the chronicity of lip lesion
 - Did biopsy & PCR
 - No cultures sent
- Didn't talk much of the skin rash



Med list

- ~~Budesonide 3mg TID~~
- Acyclovir 400 BID
 - Topical acyclovir
- ~~Isavuconazole 372 daily~~
- ~~Letermovir 480 daily~~
- ~~SMX/TMP SS qMWF~~



Break 1

[Q1.1] DDx? Infectious or otherwise

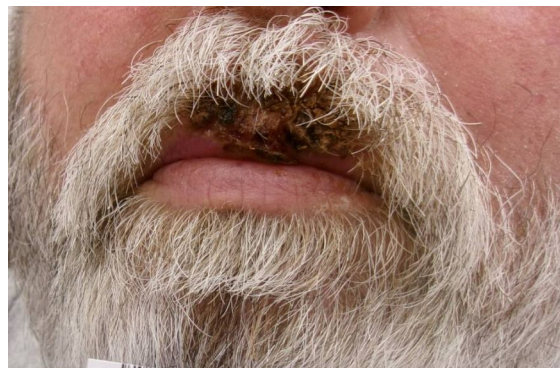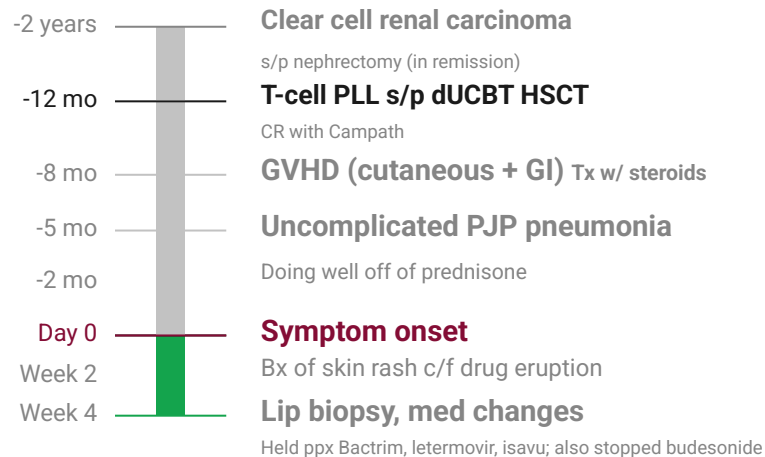
[Q1.2] Diagnostic w/up

[Q1.3] What to do for treatment?

Week 4 (day 25)

Derm clinic: Worried about the chronicity of lip lesion so did lip biopsy w/ PCR

Pathology report: HERPES VIRUS INFECTION



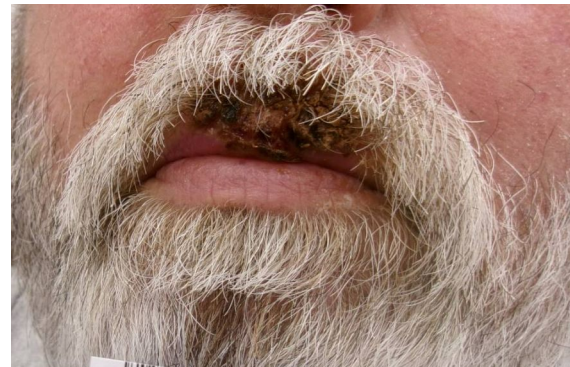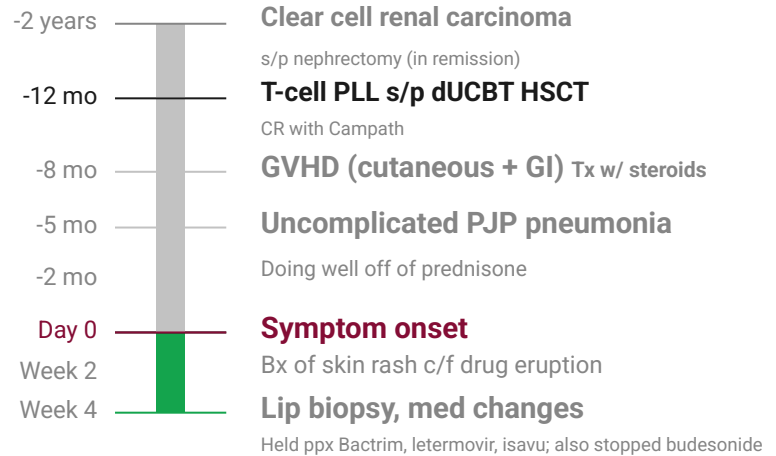
Week 4 (day 25)

Derm clinic: Worried about the chronicity of lip lesion so did lip biopsy w/ PCR

Pathology report: HERPES VIRUS INFECTION

COMMENT: The **histopathologic findings** are consistent with infection by varicella zoster virus (VZV) or herpes simplex virus (HSV). Clinical correlation is essential.

MICROSCOPIC DESCRIPTION: The specimen displays areas of epidermal necrosis with ballooning degeneration of keratinocytes. Many keratinocytes display viral cytopathic changes including multinucleation, nuclear molding, margination of chromatin, and a glassy cytoplasm. Brisk mixed inflammation is present in the dermis



Week 4 (day 25)

Derm clinic: Worried about the chronicity of lip lesion so did lip biopsy w/ PCR

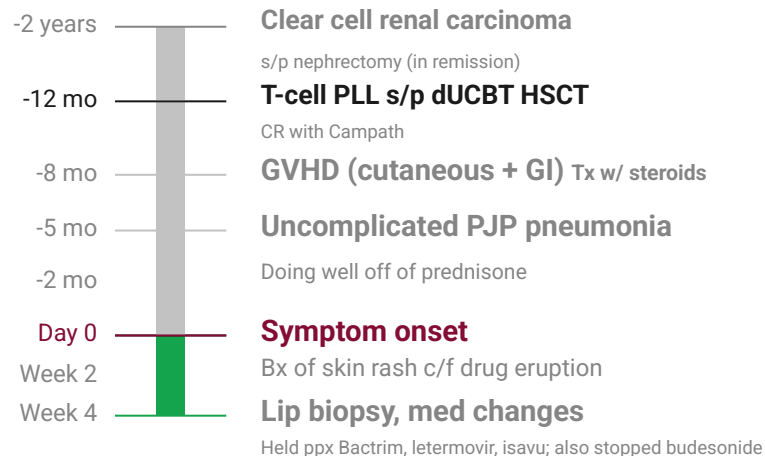
Pathology report: HERPES VIRUS INFECTION

COMMENT: The **histopathologic findings** are consistent with infection by varicella zoster virus (VZV) or herpes simplex virus (HSV). Clinical correlation is essential.

MICROSCOPIC DESCRIPTION: The specimen displays areas of epidermal necrosis with ballooning degeneration of keratinocytes. Many keratinocytes display viral cytopathic changes including multinucleation, nuclear molding, margination of chromatin, and a glassy cytoplasm. Brisk mixed inflammation is present in the dermis

PCR: Positive for **HSV-2**

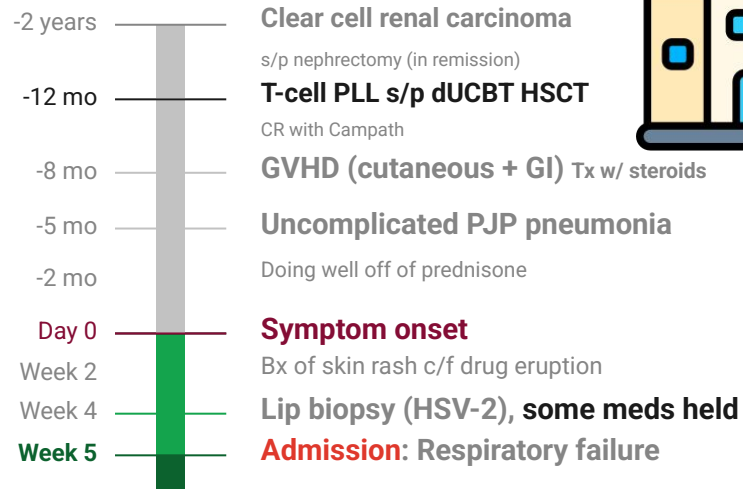
- Negative for VZV or HSV-1



Week 5

Admitted with cough, subjective fevers, & diarrhea

- Tested positive for influenza A
- Tested negative for C diff but still treated anyways..?



Med list

- ~~Budesonide 3mg TID~~
- Acyclovir 400 BID
 - Topical acyclovir
- ~~Isavuconazole 372 daily~~
- ~~Letermovir 480 daily~~
- ~~SMX/TMP SS qMWF~~

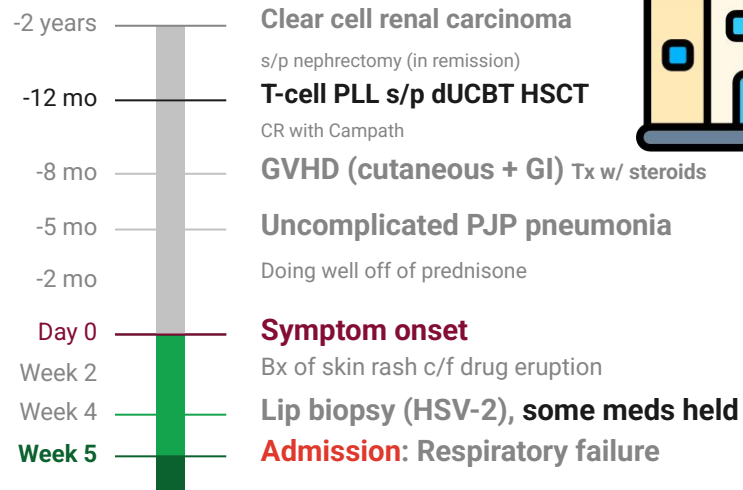
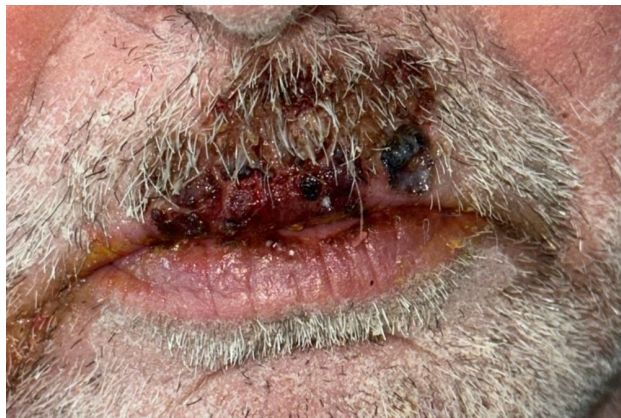

Week 5 (day 35)

Admitted with cough, subjective fevers, & diarrhea

- Tested positive for influenza A
- Tested negative for C diff but still treated anyways..?

Hospitalist was concerned for **HSV** (biopsy wasn't back yet)



Med list

- ~~Budesonide 3mg TID~~
- Acyclovir 400 BID
 - Topical acyclovir
- ~~Isavuconazole 372 daily~~
- ~~Letermovir 480 daily~~
- ~~SMX/TMP SS qMWF~~

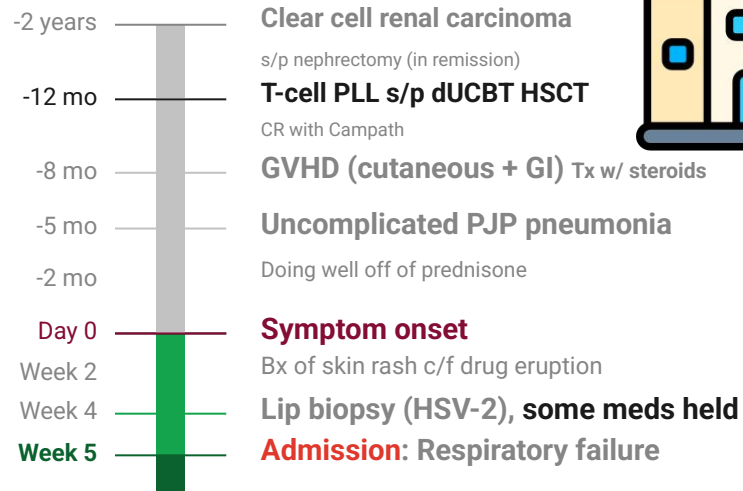
Week 5

Admitted with cough, subjective fevers, & diarrhea

- Tested positive for influenza A
- Tested negative for C diff but still treated anyways..?

Hospitalist was concerned for **HSV**

- Switched acyclovir 400 BID → **valacyclovir 1g BID** x 10 days

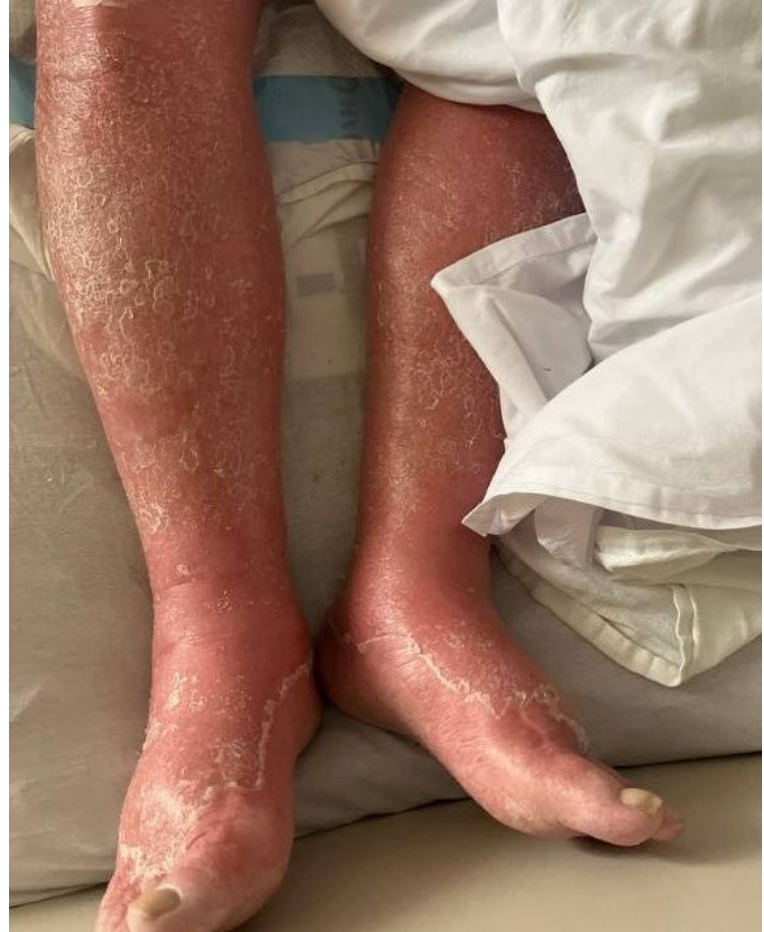
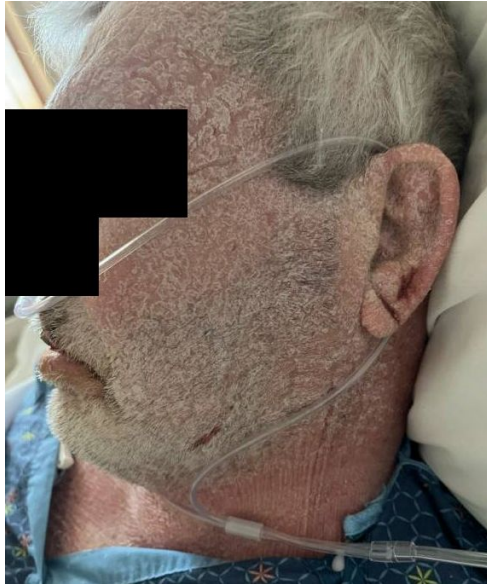
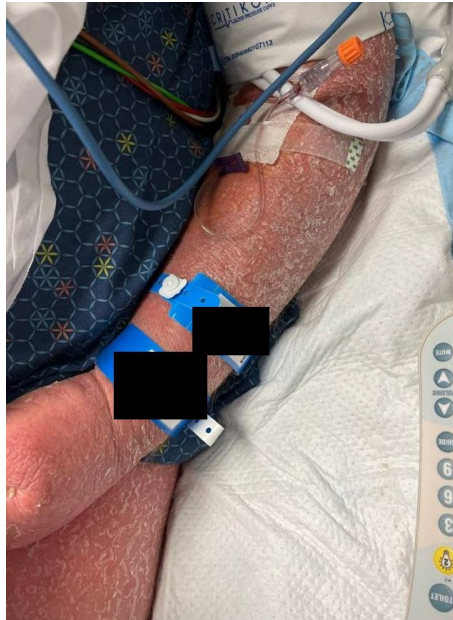Med list

- ~~Budesonide 3mg TID~~
- **Valacyclovir 1g BID**
- ~~Isavuconazole 372 daily~~
- ~~Letemovir 480 daily~~
- ~~SMX/TMP SS qMWF~~

Week 6 (day 39)

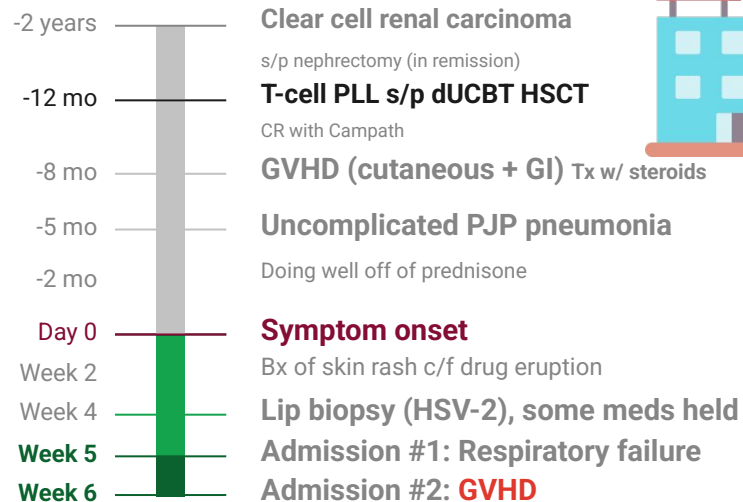
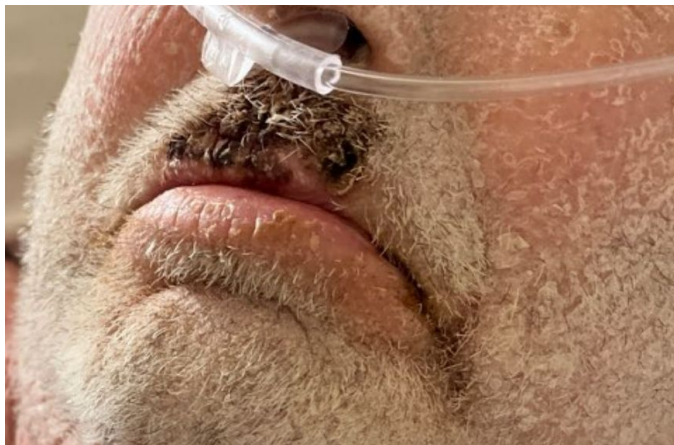Discharged from admission #1 but
readmitted the next day



Week 6 (day 39)

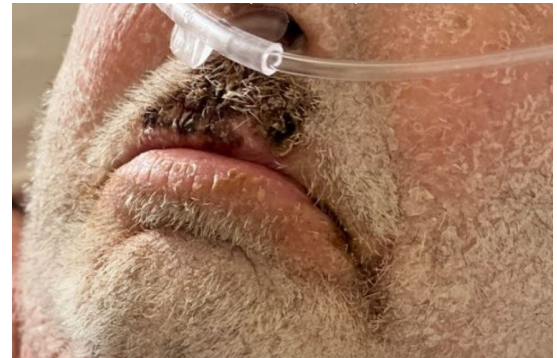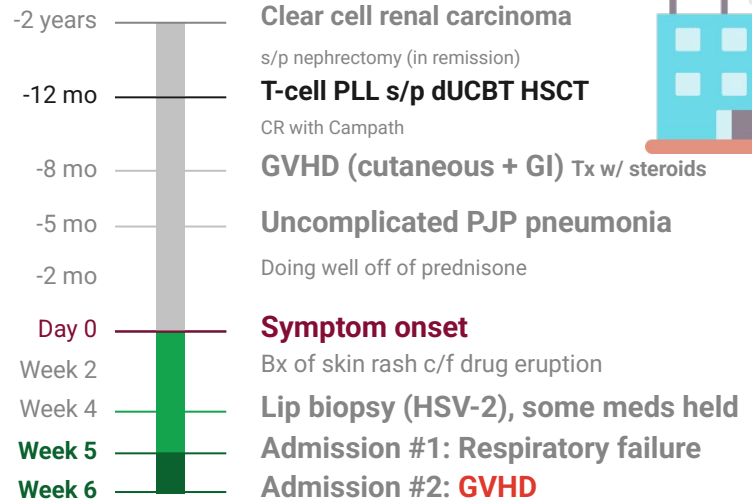
Discharged from admission #1 but readmitted the next day for cGVHD

- Started on high dose steroids for presumed cGVHD



Week 6 (day 39)

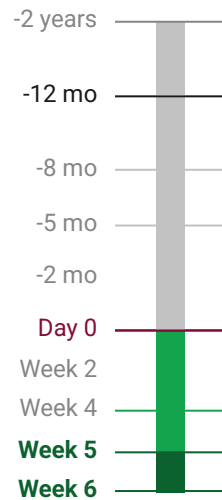
Pathology report: Lichenoid and dyskeratotic **interface dermatitis with dense lymphoeosinophilic cell infiltrates** and features consistent with **acute graft-versus-host disease, grade 2**



Week 6 (day 39)

Pathology report: Lichenoid and dyskeratotic **interface dermatitis with dense lympho eosinophilic cell infiltrates** and features consistent with **acute graft-versus-host disease, grade 2**

Variable irregular acanthosis and atrophy of the epidermis with focal vacuolar alteration of basal cell layer associated with spongiosis and substantial dyskeratosis of epidermal cells, papillary dermal edema, lymphomononuclear cell infiltrate with numerous eosinophils in the papillary dermis are present with epidermal exocytosis of few lymphocytes. Mononuclear cells in close apposition to necrotic keratinocytes known as "**satellite cell necrosis**" are suggested. Vacuolar alteration of basal cells and dyskeratosis of follicular epithelium mostly in the infundibulum



Clear cell renal carcinoma

s/p nephrectomy (in remission)

T-cell PLL s/p dUCBT HSCT

CR with Campath

GVHD (cutaneous + GI) Tx w/ steroids

Uncomplicated PJP pneumonia

Doing well off of prednisone

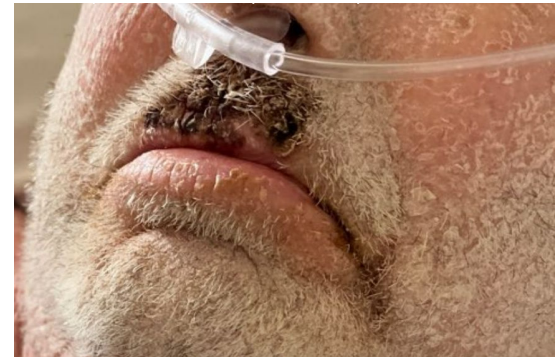Day 0 **Symptom onset**

Week 2 Bx of skin rash c/f drug eruption

Week 4 **Lip biopsy (HSV-2), some meds held**

Week 5 **Admission #1: Respiratory failure**

Week 6 **Admission #2: GVHD**

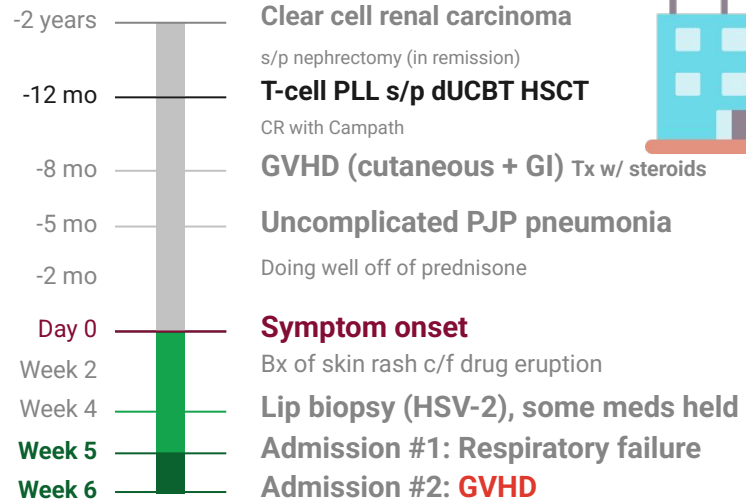


Week 6 (day 39)

Pathology report: Lichenoid and dyskeratotic **interface dermatitis with dense lymphoeosinophilic cell infiltrates** and features consistent with **acute graft-versus-host disease, grade 2**

Variable irregular acanthosis and atrophy of the epidermis with focal vacuolar alteration of basal cell layer associated with spongiosis and substantial dyskeratosis of epidermal cells, papillary dermal edema, lymphomononuclear cell infiltrate with numerous eosinophils in the papillary dermis are present with epidermal exocytosis of few lymphocytes. Mononuclear cells in close apposition to necrotic keratinocytes known as "**satellite cell necrosis**" are suggested. Vacuolar alteration of basal cells and dyskeratosis of follicular epithelium mostly in the infundibulum

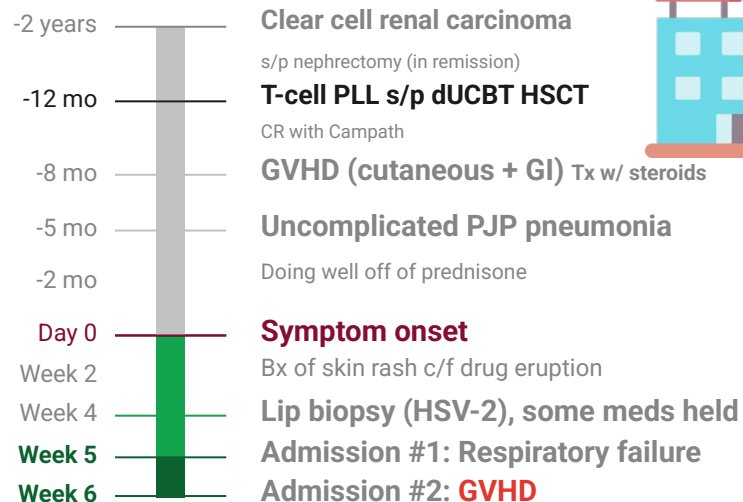
Comment: There are overwhelming histopathological features of an interface dermatitis with focal vacuolar changes at the dermo-epidermal junction associated with prominent dyskeratosis, features that would be appropriate for acute GVHD. However the presence of a **significant number of eosinophils within the infiltrate** may also suggest an **underlying hypersensitivity mechanism** and would not necessarily exclude this type of pathogenesis



Week 6 (day 39)

Discharged from admission #1 but readmitted the next day for GVHD

- Started on **high dose steroids** for presumed cGVHD
 - Also atovaquone & fluconazole ppx



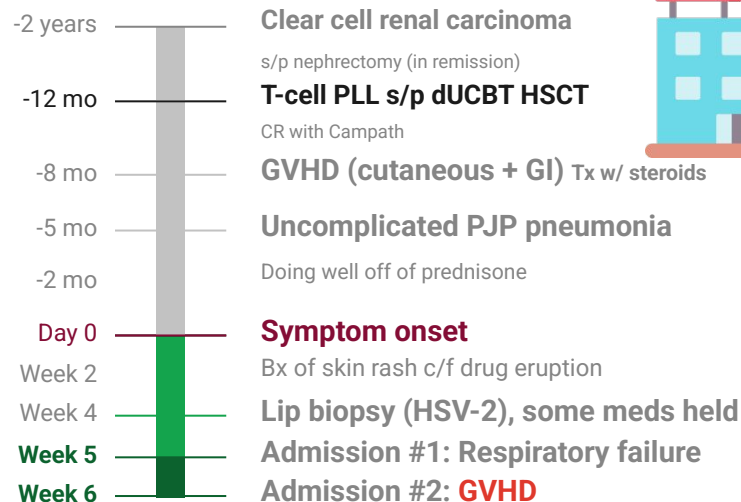
Med list

- **Prednisone** 100
- **Atovaquone** 1500 daily
- **Fluconazole** 200 daily
- Valacyclovir 1g BID
- ~~Letemovir 480 daily~~

Week 6

Discharged from admission #1 but readmitted the next day for GVHD

- Started on **high dose steroids** for presumed cGVHD
 - Also atovaquone & fluconazole ppx
- **Rash improved** with treatment (as did GI symptoms)



Med list

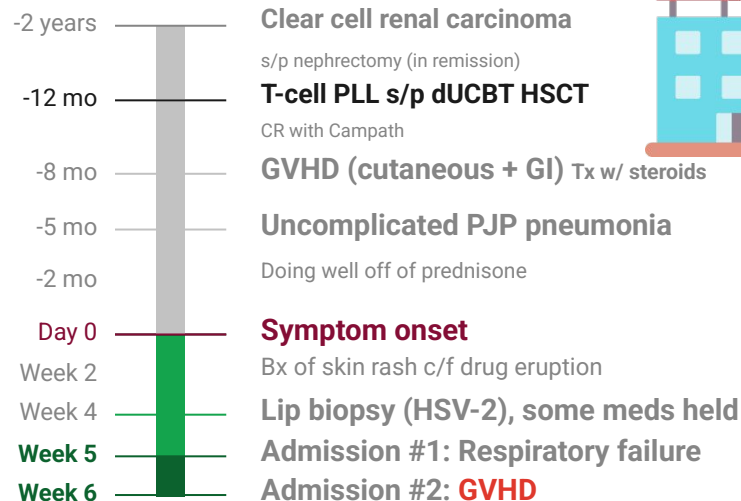
- Prednisone 100
- Atovaquone 1500 daily
- Fluconazole 200 daily
- Valacyclovir 1g BID
- ~~Letermovir 480 daily~~

Week 6 (day 42)

Discharged from admission #1 but readmitted the next day for GVHD

- Started on **high dose steroids** for presumed cGVHD
 - Also atovaquone & fluconazole ppx
- Rash improved** with treatment (as did GI symptoms)

After 10 days of valacyclovir 1g BID →
valacyclovir 500 BID

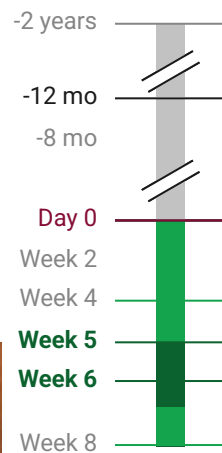
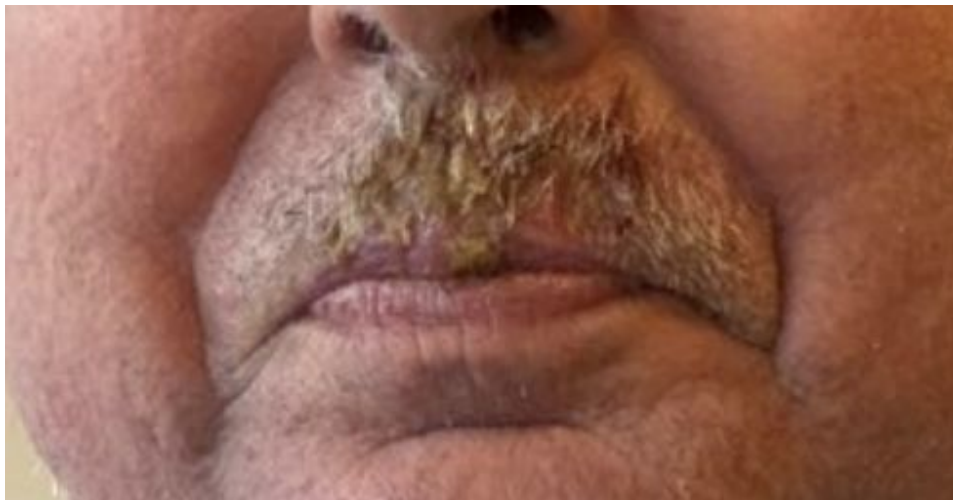

Med list

- Prednisone 100
- Atovaquone 1500 daily
- Fluconazole 200 daily
- Valacyclovir **500** BID
- ~~Letermovir 480 daily~~

Week 8 (day 50)

Dermatology: GHVD responding well (no comment on lip lesion)



Clear cell renal carcinoma
s/p nephrectomy (in remission)
T-cell PLL s/p dUCBT HSCT
GVHD (cutaneous + GI) Tx w/ steroids



Symptom onset

Bx of skin rash c/f drug eruption

Lip biopsy (HSV-2), some meds held

Admission #1: Respiratory failure

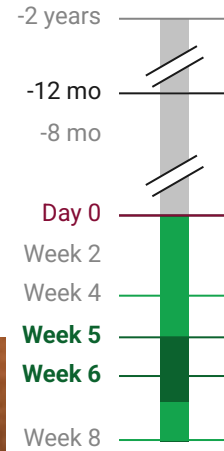
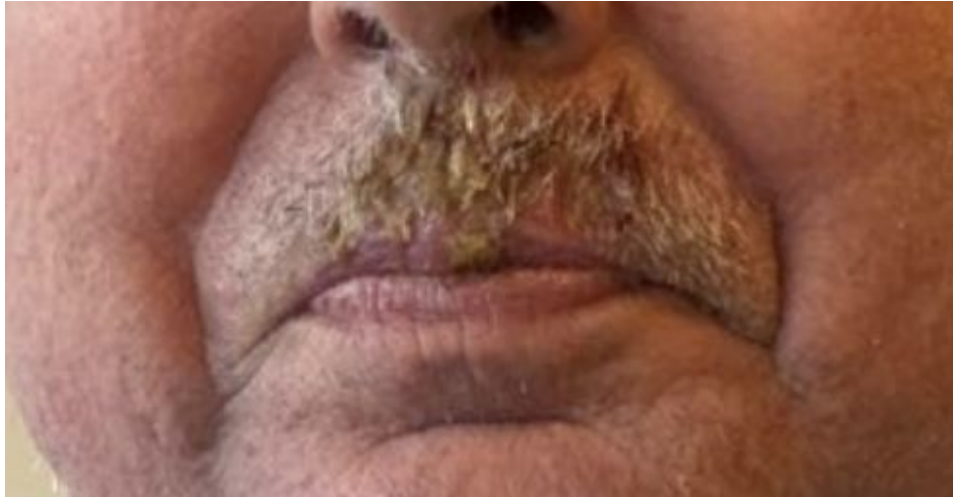Admission #2: GVHD

Started on high dose prednisone

Clinic

Week 8 (day 50)

Dermatology: GHVD responding well (no comment on lip lesion)



Clear cell renal carcinoma
s/p nephrectomy (in remission)
T-cell PLL s/p dUCBT HSCT
GVHD (cutaneous + GI) Tx w/ steroids



Symptom onset

Bx of skin rash c/f drug eruption

Lip biopsy (HSV-2), some meds held

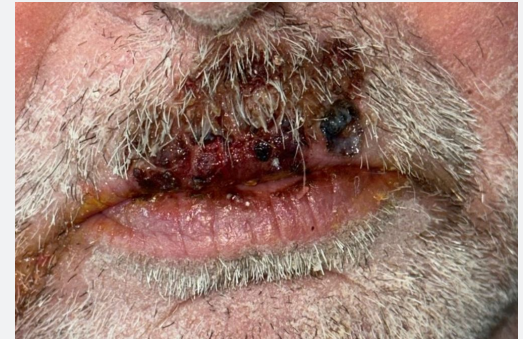Admission #1: Respiratory failure

Admission #2: GVHD

Started on high dose prednisone

Clinic

From day 35



Week 8 (day 50)

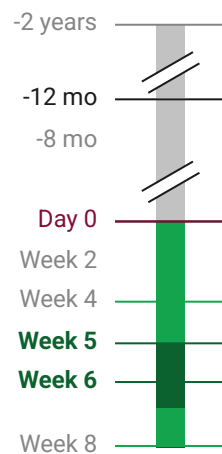
Dermatology: GHVD responding well

Heme/Onc clinic:

- Doing well, start **tapering prednisone** by 10mg weekly

Med list

- Prednisone 100
- Atovaquone 1500 daily
- Fluconazole 200 daily
- Valacyclovir 500 BID
- ~~Letermovir 480 daily~~



Clear cell renal carcinoma
s/p nephrectomy (in remission)
T-cell PLL s/p dUCBT HSCT
GVHD (cutaneous + GI) Tx w/ steroids



Symptom onset

Bx of skin rash c/f drug eruption

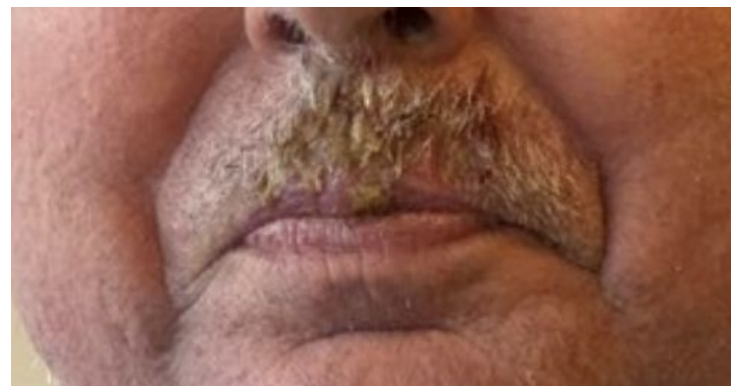
Lip biopsy (HSV-2), some meds held

Admission #1: Respiratory failure

Admission #2: GVHD

Started on high dose prednisone

Clinic

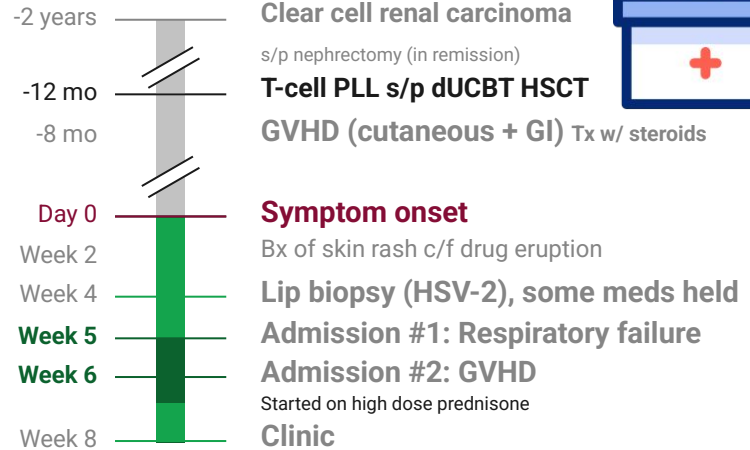


Week 8 (day 50)

Dermatology: GHVD responding well

Heme/Onc clinic:

- Doing well, start **tapering prednisone** by 10mg weekly
- Insurance approved **Jakafi** (Ruxolitinib, tyrosine kinase inhibitor)



Med list

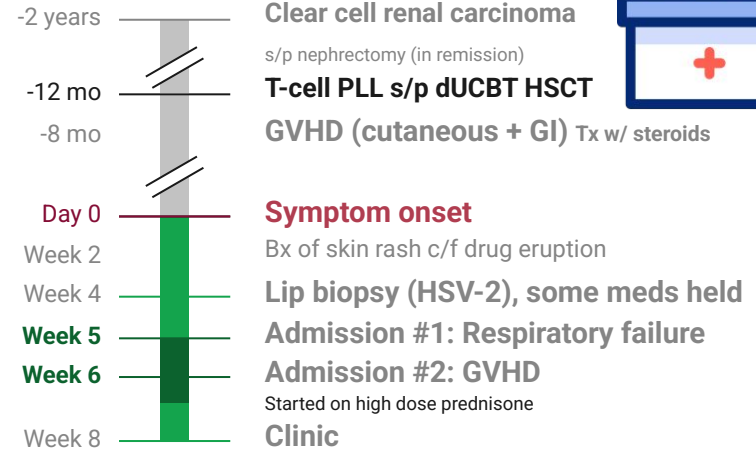
- Prednisone 100
- **Ruxolitinib** (Jakafi)
- Atovaquone 1500 daily
- Fluconazole 200 daily
- Valacyclovir 500 BID
- ~~Letermovir 480 daily~~

Week 8 (day 50)

Dermatology: GHVD responding well

Heme/Onc clinic:

- Doing well, start **tapering prednisone** by 10mg weekly
- Insurance approved **Jakafi** (Ruxolitinib, tyrosine kinase inhibitor)
- **Posaconazole** approved (for PPx)

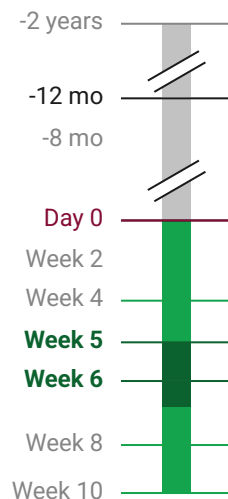
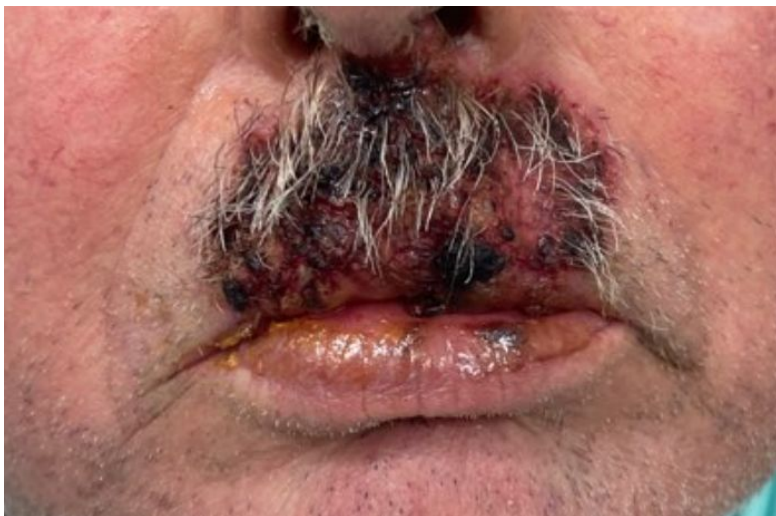

Med list

- Prednisone 100
- Ruxolitinib (Jakafi)
- Atovaquone 1500 daily
- **Posaconazole** 300 daily
- Valacyclovir 500 BID
- ~~Letermovir 480 daily~~

Week 10 (day 64)

Heme/Onc clinic: Upper **lip lesion worsening** in past week. Now on pred 70 + Ruxolitinib



Clear cell renal carcinoma

s/p nephrectomy (in remission)

T-cell PLL s/p dUCBT HSCT

GVHD (cutaneous + GI) Tx w/ steroids

Symptom onset

Bx of skin rash c/f drug eruption

Lip biopsy (HSV-2), some meds held

Admission #1: Respiratory failure

Admission #2: GVHD

Started on high dose prednisone

Clinic: Started Jakafi

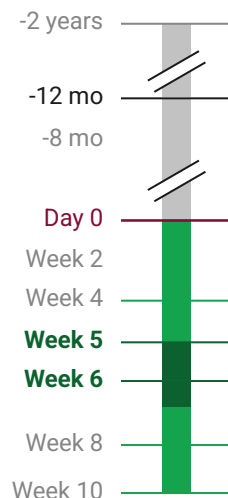
Clinic



Week 10 (day 64)

Heme/Onc clinic: Upper **lip lesion worsening** in past week. Now on pred 70 + Ruxolitinib

Derm: Feels this is consistent with HSV, but wants to get ID's input



Clear cell renal carcinoma

s/p nephrectomy (in remission)

T-cell PLL s/p dUCBT HSCT

GVHD (cutaneous + GI) Tx w/ steroids

Symptom onset

Bx of skin rash c/f drug eruption

Lip biopsy (HSV-2), some meds held

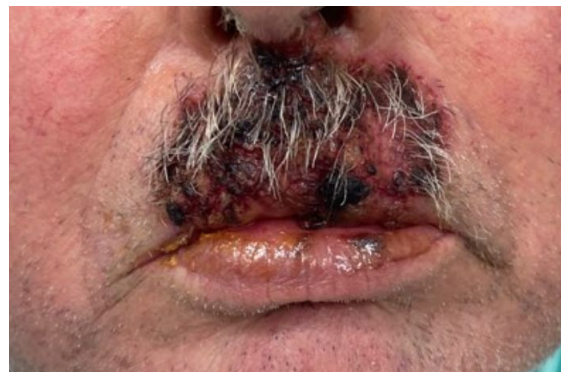Admission #1: Respiratory failure

Admission #2: GVHD

Started on high dose prednisone

Clinic: Started Jakafi

Clinic

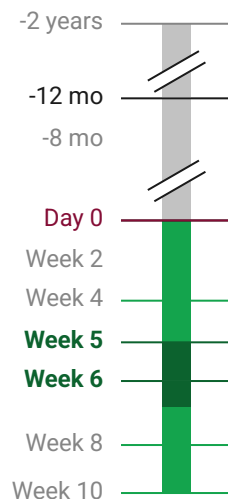


Week 10 (day 64)

Heme/Onc clinic: Upper **lip lesion worsening** in past week. Now on pred 70 + Ruxolitinib

Derm: Feels this is consistent with HSV, but wants to get ID's input

- Sends HSV & VZV PCR
- Starts therapeutic valacyclovir (1g BID)



Clear cell renal carcinoma
s/p nephrectomy (in remission)
T-cell PLL s/p dUCBT HSCT
GVHD (cutaneous + GI) Tx w/ steroids



Symptom onset

Bx of skin rash c/f drug eruption

Lip biopsy (HSV-2), some meds held

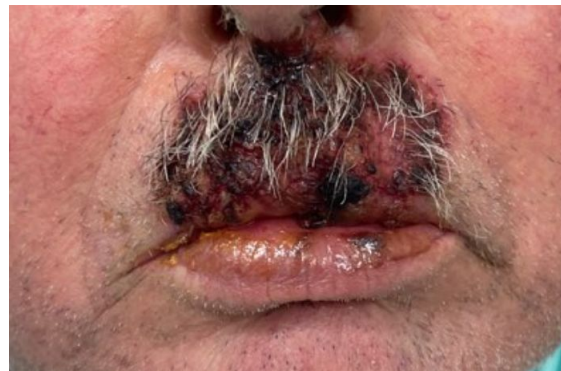Admission #1: Respiratory failure

Admission #2: GVHD

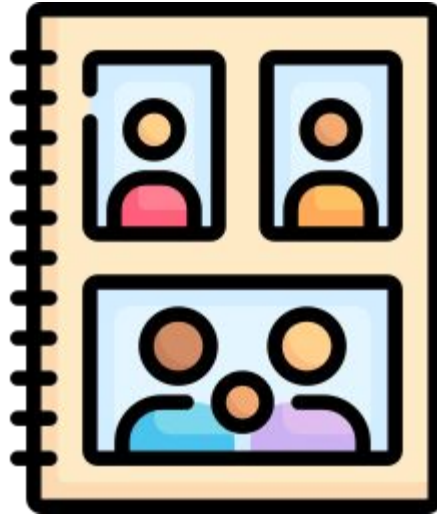
Started on high dose prednisone

Clinic: Started Jakafi

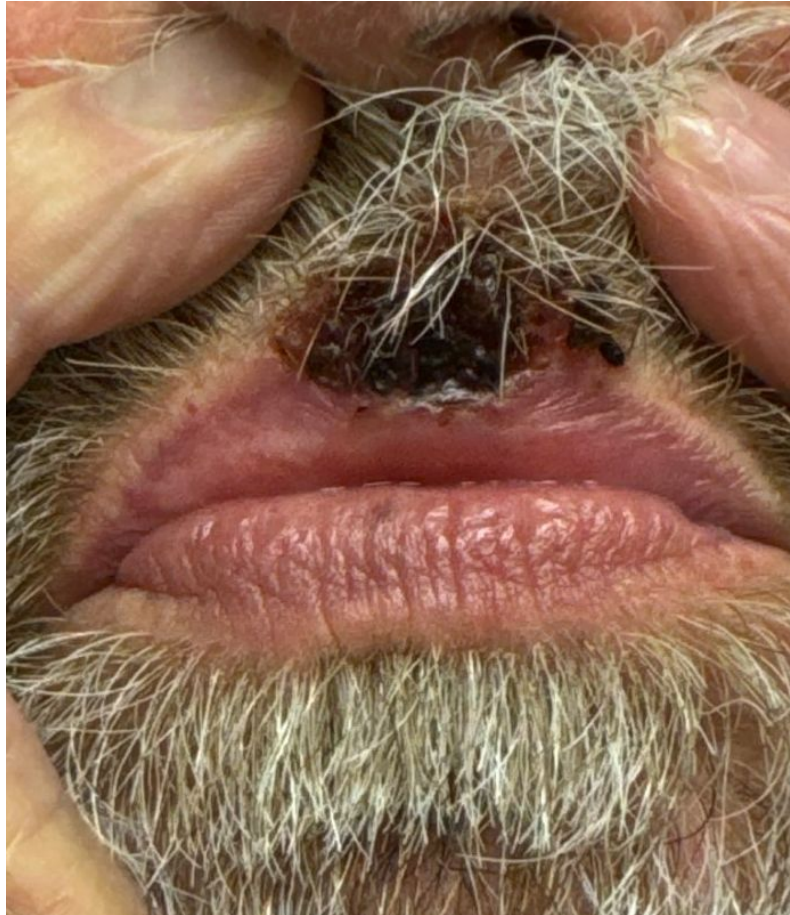Clinic



Recap of pictures & treatments (thus far)



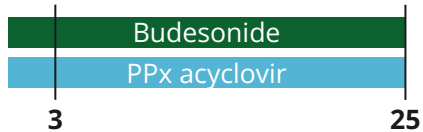
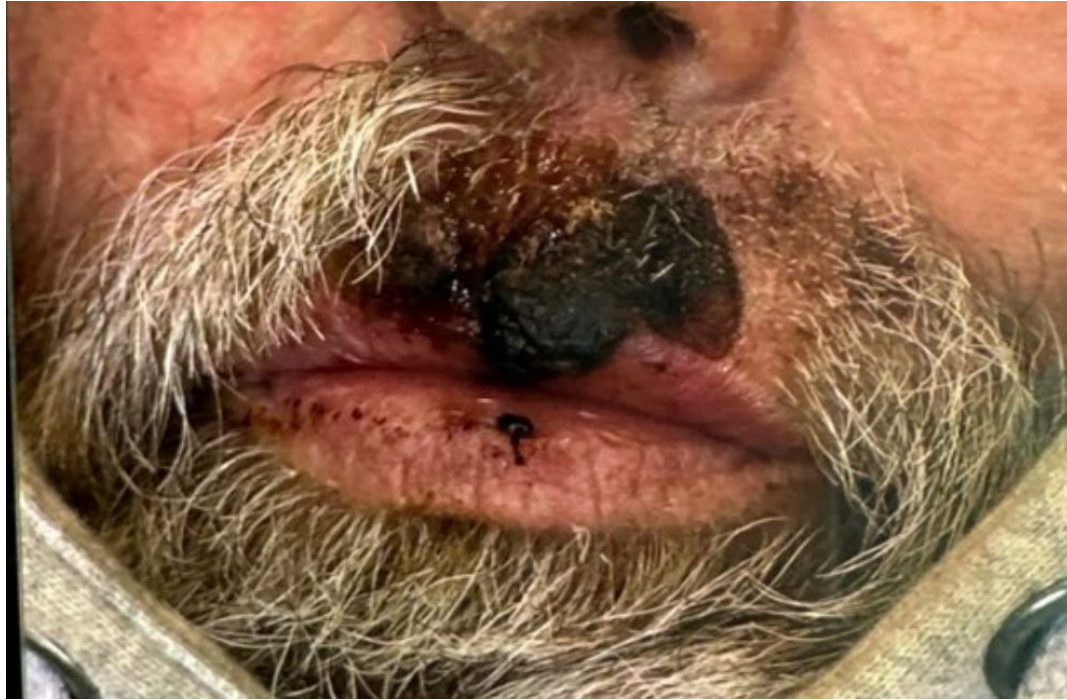Day 3



Antivirals

- PPx (val)acyclovir
- Therapeutic valacyclovir

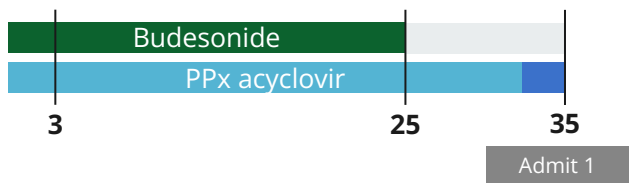
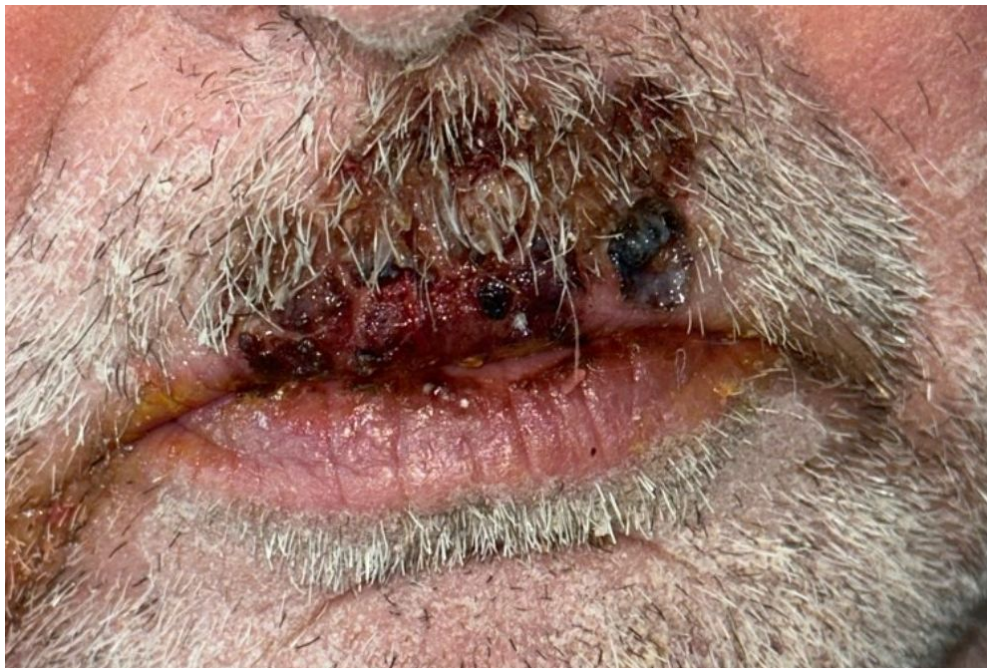Day 25



Antivirals

- PPx (val)acyclovir
- Therapeutic valacyclovir

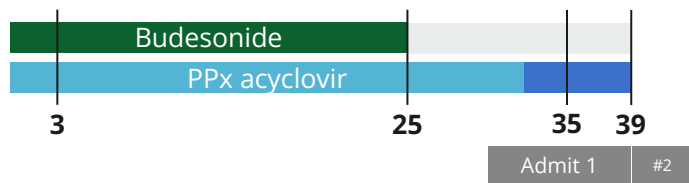
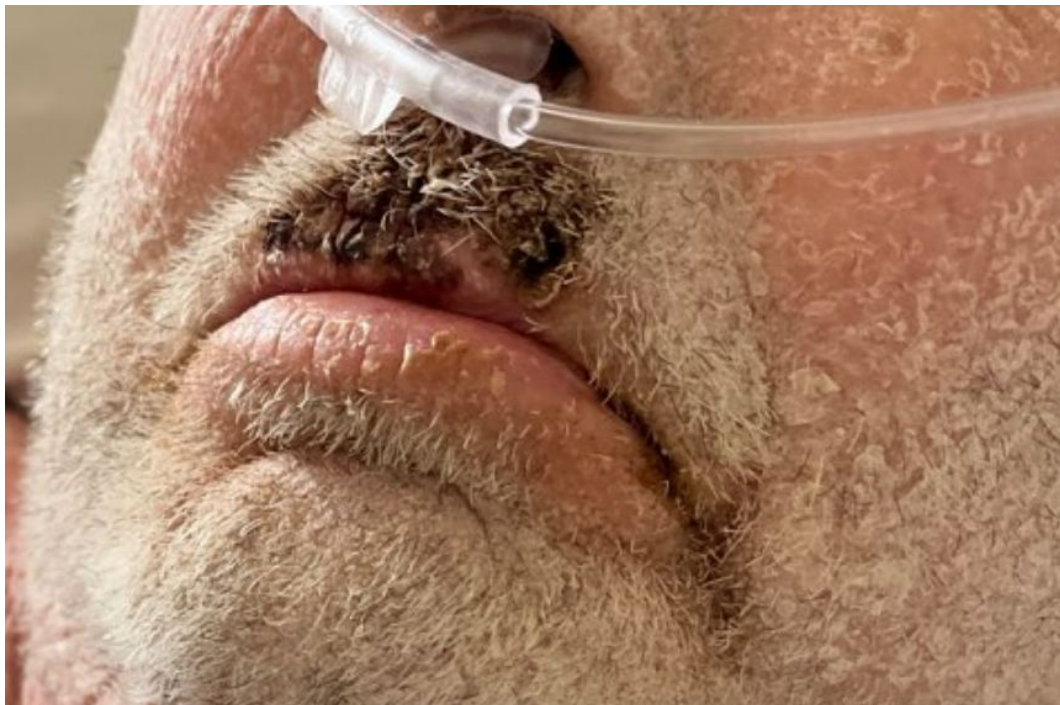Day 35



Antivirals

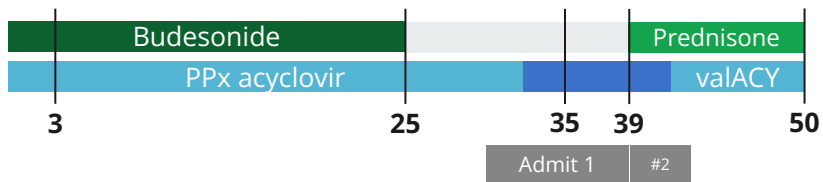
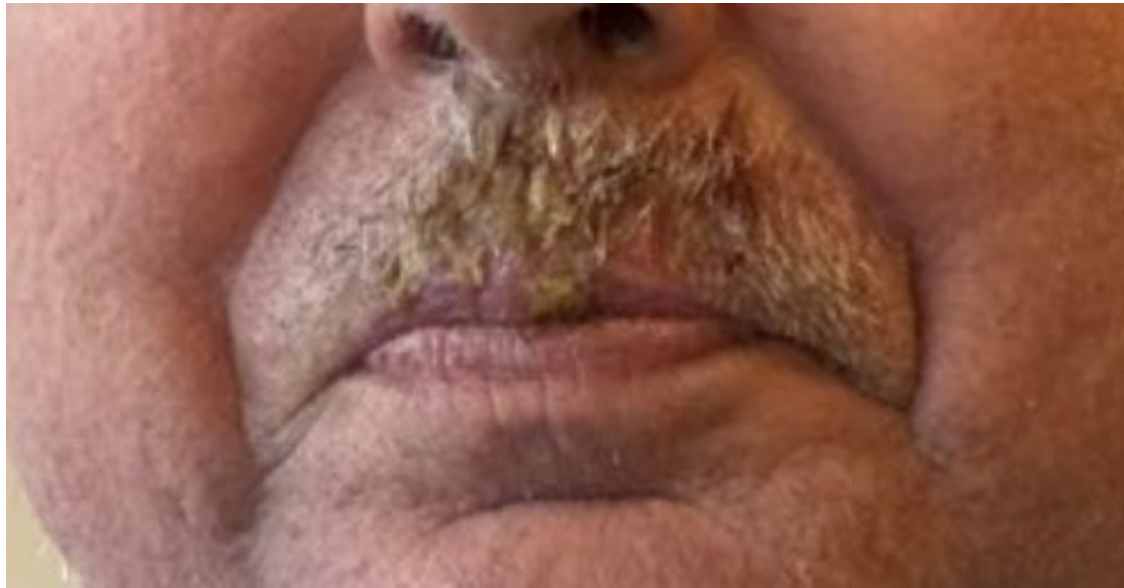- PPx (val)acyclovir
- Therapeutic valacyclovir

Day 39



Antivirals
■ PPx (val)acyclovir
■ Therapeutic valacyclovir

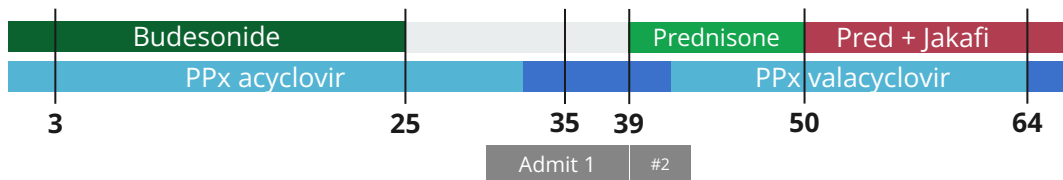
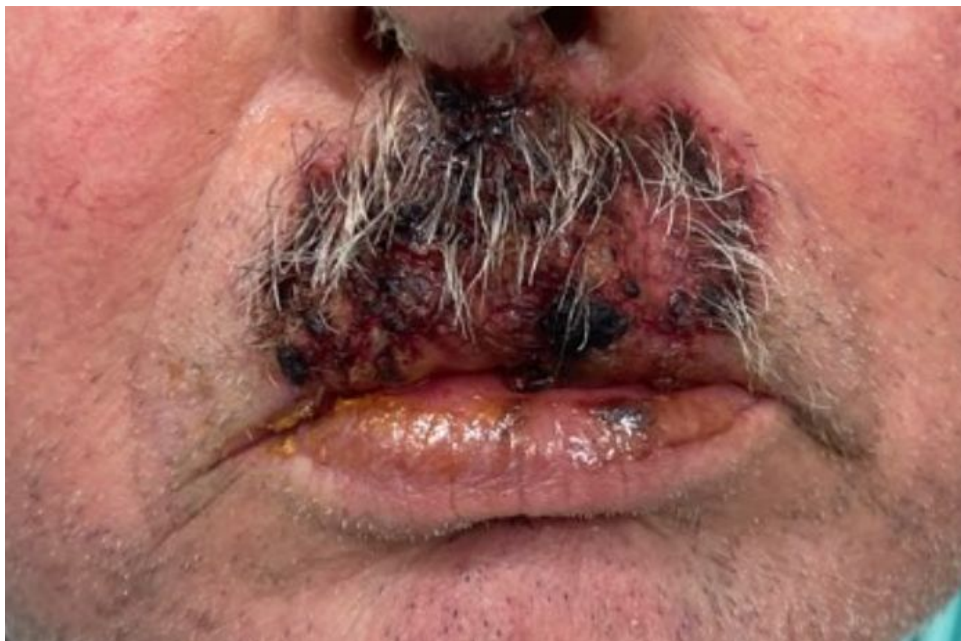Day 50



Antivirals

- PPx (val)acyclovir
- Therapeutic valacyclovir

Day 64



Antivirals

- PPx (val)acyclovir
- Therapeutic valacyclovir

**What would you
do?**

Week 10 (day 64)

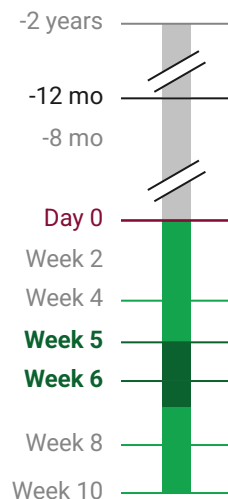
Heme/Onc clinic: Upper **lip lesion worsening** in past week. Now on pred 70 + Ruxolitinib

Derm: Feels this is consistent with HSV, but wants to get ID's input

- Sends **HSV & VZV** PCR
- Starts therapeutic valacyclovir (1g BID)

PCR: Positive for HSV-2

- Negative for VZV or HSV-1



Clear cell renal carcinoma

s/p nephrectomy (in remission)

T-cell PLL s/p dUCBT HSCT

GVHD (cutaneous + GI) Tx w/ steroids

Symptom onset

Bx of skin rash c/f drug eruption

Lip biopsy (HSV-2), some meds held

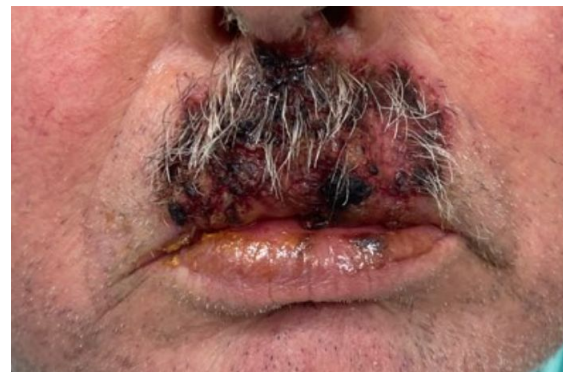Admission #1: Respiratory failure

Admission #2: GVHD

Started on high dose prednisone

Clinic: Started Jakafi

Clinic

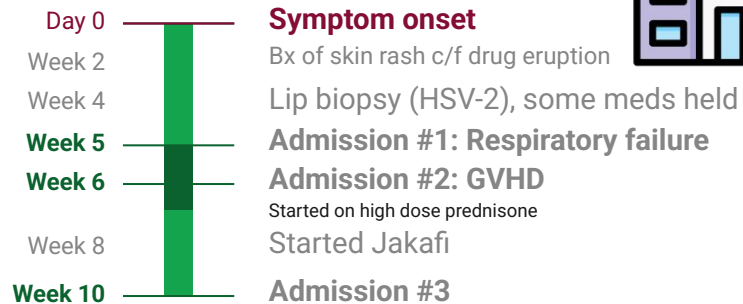




Week 10



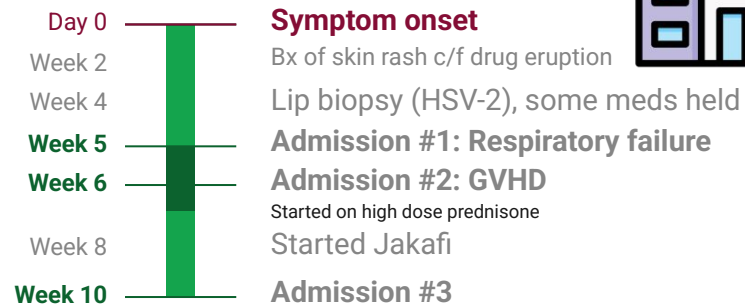
ID e-consulted: Should be admitted to get testing for **TK-deficient HSV** and consideration for IV therapy





Week 10 (day 66)

ID e-consulted: Should be admitted to get testing for **TK-deficient HSV** and consideration for IV therapy



Viral culture

- Sent to ARUP
- Didn't grow :(

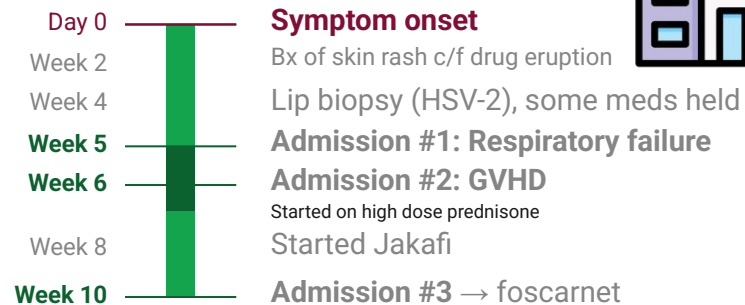
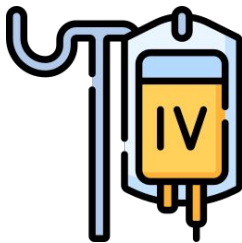


Admission #3

ID e-consulted: Should be admitted to get testing for **TK-deficient HSV** and consideration for IV therapy

Started on **foscarnet** (day 67)

- Discharged on OPAT (renal fxn stable)
- Derm wanted topical cidofovir (insurance did not want this)



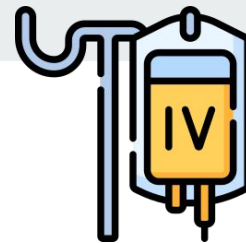
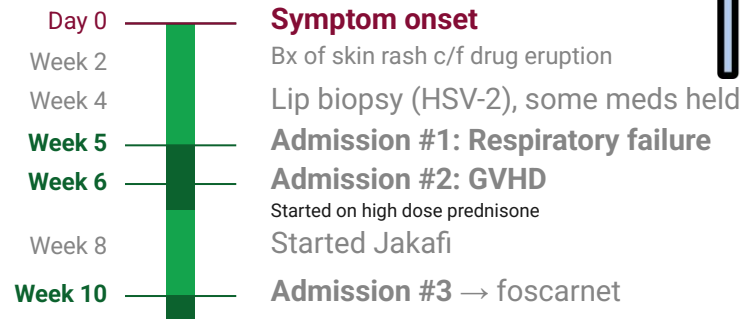
Viral culture

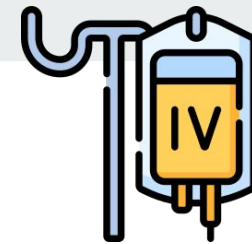
- Sent to ARUP
- Didn't grow :(

OPAT

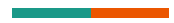Discharged on 2 weeks of **foscarnet**

- Renal function was stable





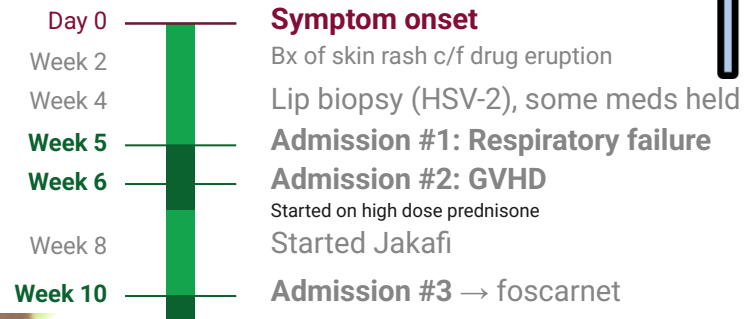
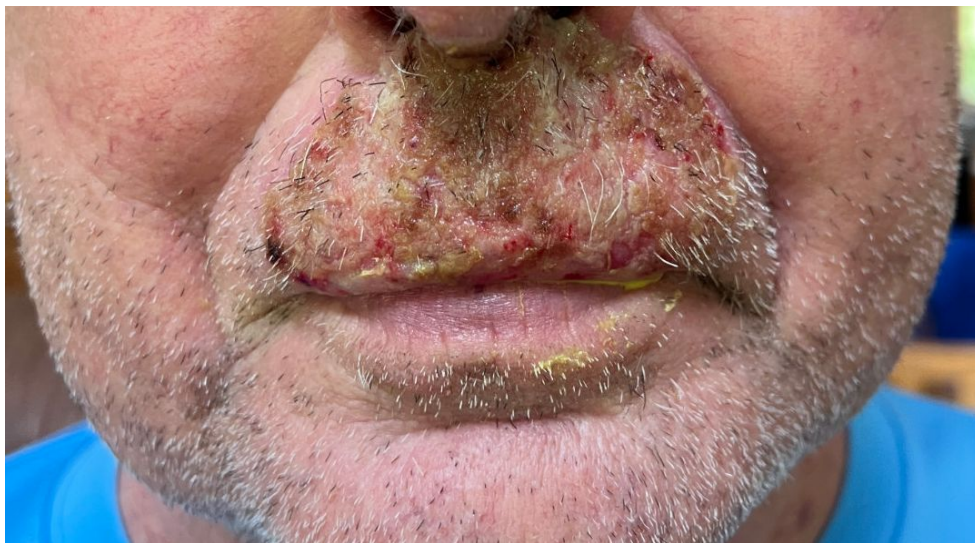OPAT (day 75)



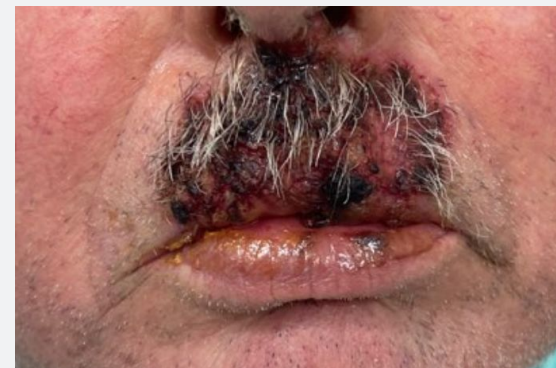
Discharged on 2 weeks of **foscarnet**

- Renal function was stable


Noticeable **improvement** at **one week** of Tx



Before foscarnet (Day 64)

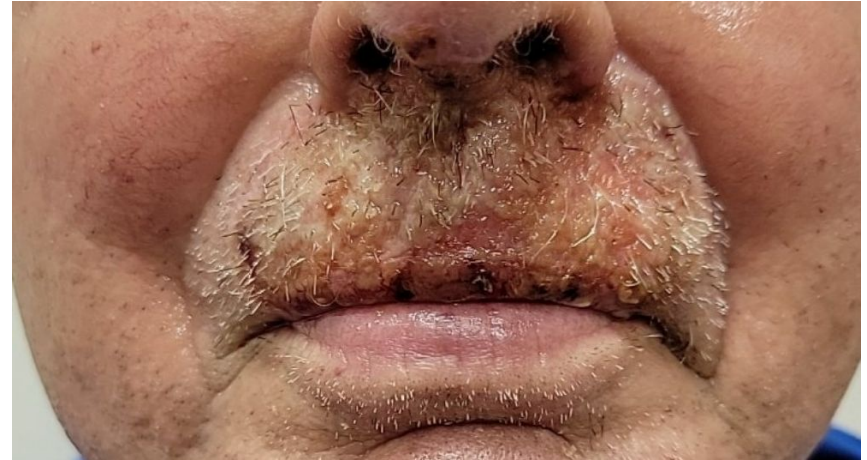

Week 12 (day 78)



Transplant ID clinic:

- Renal function was stable
- Lip lesions looked better than they ever had (on **foscarnet** at that time; day 11 of 14)

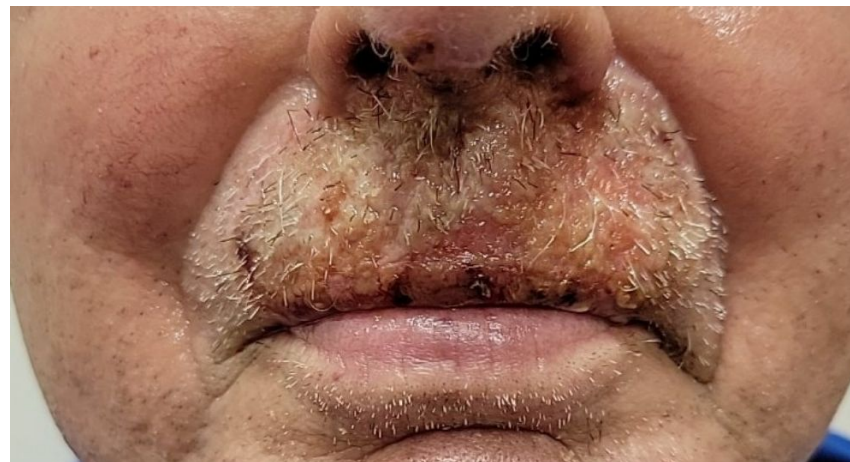




Week 12 (day 78)

Transplant ID clinic:

- Renal function was stable
- Lip lesions looked better than they ever had (on **foscarnet** at that time; day 11 of 14)



We are here



Antivirals

- PPx (val)acyclovir
- Tx valacyclovir
- Foscarnet

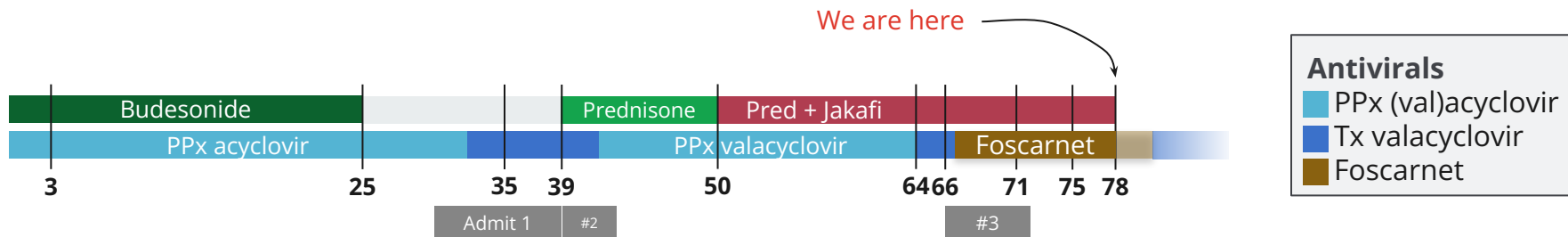


Week 12 (day 78)

Transplant ID clinic:


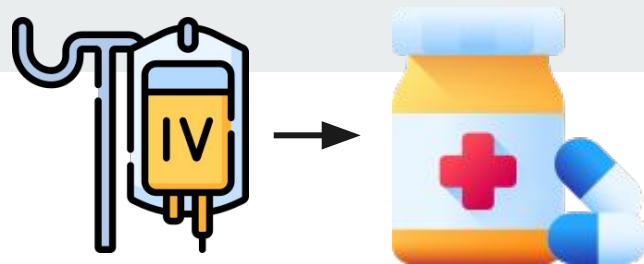
- Renal function was stable
- Lip lesions looked better than they ever had (on **foscarnet** at that time; day 11 of 14)

Planned for finishing 2 weeks of **foscarnet** followed by **valacyclovir** 1g BID



Week 12 (day 81)

Finished two weeks of **foscarnet** →
valacyclovir 1g BID


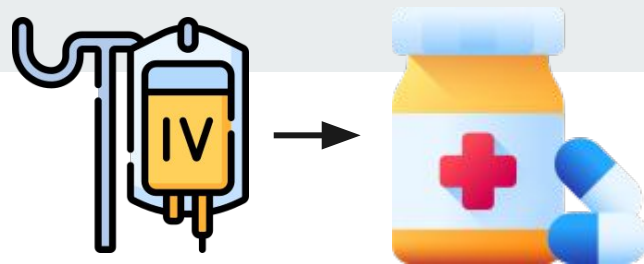


Week 12 (day 81)

Finished two weeks of **foscarnet** →
valacyclovir 1g BID

Around the same time, he noticed **oral thrush**

- No pictures in the EMR :(





Week 12 (day 81)

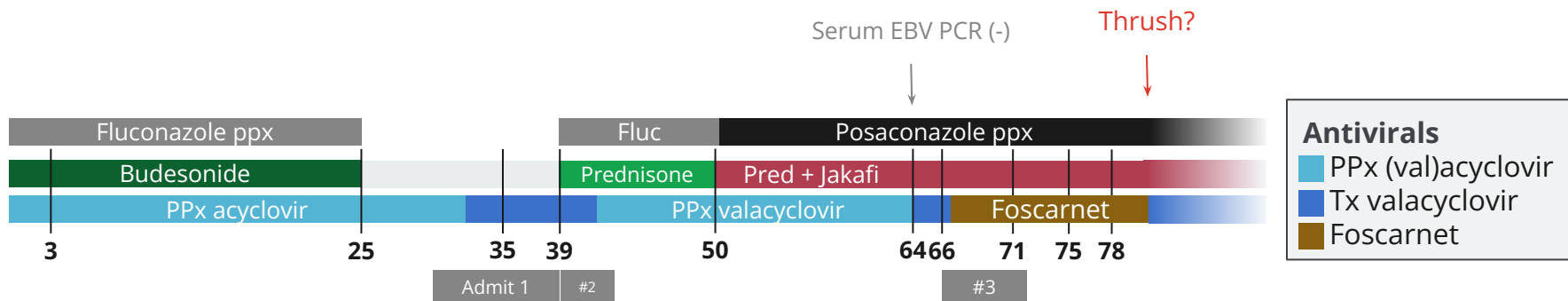
Finished two weeks of **foscarnet** →
valacyclovir 1g BID

Around the same time, he noticed **oral thrush**

- No pictures in the EMR :(
- Notably had **been on posaconazole**
 - Serum **EBV PCR** was **negative** (day 64)

Med list

- Prednisone **40**
- Ruxolitinib (Jakafi)
- Atovaquone 1500 daily
- **Posaconazole** 300 daily
- Valacyclovir 1g BID
- ~~Letermovir 480 daily~~





Week 12 (day 81)


Finished two weeks of **foscarnet** →
valacyclovir 1g BID

Around the same time, he noticed **oral thrush**

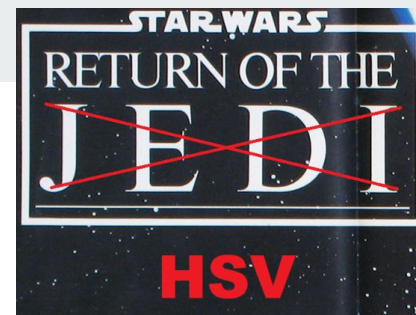
- No pictures in the EMR :(
- Notably had **been on posaconazole**
 - Serum **EBV PCR** was **negative** (day 64)
- Hematology Rx'ed **nystatin swish and swallow**

Med list

- Prednisone **40**
- Ruxolitinib (Jakafi)
- Atovaquone 1500 daily
- **Posaconazole** 300 daily
 - **Nystatin** S&S
- Valacyclovir 1g BID
- ~~Letemovir 480 daily~~

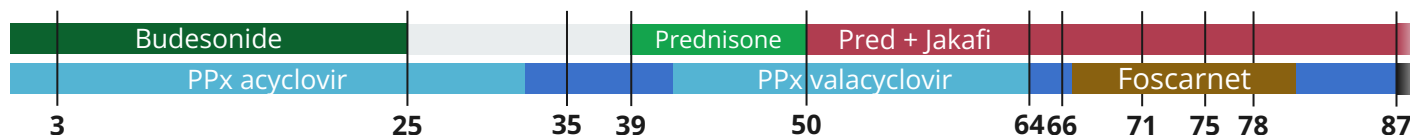


Week 13 (day 87)



Transplant ID & derm clinic:

- **Good news:** Thrush is better with nystatin S&S (+posa)
- **Bad news:**



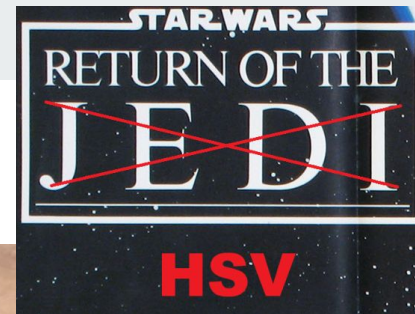
Antivirals

- PPx (val)acyclovir
- Tx valacyclovir
- Foscarnet

Admit 1

#2

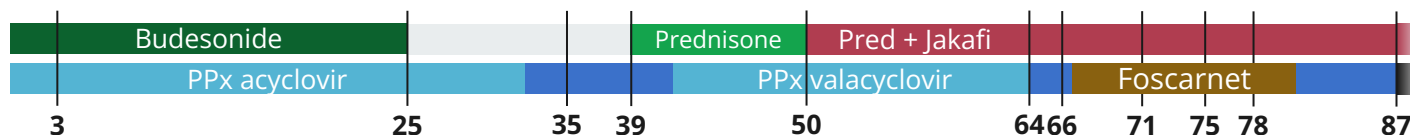
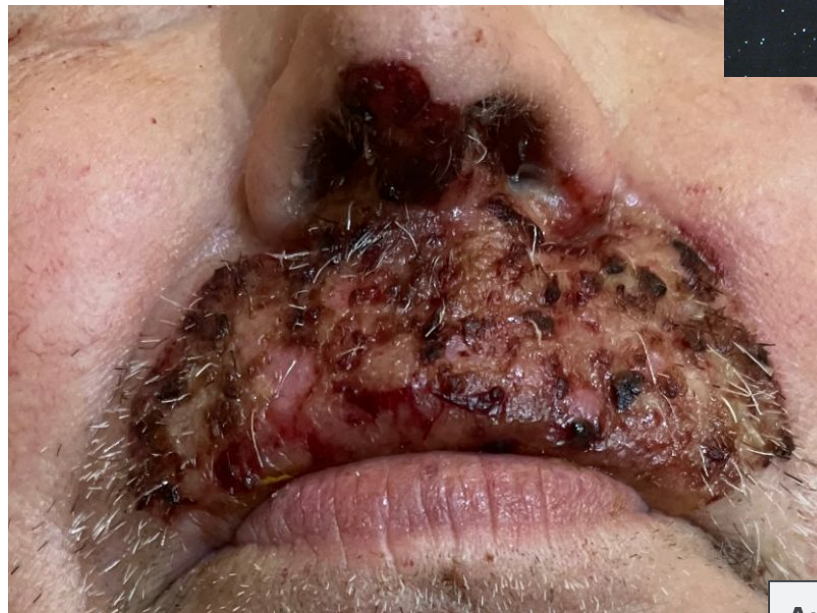#3



Week 13 (day 87)

Transplant ID & derm clinic:

- Patient says **lip has gotten worse** since **stopping foscarnet**



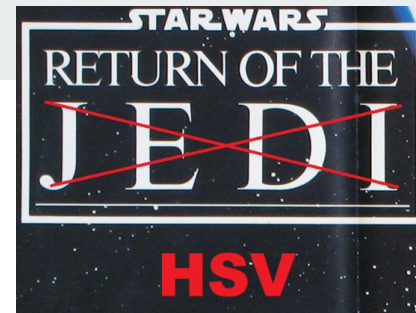
Admit 1 #2

#3

Antivirals

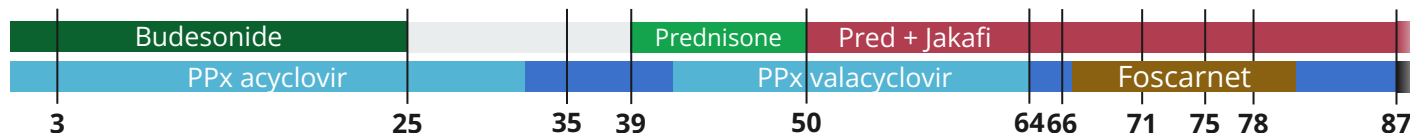
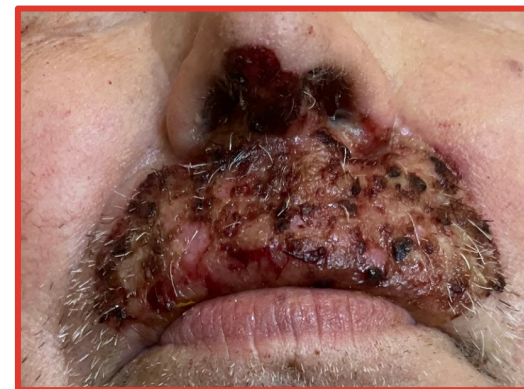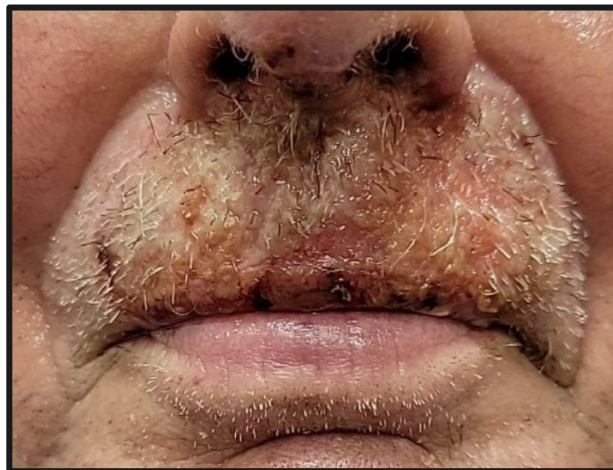- PPx (val)acyclovir
- Tx valacyclovir
- Foscarnet

Week 13 (day 87)



Transplant ID & derm clinic:

- Patient says **lip has gotten worse** since **stopping foscarnet**



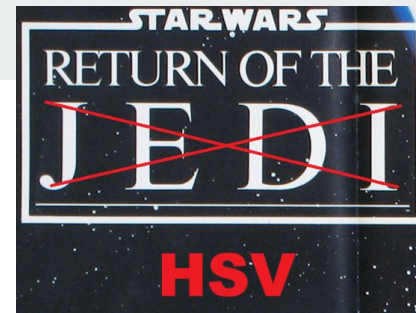
Antivirals

- PPx (val)acyclovir
- Tx valacyclovir
- Foscarnet

Admit 1 #2

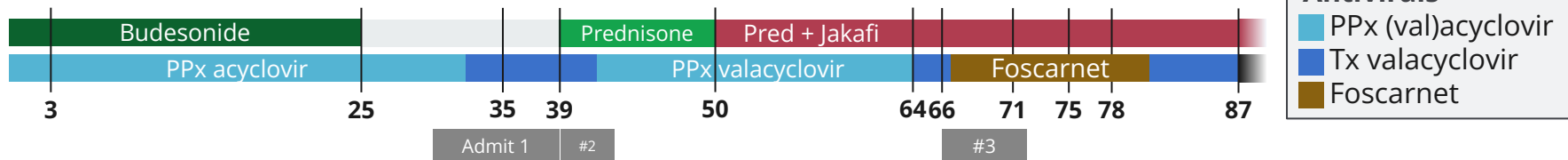#3

Week 13 (day 87)

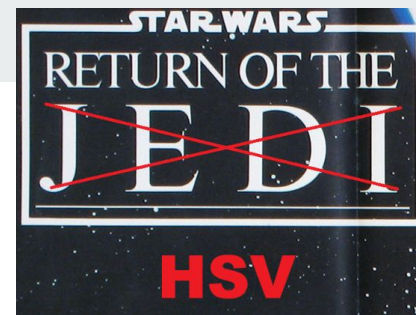


Transplant ID & derm clinic:

- Patient says lip has gotten worse since stopping foscarnet
- Still fighting insurance for topical cidofovir



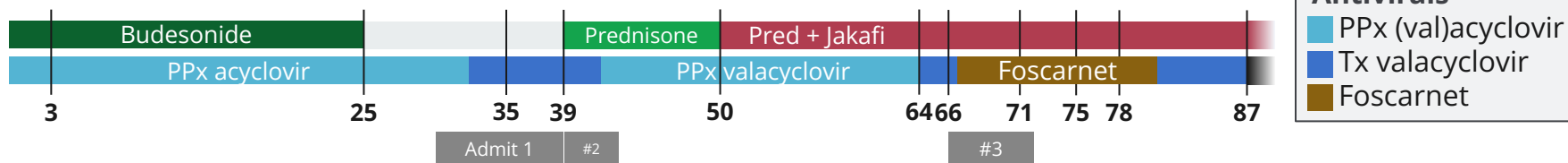
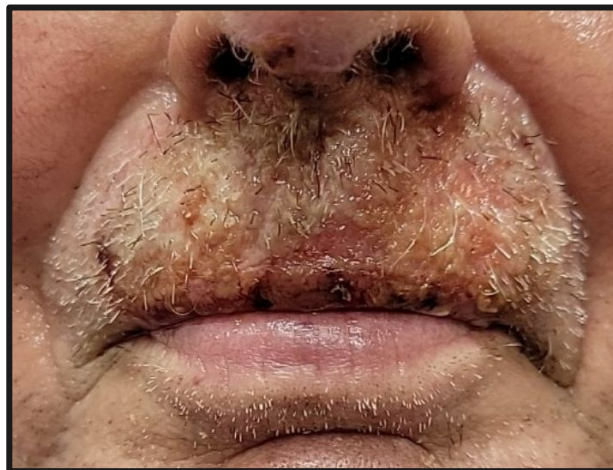
Week 13 (day 87)



Transplant ID & derm clinic:

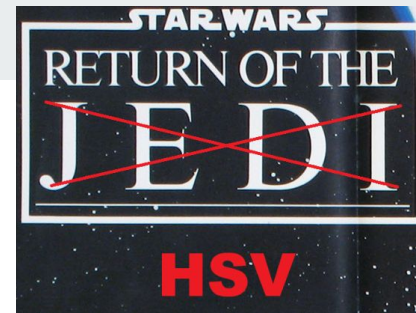
- Patient says **lip has gotten worse** since **stopping foscarnet**
- Still **fighting insurance** for **topical cidofovir**

PCR: Positive for HSV-2
• Negative for HSV-1



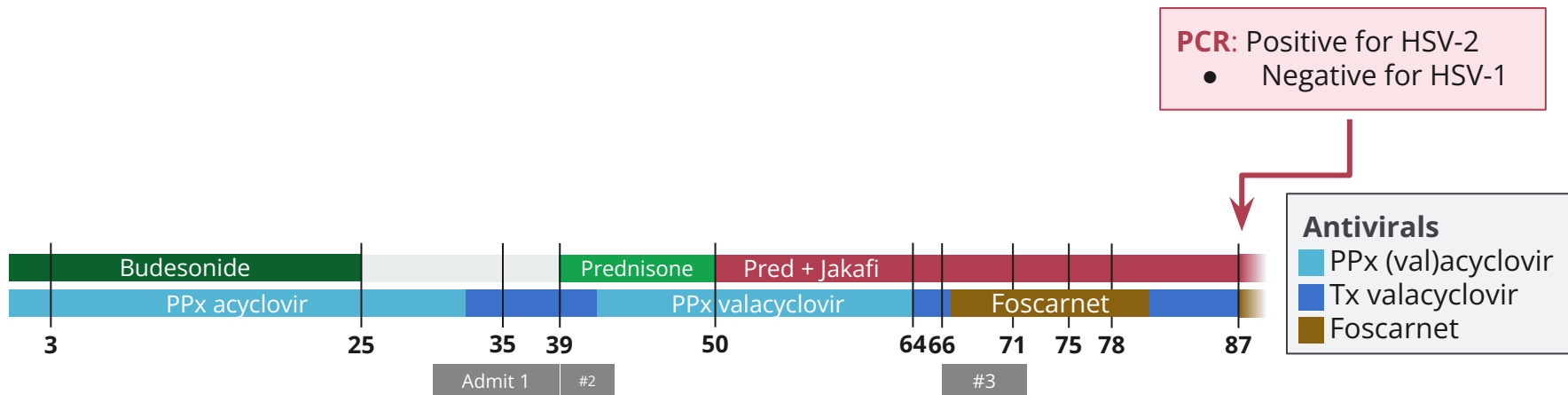
**What would you
do?**

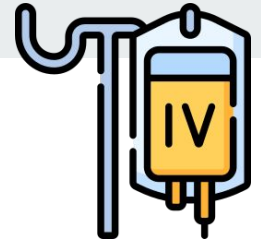
Week 13



Transplant ID & derm clinic:

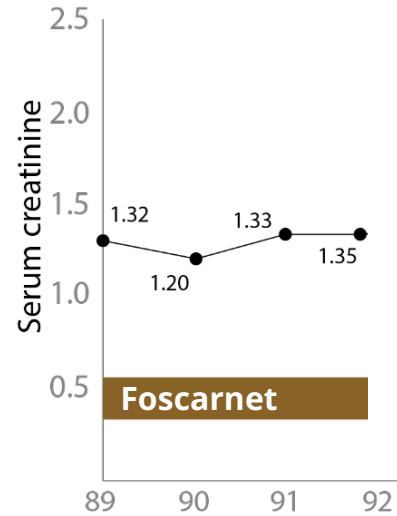
- Restart **foscarnet**
- Would take a few days to get PICC & OPAT set up





OPAT: Week 14

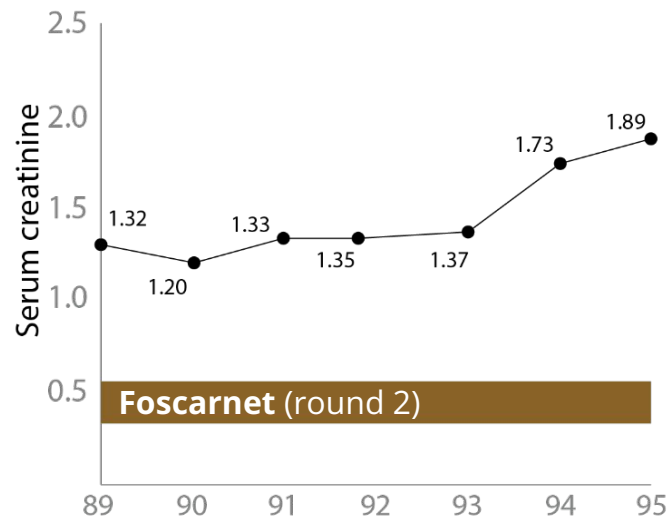

Started on **foscarnet** with stable renal function



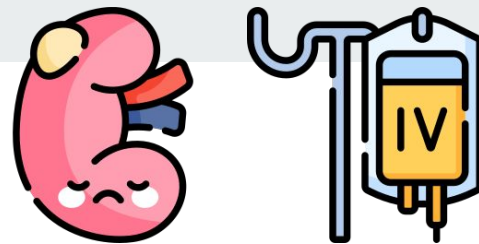
OPAT: Week 14

Started on **foscarnet** with stable renal function **at first**

- On **day 5** of therapy, creatinine increases by 0.4 mg/dL above baseline

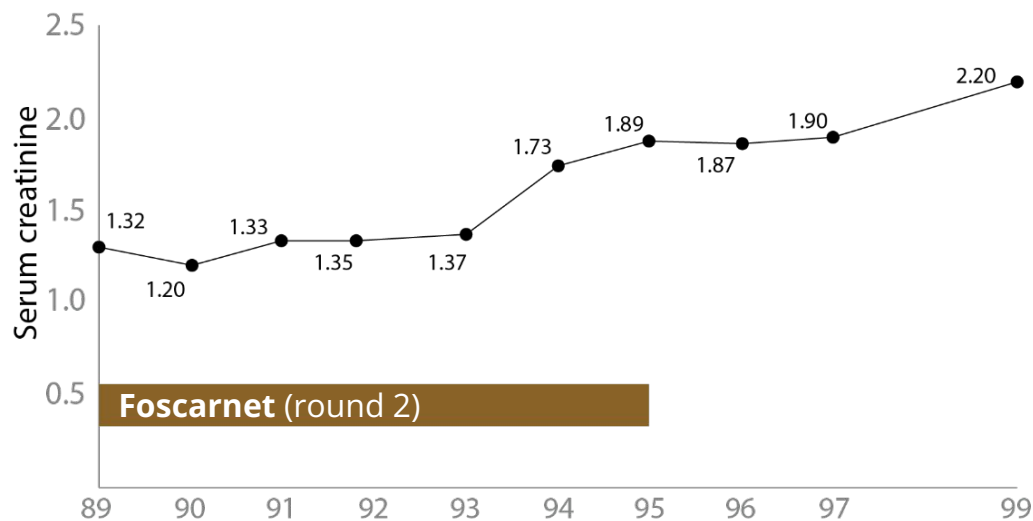


OPAT: Week 14



Started on **foscarnet** with stable renal function **at first**

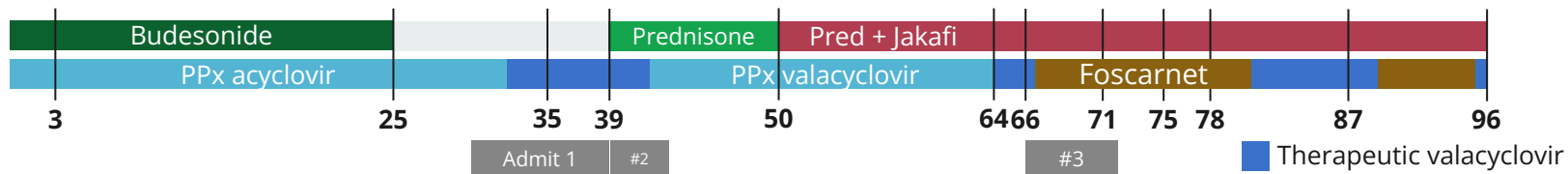
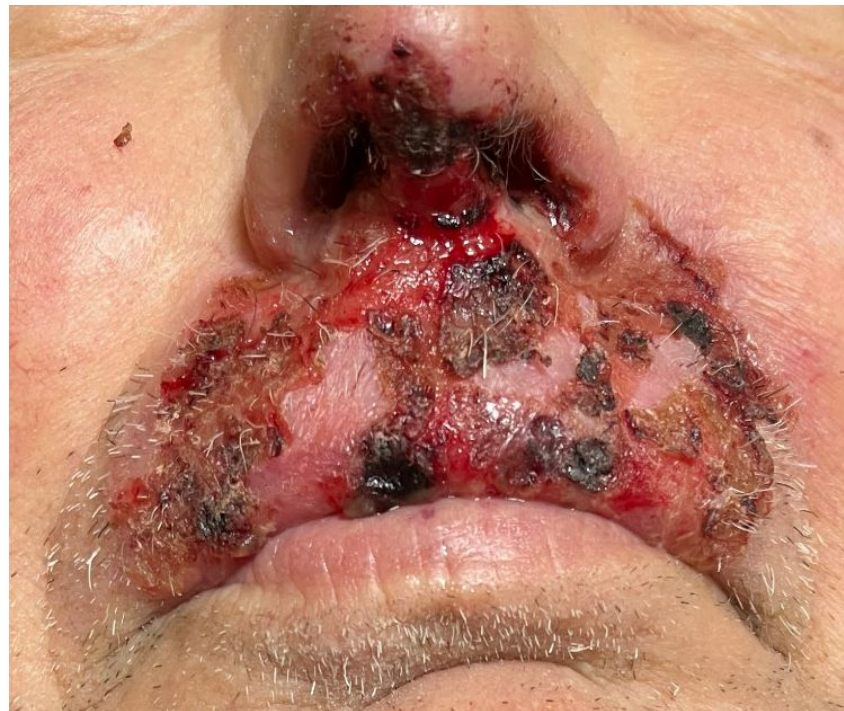- On **day 5** of therapy, creatinine increases by 0.4 mg/dL above baseline
- **Foscarnet held**



OPAT: Week 14 (day 96)

Started on **foscarnet** with stable renal function **at first**


- On **day 5** of therapy, creatinine increases by 0.4 mg/dL above baseline
- **Foscarnet held**
- By time of AKI, patient **did not have any improvement with second round** of foscarnet



Clinic: Week 15 (day 100)

Seen at next available clinic appointment

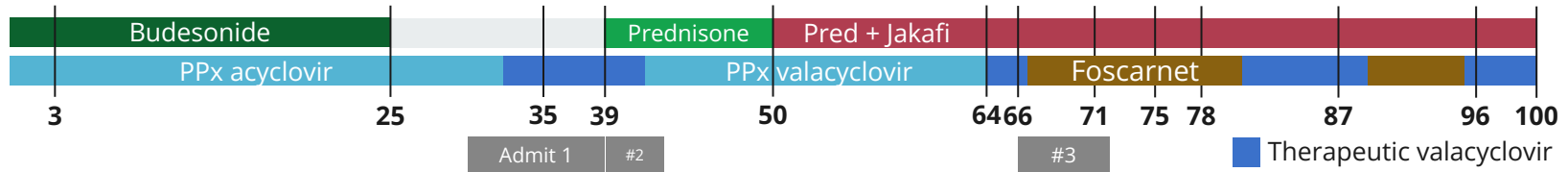
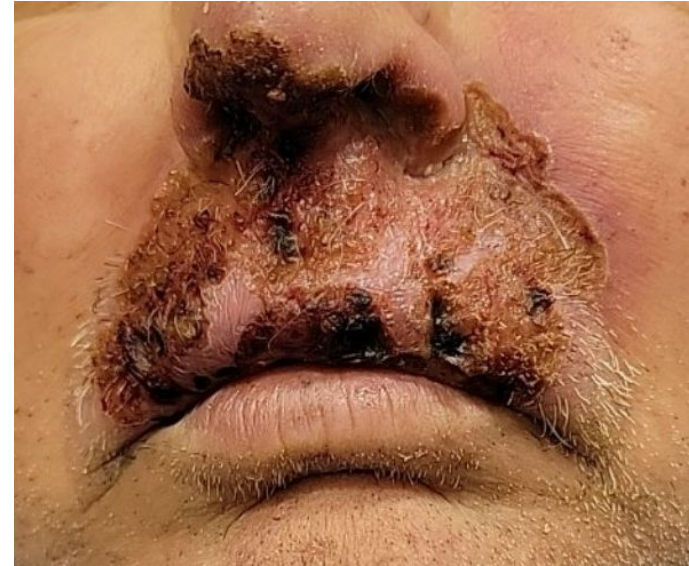- Lesions worsening
- Not eating



Clinic: Week 15 (day 100)

Seen at next available clinic appointment

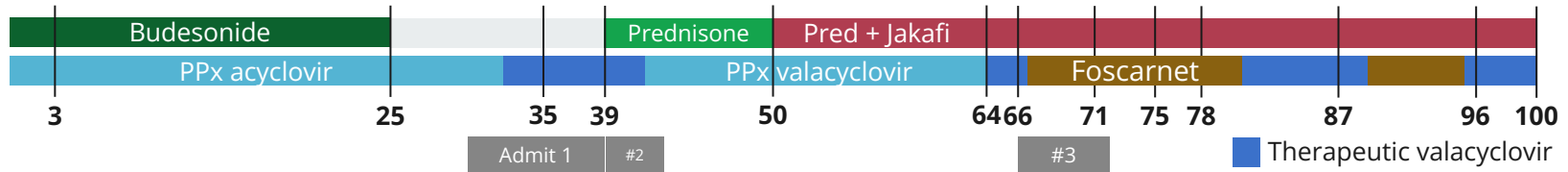
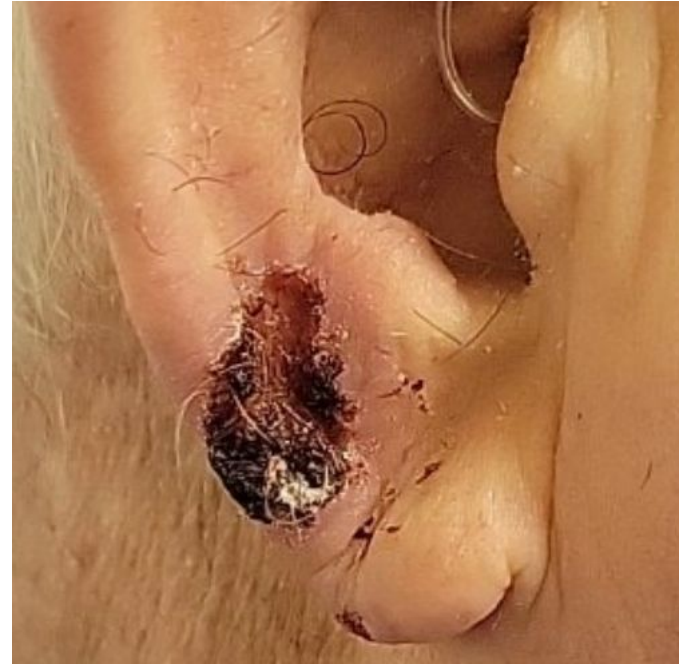- Lesions worsening
- Not eating



Clinic: Week 15 (day 100)

Seen at next available clinic appointment

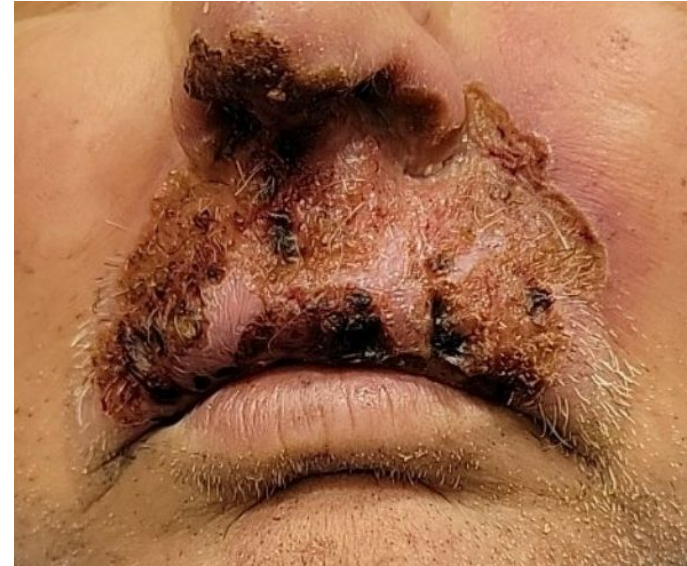
- Lesions worsening
- Not eating

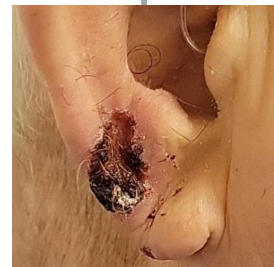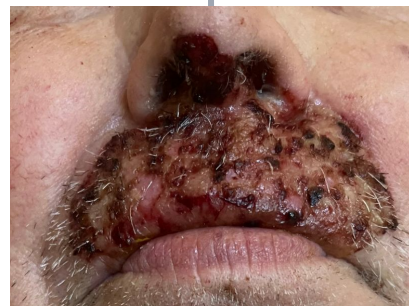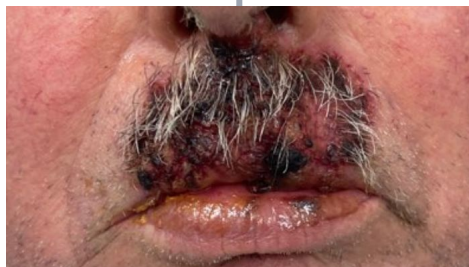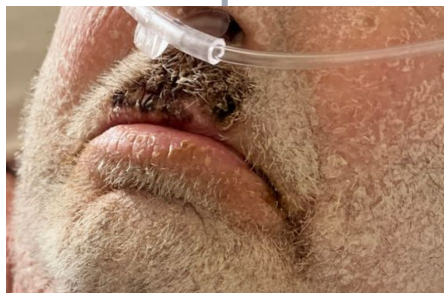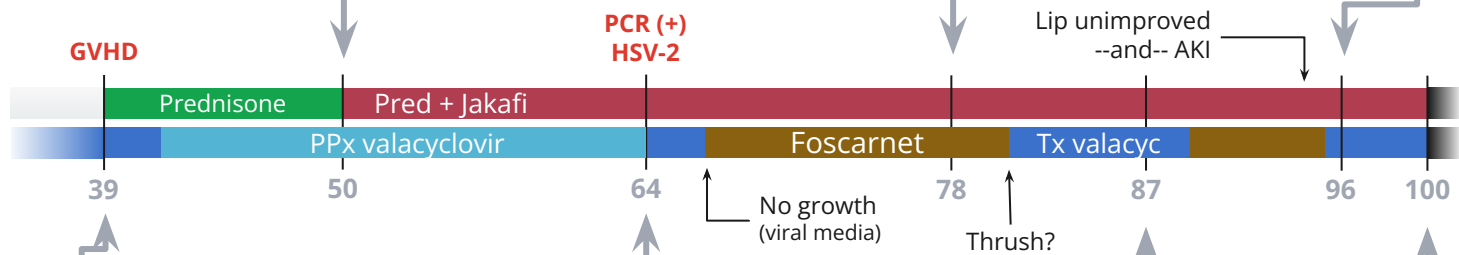


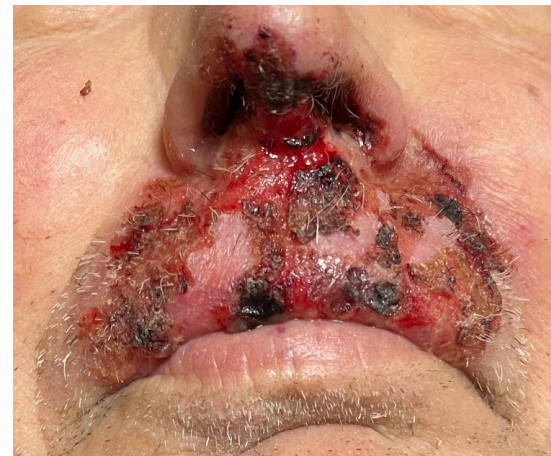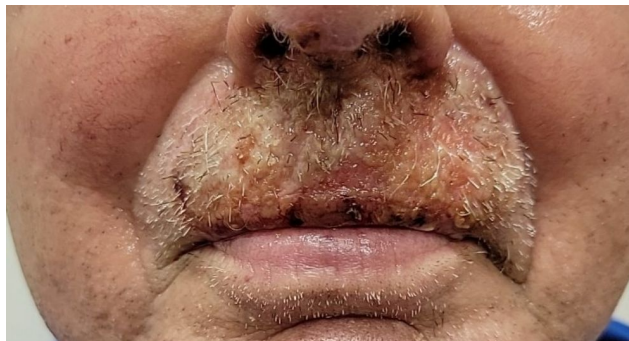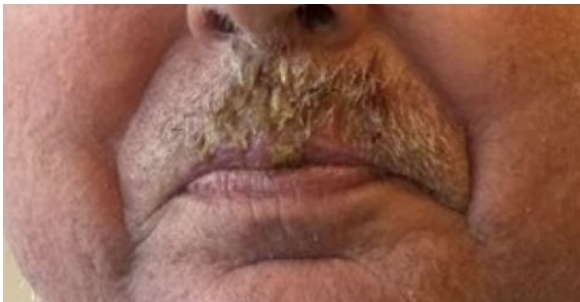Clinic: Week 15 (day 100)

Seen at next available clinic appointment

- Lesions worsening
- Not eating
- Still having thrush





**What would you
do?**

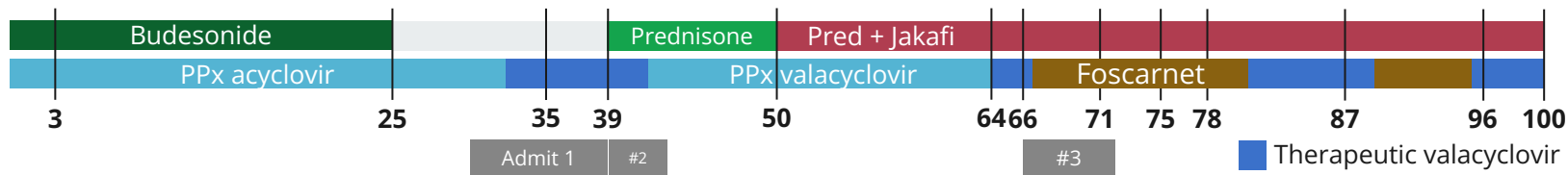
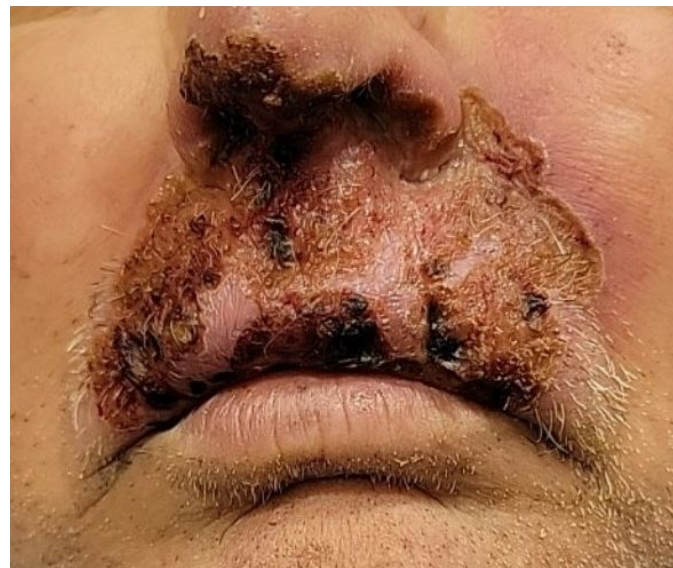Clinic: Week 15 (day 100)

Seen at next available clinic appointment

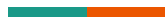- Lesions worsening
- Not eating

Recommendations

- Admit for coordination of care with nephrology
 - Possible IV acyclovir
- Derm consult for Bx
 - Viral Cx
 - Fungal / AFB
 - Path to look for other causes



Admission #4



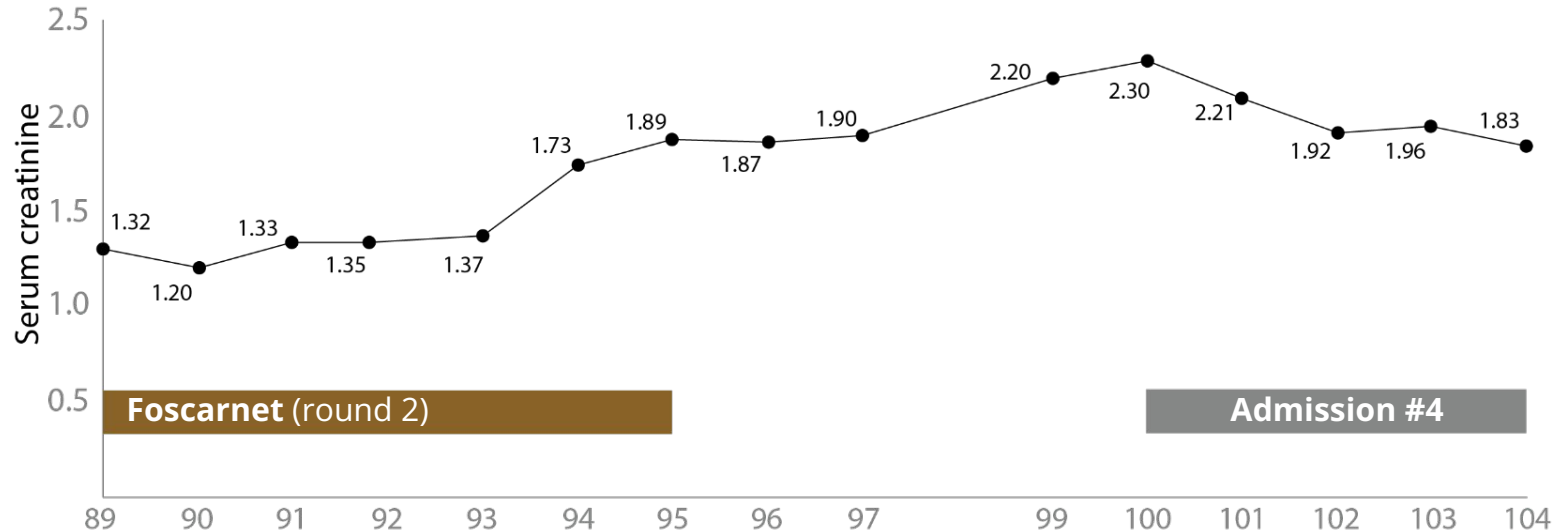
Generous IV fluids →



Admission #4



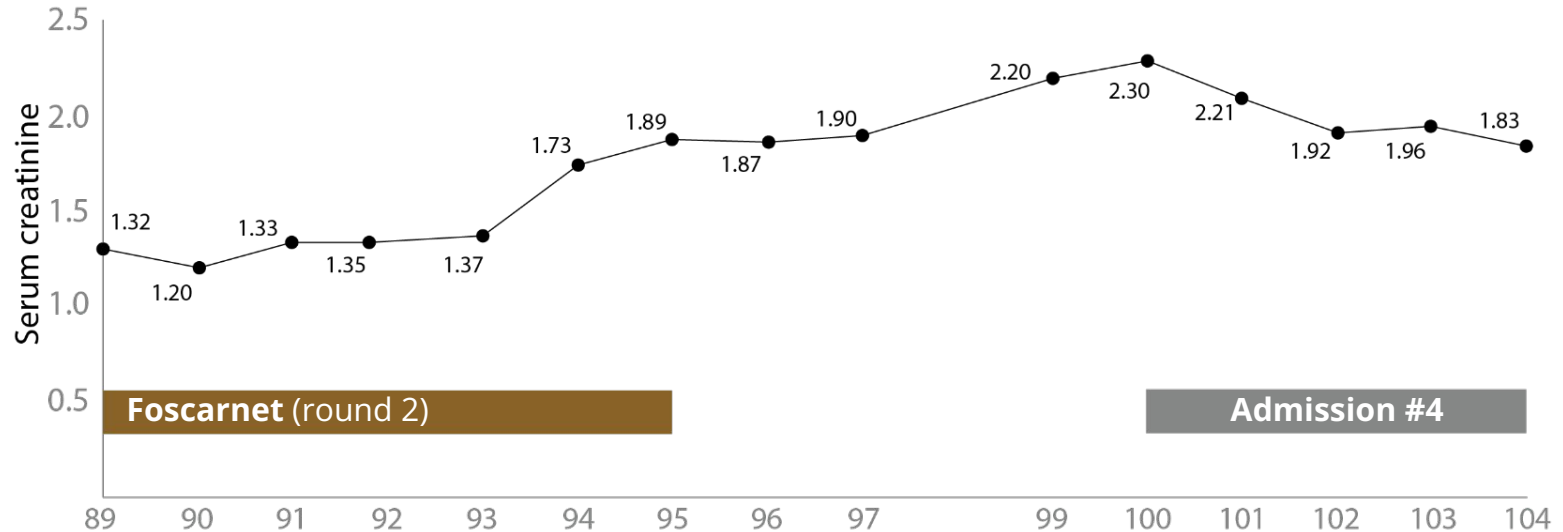
Generous IV fluids → **Still not much improvement** of renal fxn



Admission #4



Generous IV fluids → **Still not much improvement** of renal fxn → **risks** >> **benefits** of IV





Admission #4

Generous IV fluids → **Still not much improvement** of renal fxn → **risks >> benefits** of IV

- PCR:** Positive for HSV-2
- Negative for HSV-1



Admission #4

Generous IV fluids → **Still not much improvement** of renal fxn → **risks >> benefits** of IV

- PCR:** Positive for HSV-2
- Negative for HSV-1

Pathology report: Herpes folliculitis

Examination reveals a piece of skin with a **necrotic and ulcerated surface**. The underlying dermis reveals a dense **perifollicular mixed inflammatory infiltrate** with disruption and destruction of the follicles. **HSV1 and 2 immunohistochemical stain shows positive staining** within the follicular epithelium, supporting the above diagnosis. VZV and Gram stains are negative. Positive and negative controls stain as expected

Admission #4



Generous IV fluids → **Still not much improvement** of renal fxn → **risks >> benefits** of IV

- PCR:** Positive for HSV-2
- Negative for HSV-1

Viral culture (Quest)
Virus was isolated...

Pathology report: Herpes folliculitis

Examination reveals a piece of skin with a **necrotic and ulcerated surface**. The underlying dermis reveals a dense **perifollicular mixed inflammatory infiltrate** with disruption and destruction of the follicles. **HSV1 and 2 immunohistochemical stain shows positive staining** within the follicular epithelium, supporting the above diagnosis. VZV and Gram stains are negative. Positive and negative controls stain as expected

Admission #4



Generous IV fluids → **Still not much improvement** of renal fxn → **risks >> benefits** of IV

- PCR:** Positive for HSV-2
- Negative for HSV-1

Viral culture (Quest)

Virus was isolated... but Quest doesn't do susceptibilities should have gone to **ARUP**



Pathology report: Herpes folliculitis

Examination reveals a piece of skin with a **necrotic and ulcerated surface**. The underlying dermis reveals a dense **perifollicular mixed inflammatory infiltrate** with disruption and destruction of the follicles. **HSV1 and 2 immunohistochemical stain shows positive staining** within the follicular epithelium, supporting the above diagnosis. VZV and Gram stains are negative. Positive and negative controls stain as expected

Admission #4



Generous IV fluids → **Still not much improvement** of renal fxn → **risks >> benefits** of IV

- PCR:** Positive for HSV-2
- Negative for HSV-1

Viral culture (Quest)
Virus was isolated... but Quest
doesn't do susceptibilities
should have gone to **ARUP**



Viral culture, take 2 (ARUP)
POSITIVE for **Herpes Simplex
Virus**

Pathology report: Herpes folliculitis

Examination reveals a piece of skin with a **necrotic and ulcerated surface**. The underlying dermis reveals a dense **perifollicular mixed inflammatory infiltrate** with disruption and destruction of the follicles. **HSV1 and 2 immunohistochemical stain shows positive staining** within the follicular epithelium, supporting the above diagnosis. VZV and Gram stains are negative. Positive and negative controls stain as expected

Admission #4




Generous IV fluids → **Still not much improvement** of renal fxn → **risks >> benefits** of IV

- PCR:** Positive for HSV-2
- Negative for HSV-1

Viral culture (Quest)
Virus was isolated... but Quest
doesn't do susceptibilities
should have gone to **ARUP**



Viral culture, take 2 (ARUP)
POSITIVE for **Herpes Simplex**
Virus... for some reason
didn't reflex..?



Pathology report: Herpes folliculitis

Examination reveals a piece of skin with a **necrotic and ulcerated surface**. The underlying dermis reveals a dense **perifollicular mixed inflammatory infiltrate** with disruption and destruction of the follicles. **HSV1 and 2 immunohistochemical stain shows positive staining** within the follicular epithelium, supporting the above diagnosis. VZV and Gram stains are negative. Positive and negative controls stain as expected



Admission #4

Generous IV fluids → **Still not much improvement** of renal fxn → **risks >> benefits** of IV

Generally not the most productive admission

Pathology report: Herpes folliculitis

PCR: Positive for HSV-2



Admission #4

Generous IV fluids → **Still not much improvement** of renal fxn → **risks** >> **benefits** of IV

Generally not the most productive admission

- Didn't receive any IV antivirals

Pathology report: Herpes folliculitis

PCR: Positive for HSV-2

Admission #4



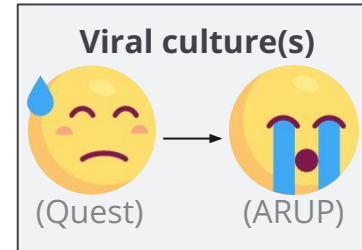
Generous IV fluids → **Still not much improvement** of renal fxn → **risks >> benefits** of IV

Generally not the most productive admission

- Didn't receive any IV antivirals
- Diagnostic testing was...frustrating

Pathology report: Herpes folliculitis

PCR: Positive for HSV-2



Admission #4

Generous IV fluids → **Still not much improvement** of renal fxn → **risks >> benefits** of IV

Generally not the most productive admission

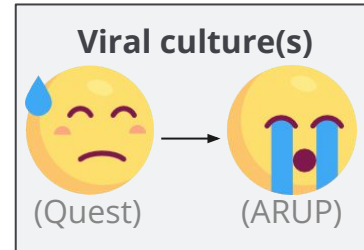
- Didn't receive any IV antivirals
- Diagnostic testing was...frustrating

Good news: Dermatology did get topical cidofovir approved!



Pathology report: Herpes folliculitis

PCR: Positive for HSV-2



Case 1: Discharge course

- Discharged from admission #4 on day 105
- Saw primary care on day 109

Case 1: Discharge course

- Discharged from admission #4 on day 105
- Saw primary care on day 109
 - Having nausea → Rx ondansetron (Zofran)

QT Interval	562	ms
QTC Calculation	627	ms

Case 1: Discharge course

- Discharged from admission #4 on day 105
- Saw primary care on day 109
 - Having nausea → Rx ondansetron (Zofran)
- Seen in ED the following day (day 110) for lethargy & encephalopathy

QT Interval	562	ms
QTC Calculation	627	ms

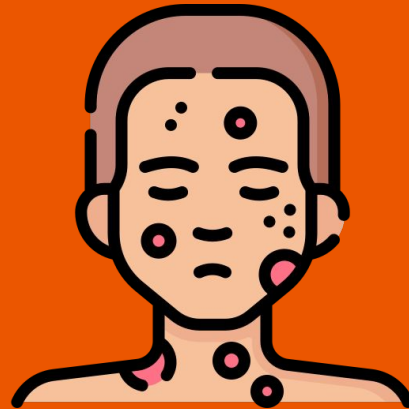
Case 1: Discharge course

- Discharged from admission #4 on day 105
- Saw primary care on day 109
 - Having nausea → Rx ondansetron (Zofran)
- Seen in ED the following day (day 110) for lethargy & encephalopathy
- Shortly after returning from CT head (normal) → seizure-like activity
 - 4mg IV lorazepam (Ativan) → another seizure

Case 1: Discharge course

- Discharged from admission #4 on day 105
- Saw primary care on day 109
 - Having nausea → Rx ondansetron (Zofran)
- Seen in ED the following day (day 110) for lethargy & encephalopathy
- Shortly after returning from CT head (normal) → seizure-like activity
 - 4mg IV lorazepam (Ativan) → another seizure
 - Another lorazepam (Ativan) → apnea → bradycardia → PEA arrest
- ACLS (x2) → family called code off

Discussion



Links to articles discussed
here

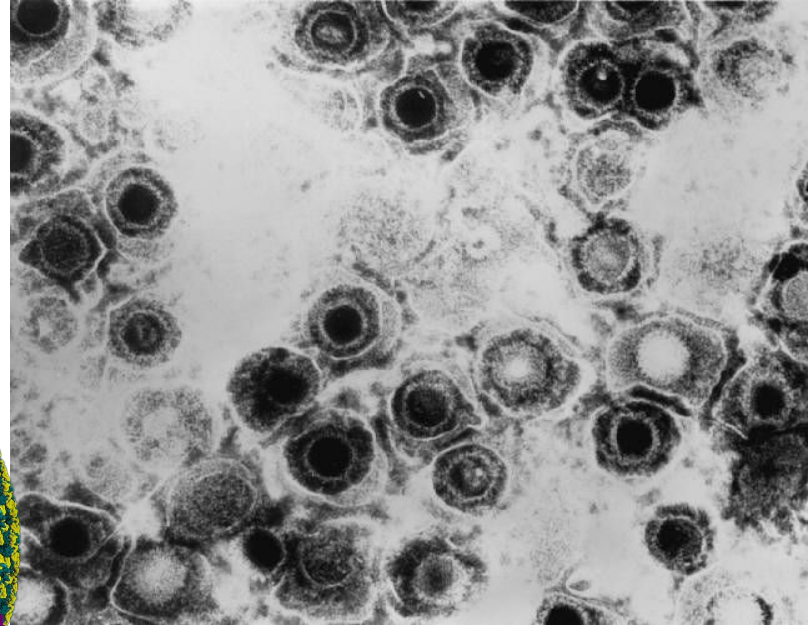
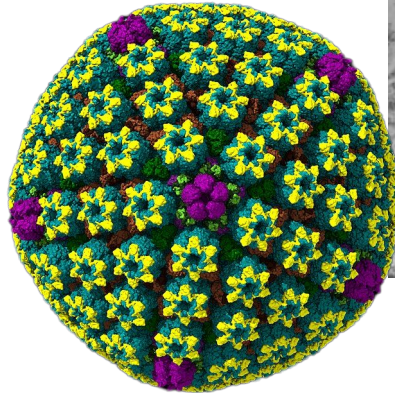


Learning objectives

- Identify the **antivirals used in the treatment of HSV** and their potential **mechanisms of resistance**
 - Including **TK deficient HSV**
- Discuss **newer candidates** for the treatment of HSV
- **A trip to the kitchen...**

Herpes simplex virus

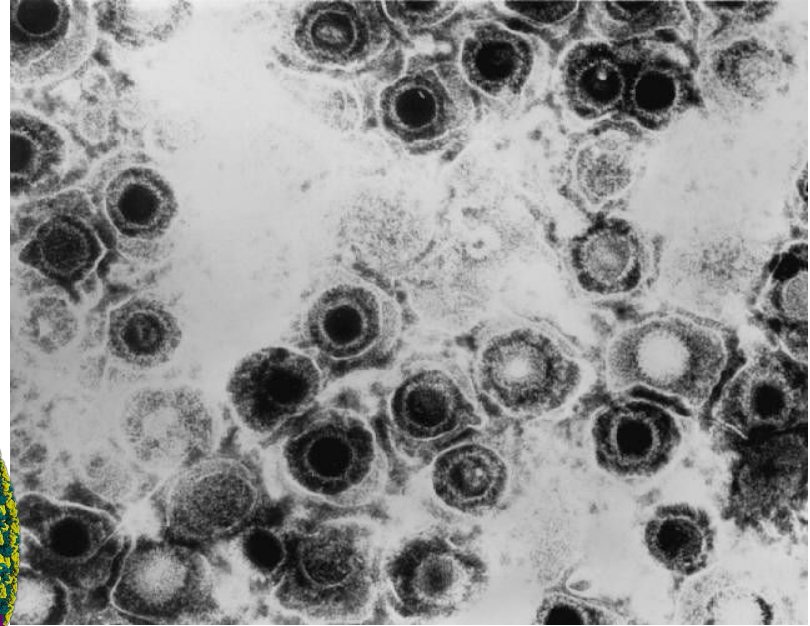
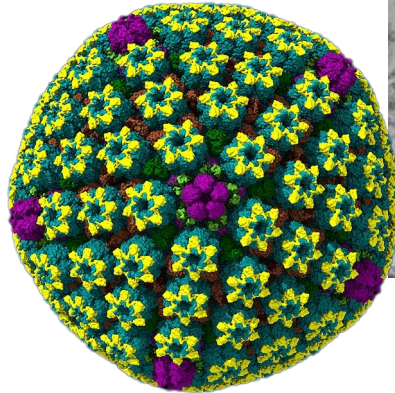
- Enveloped dsDNA virus
- Viral genome of ~15,000 base pairs
 - One of the better studied viruses



Wikipedia: Herpes simplex virus

Herpes simplex virus

- Enveloped dsDNA virus
- Viral genome of ~15,000 base pairs
 - One of the better studied viruses
- Virus encodes key machinery used in viral life cycle (unique long regions; UL)
 - **UL30**: DNA polymerase
 - **UL23**: Thymidine kinase
 - **UL8**: DNA helicase

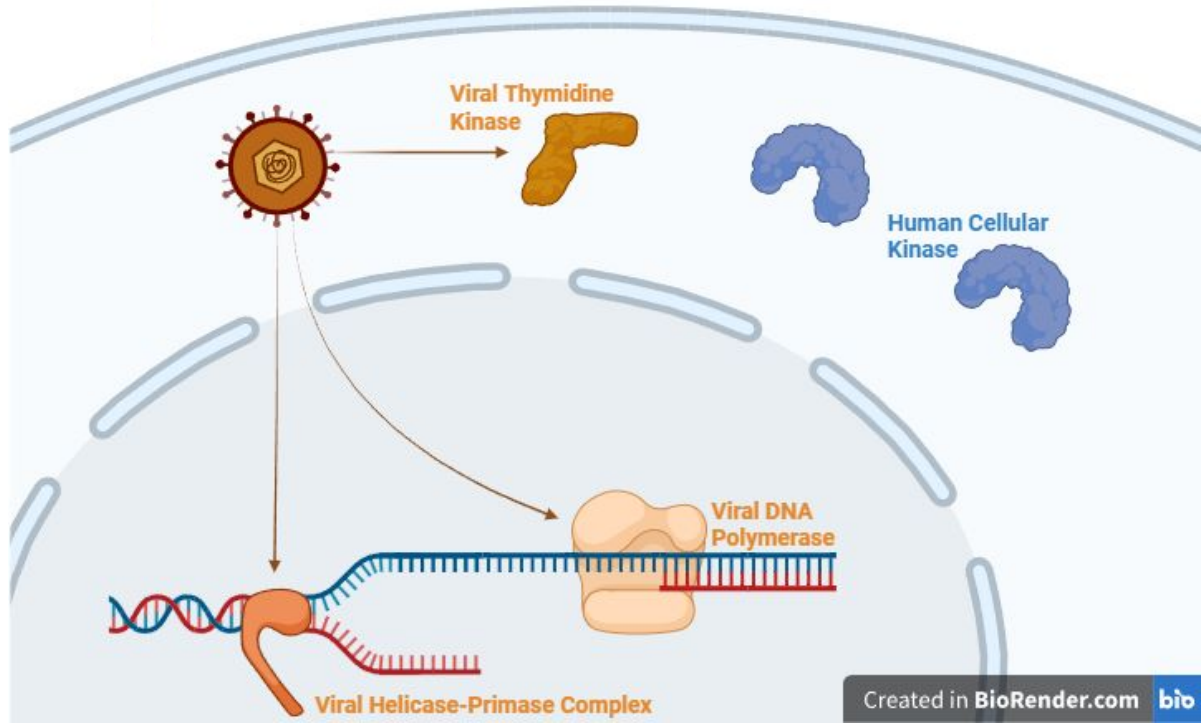


Wikipedia: Herpes simplex virus

HSV lifecycle [1][2]

Key unique long (UL) regions

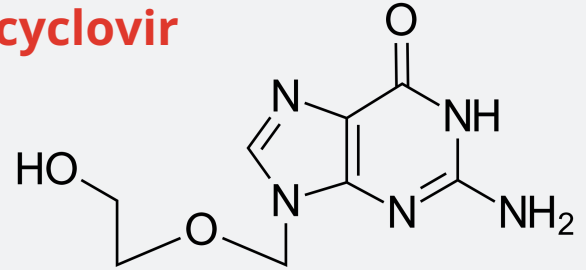
- **UL30**: DNA polymerase
- **UL23**: Thymidine kinase
- **UL8**: DNA helicase



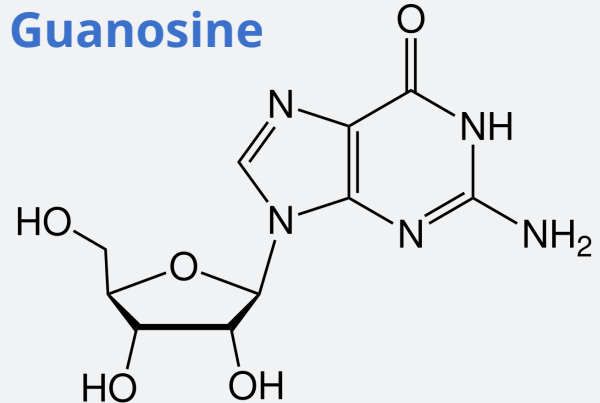
Mechanism of acyclovir

Acyclovir is the **prodrug** of a (guanosine) **nucleoside analogue**

Acyclovir



Guanosine

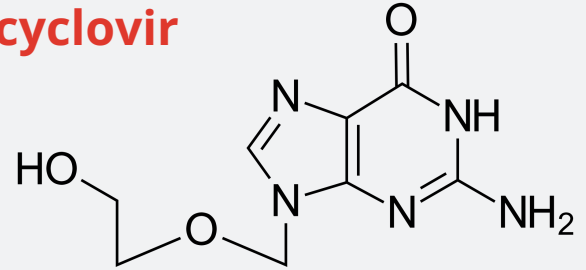


Mechanism of acyclovir

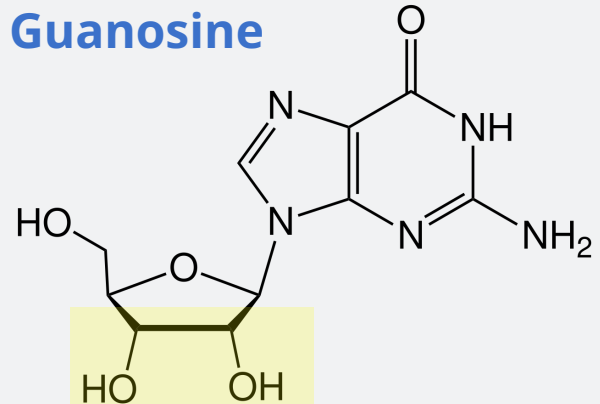
Acyclovir is the **prodrug** of a (guanosine) **nucleoside analogue**

- **Active version** (acyclovir triphosphate, AKA acyclo-GTP) **lacks the 3'-OH group** → **halts DNA replication**

Acyclovir



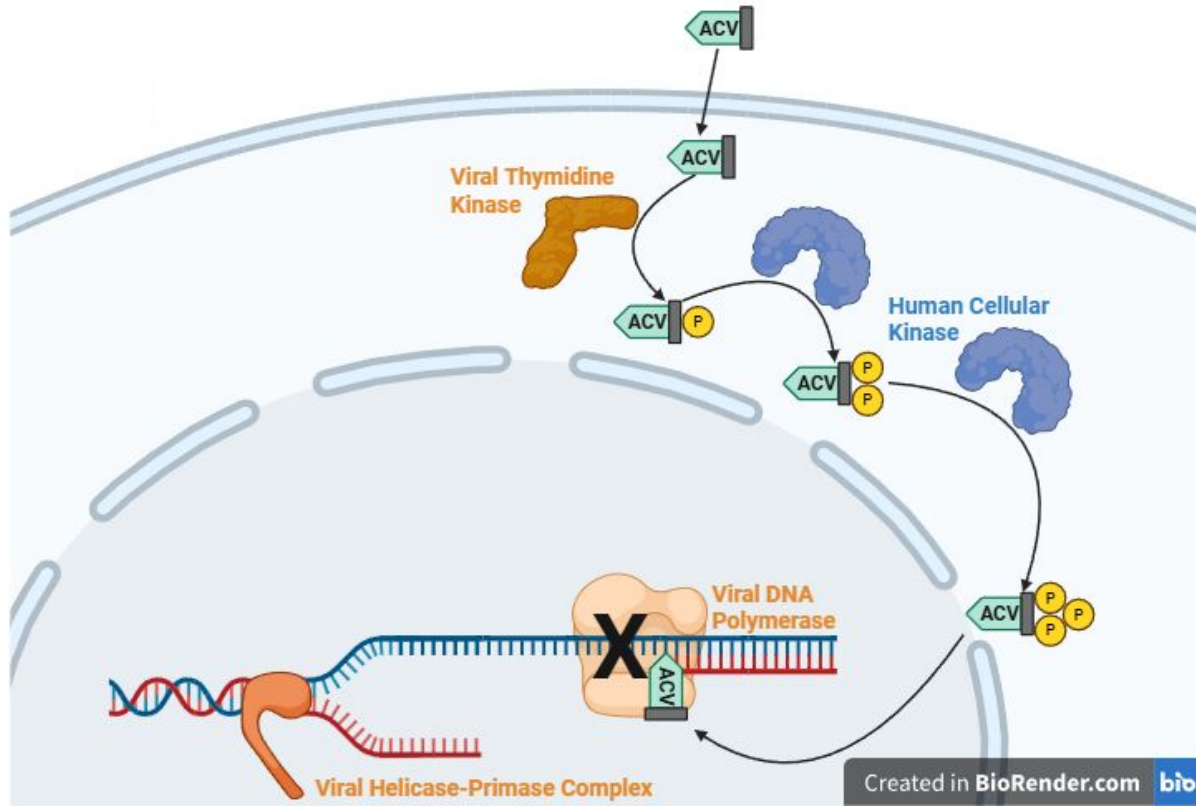
Guanosine



Mechanism of acyclovir [2]

Acyclovir is the **prodrug** of a **nucleoside analogue**

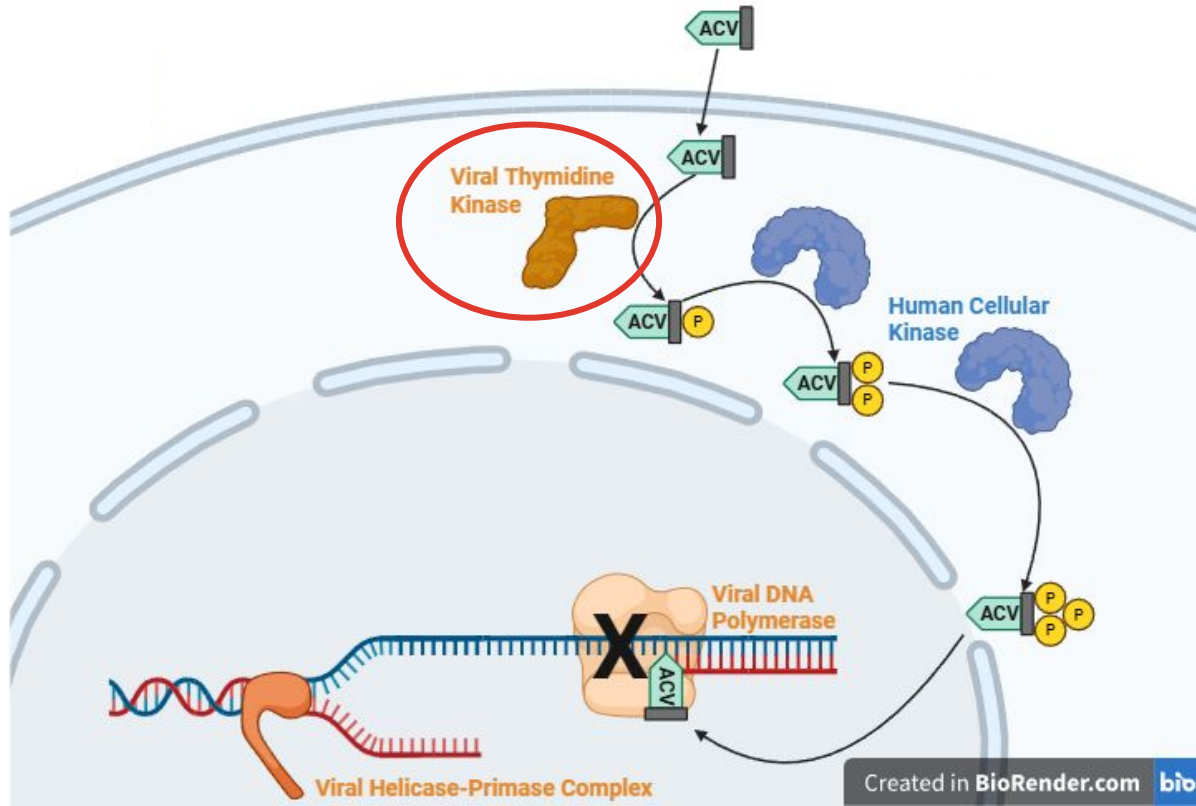
- To be converted into active version, **must be phosphorylated** (three times)



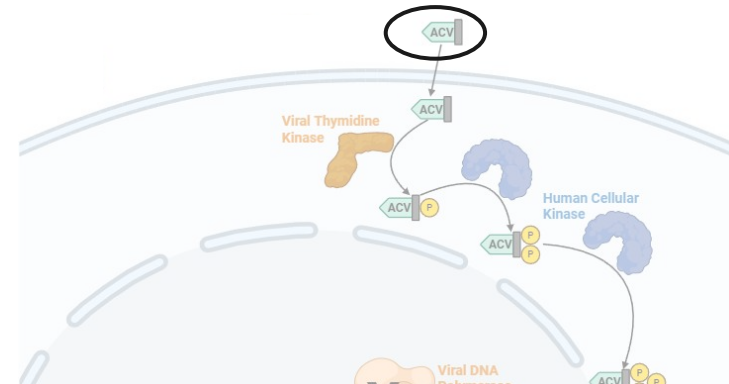
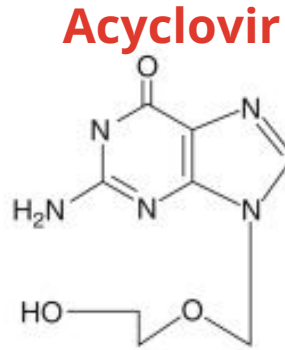Mechanism of acyclovir [2]

Acyclovir is the **prodrug** of a **nucleoside analogue**

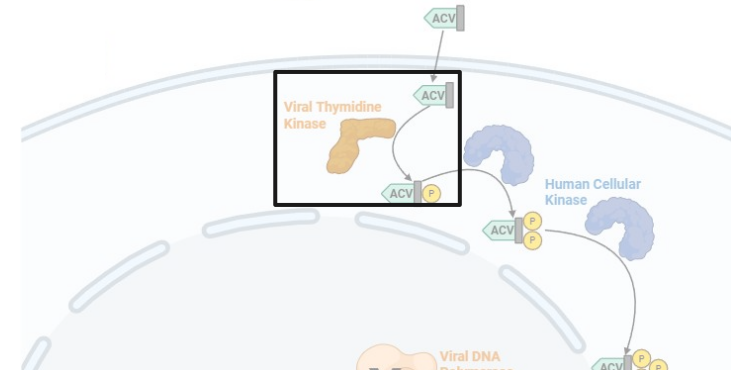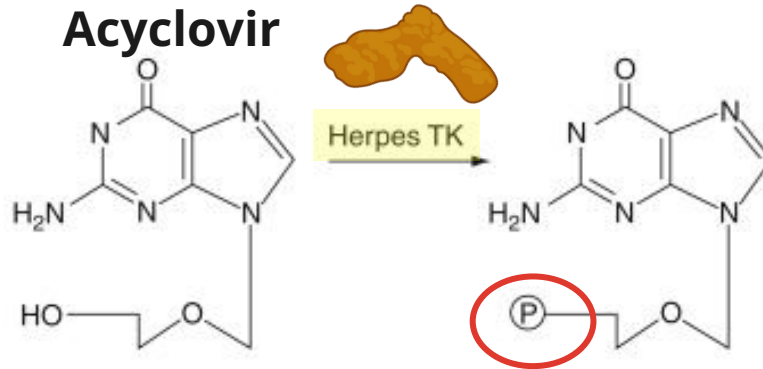
- To be converted into active version, **must be phosphorylated** (three times)
- First phosphorylation is done by the **viral thymidine kinase**



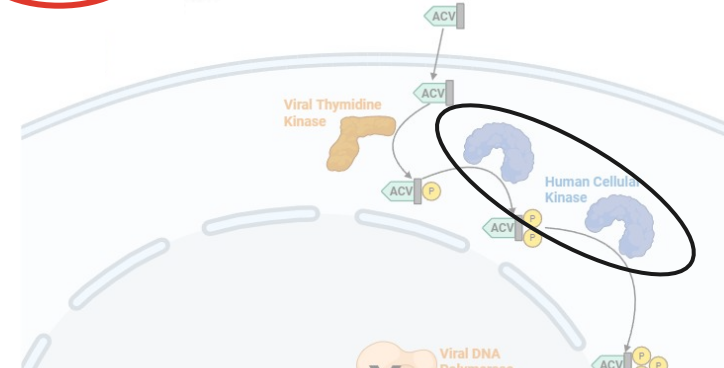
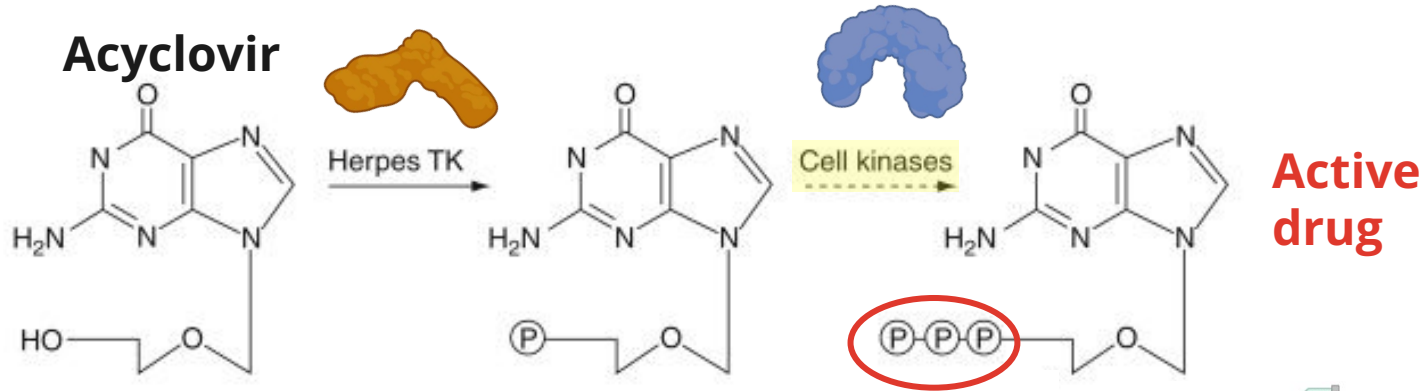
Molecular mechanism of acyclovir



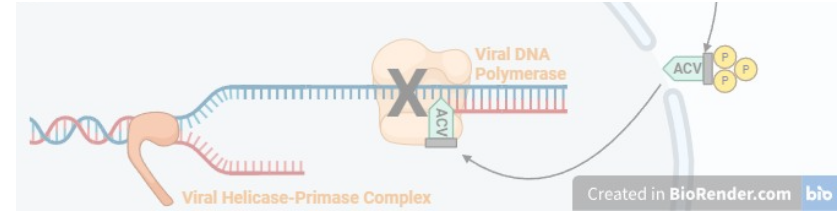
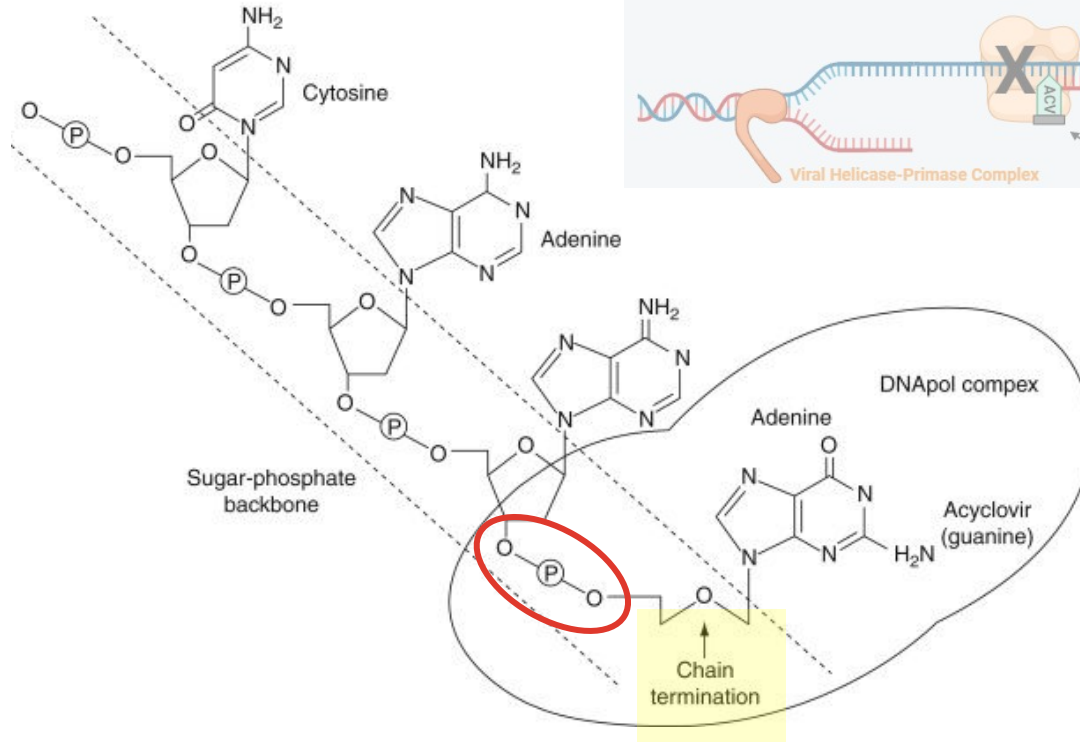
Molecular mechanism of acyclovir



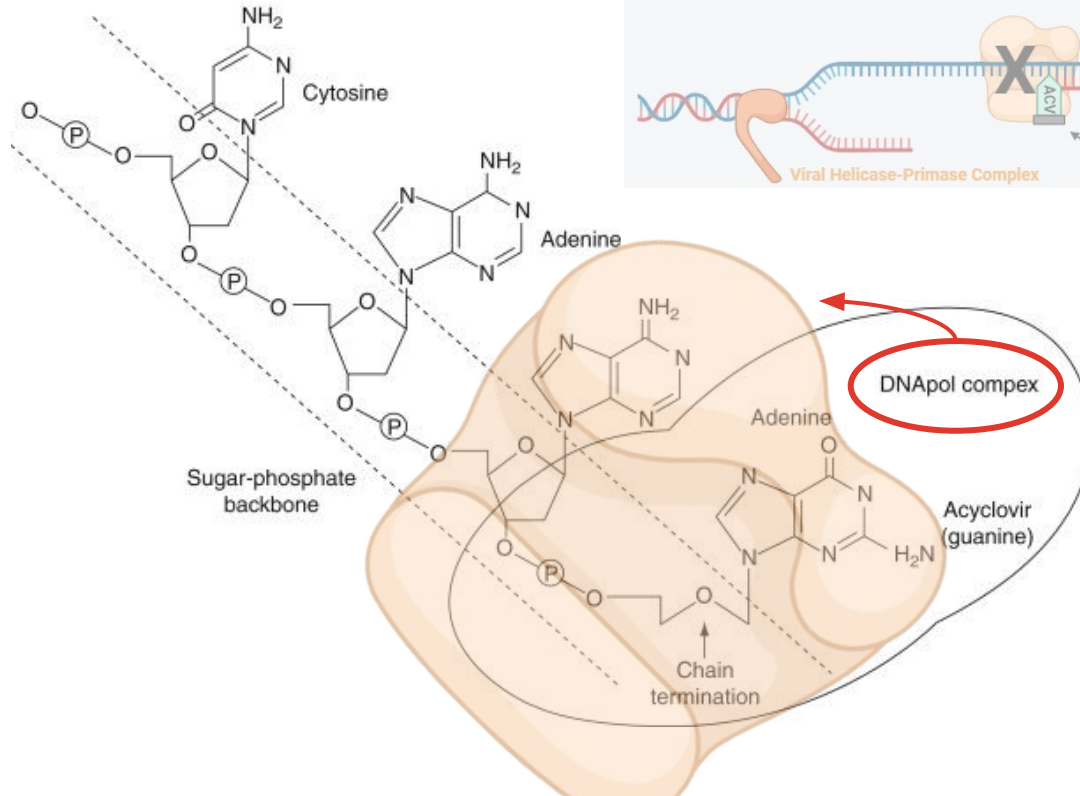
Molecular mechanism of acyclovir



Halting DNA replication (no 3'-OH group)

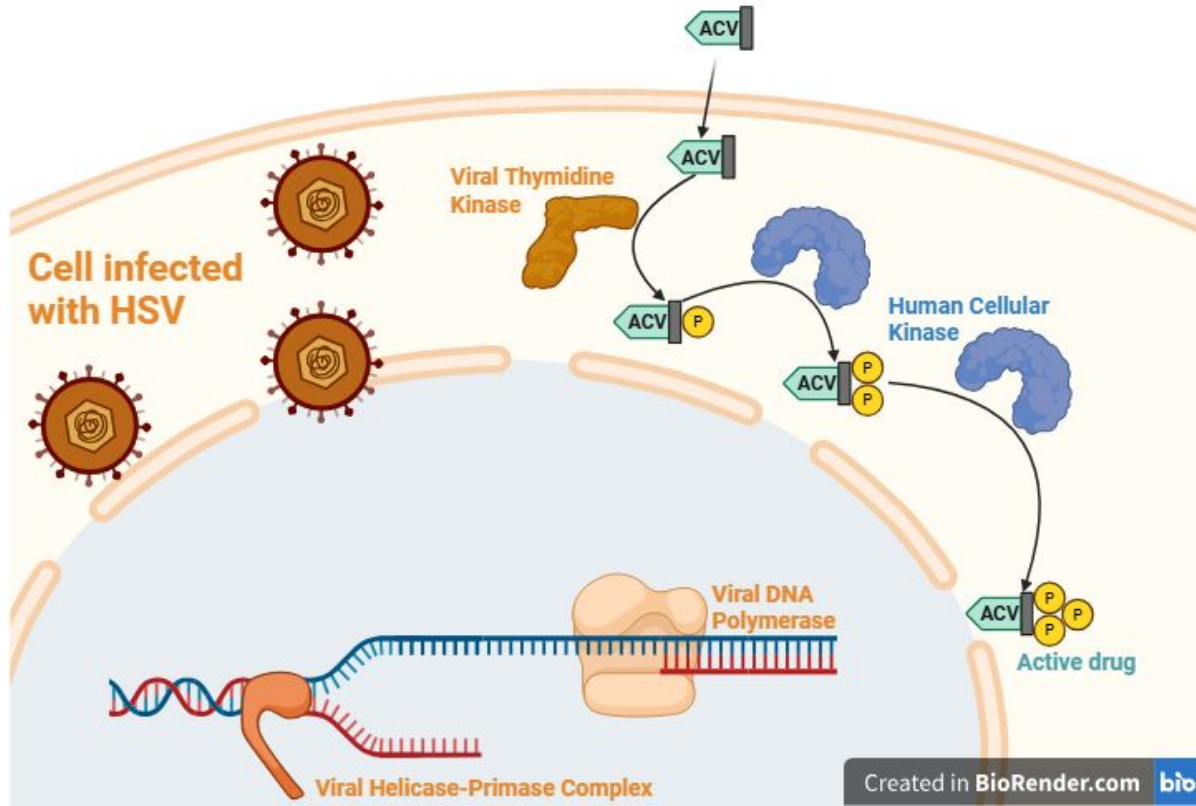


Halting DNA replication (no 3'-OH group)



Acyclovir's selectivity

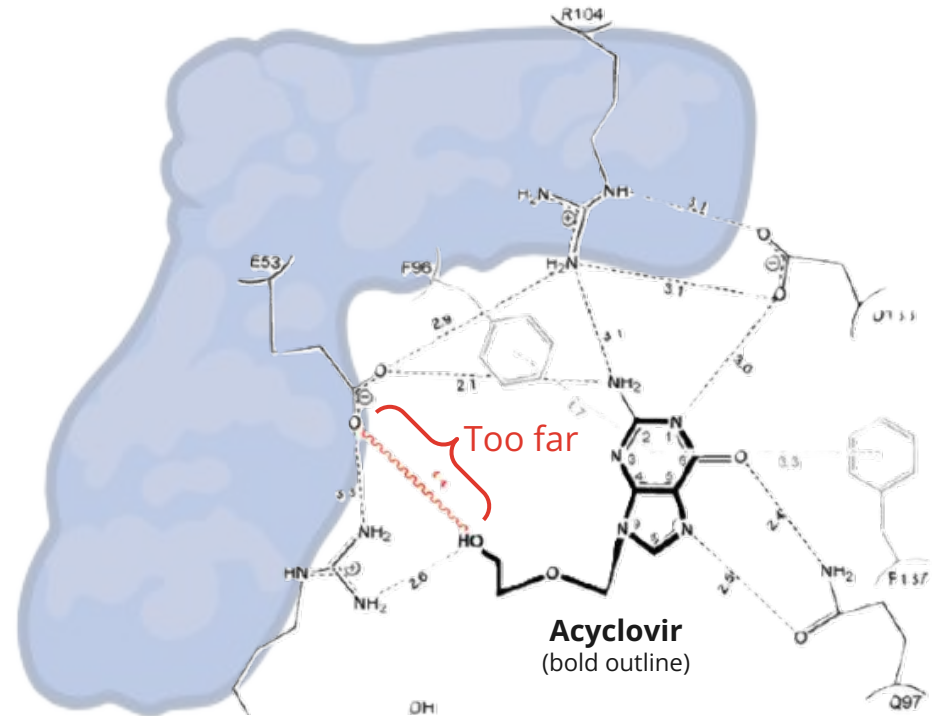
Acyclovir has a much **higher affinity for viral TK** than for the **human analog** (dCK) [3]



Acyclovir's selectivity [3]

Acyclovir has a much **higher affinity for viral TK** than for the **human analog (dCK)** [3]

- Binds to both, but **acyclic sugar** prevents dCK from being able to phosphorylate

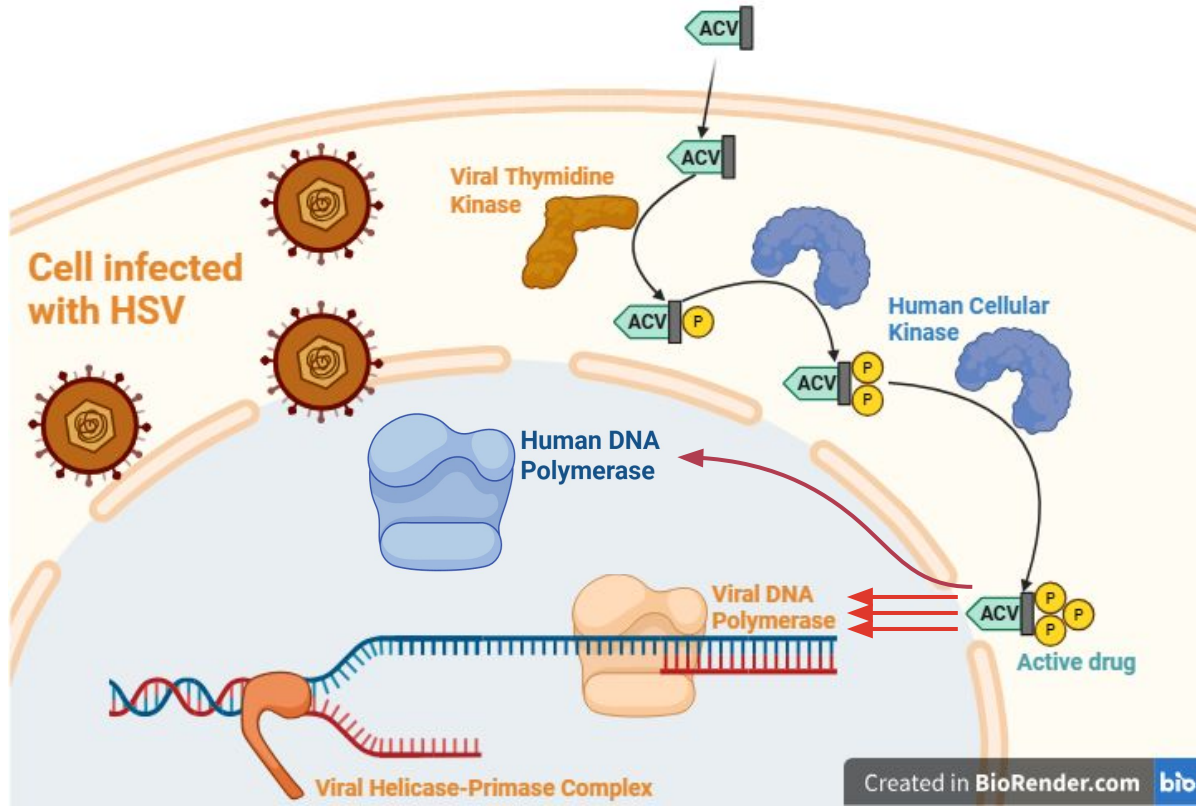


Acyclovir's selectivity

Acyclovir has a much **higher affinity for viral TK** than for the **human analog** (dCK) [3]

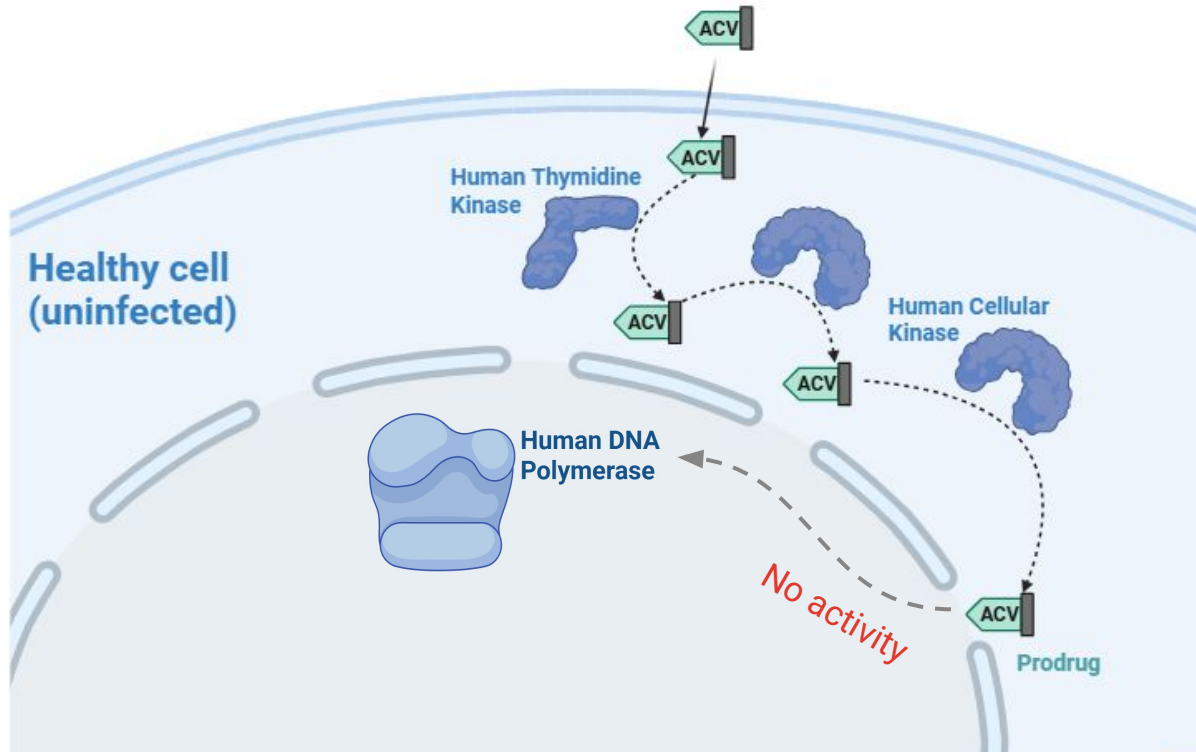
Acyclovir triphosphate (**active drug**) also *prefers* **viral DNA pol**, but is **not selective** (so still binds with human DNA pol) [4]

- Mainly mentioning this because this paper [4] was from my undergrad biochem professor



Acyclovir's selectivity [3][4]

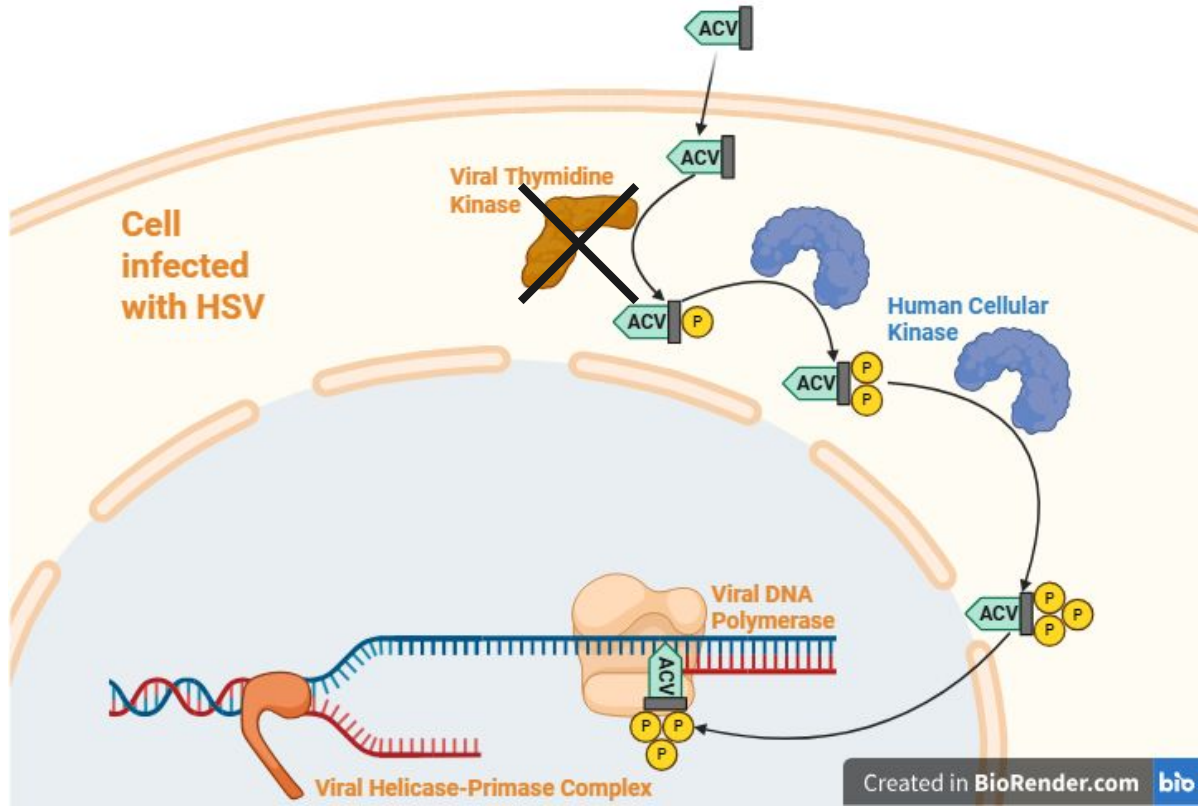
Key point: Acyclovir has a favorable **toxicity profile** because it only becomes active in **virally infected cells**, which express **viral TK**



TK deficient HSV

Key point: Acyclovir has a favorable **toxicity profile** because it only becomes active in **virally infected cells**, which express **viral-TK**

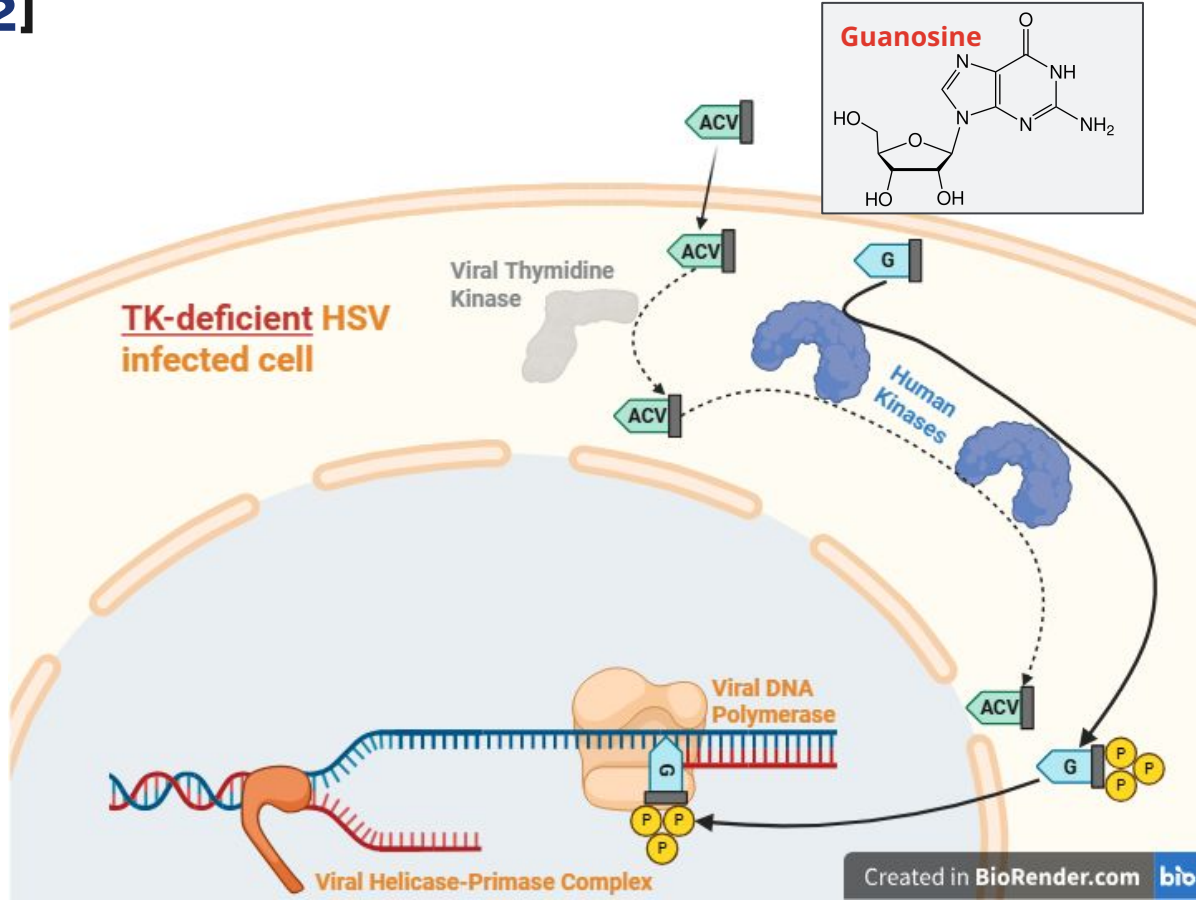
What if the virus does not make viral TK?



TK deficient HSV [2]

For strains of the virus that do not produce HSV thymidine kinase:

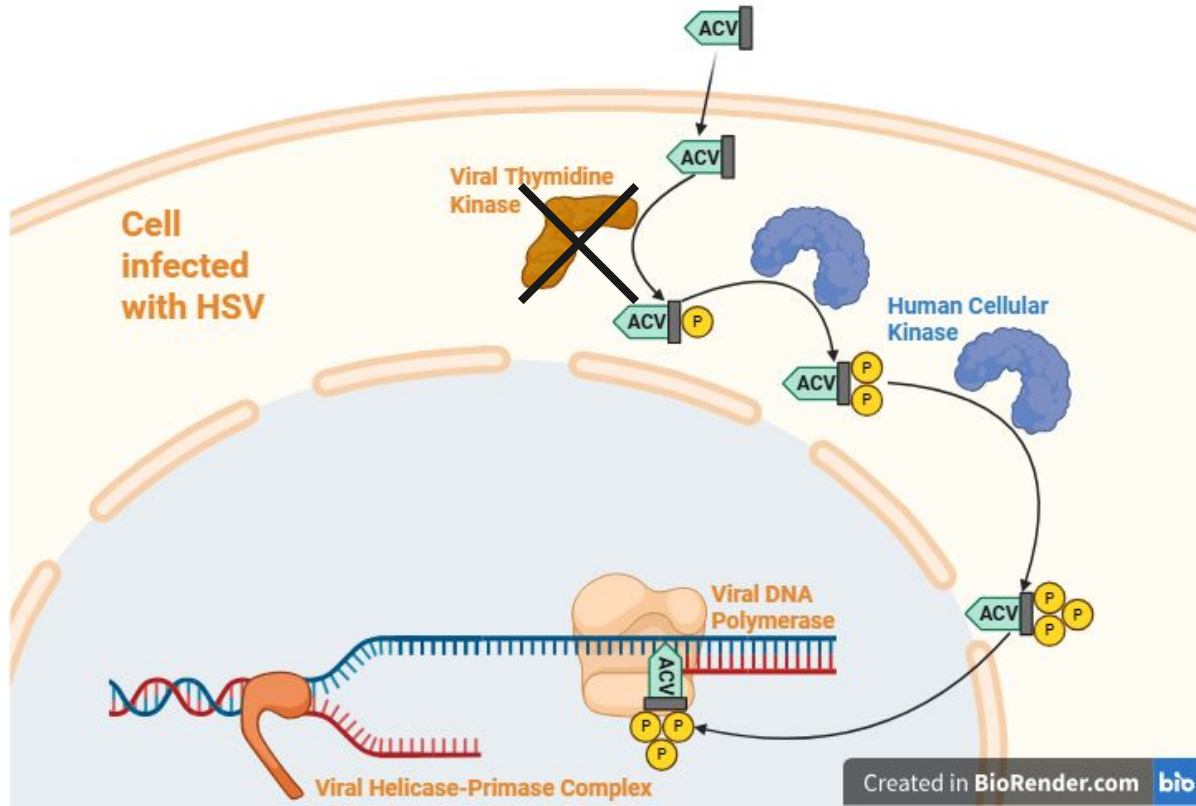
- Acyclovir **cannot be activated** (to acyclo-GTP)
- Thus no therapeutic effect



TK deficient HSV[7]

Rates of acyclovir resistant HSV may be **10 times higher** in immunocompromised hosts

- Between **1 in 25** to **1 in 10**



TK deficient HSV

Rates of acyclovir resistant HSV may be **10 times higher** in immunocompromised hosts

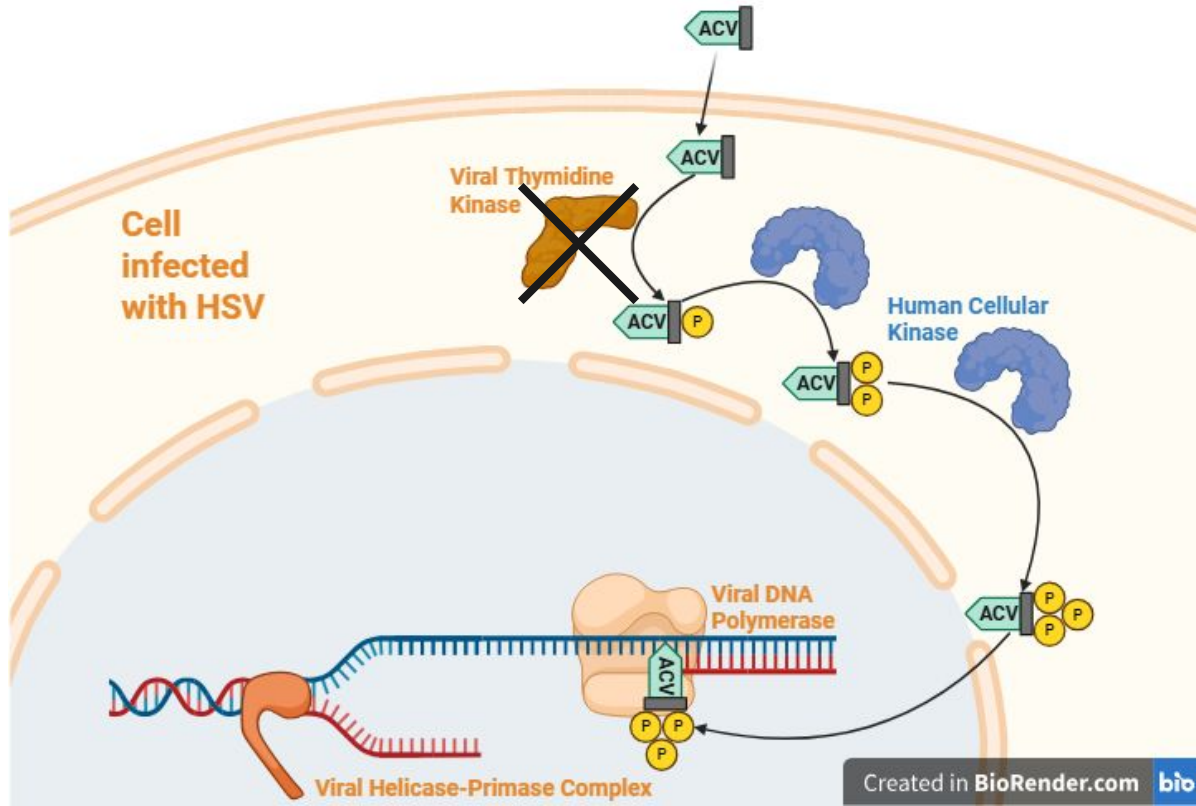
- Between **1 in 25** to **1 in 10**

Impaired host responses →

Less pathogenic viral strains able to survive →

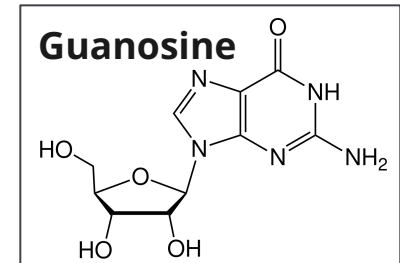
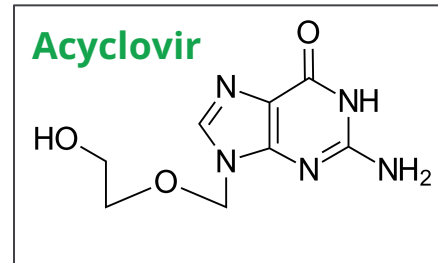
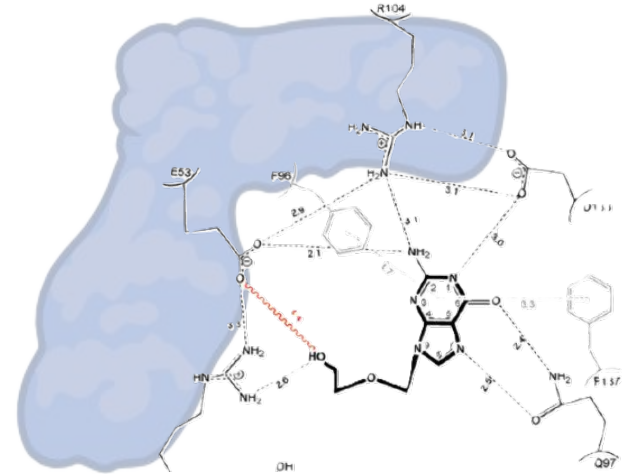
Selective pressure →

Emergence of resistant strains



What about ganciclovir? [2][3]

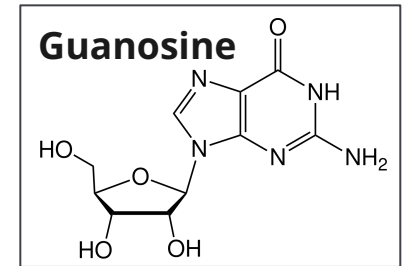
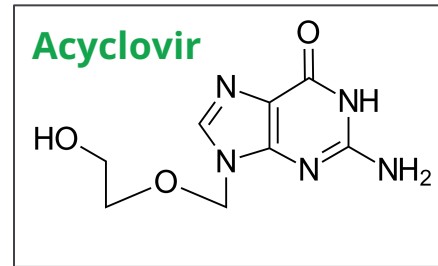
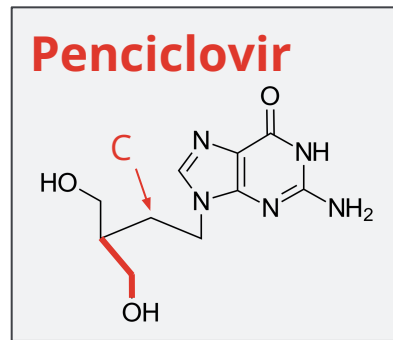
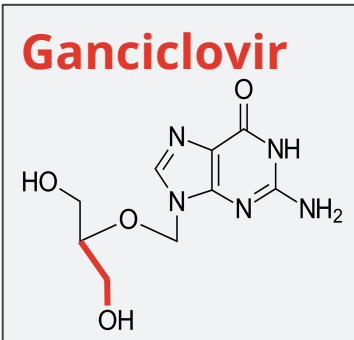
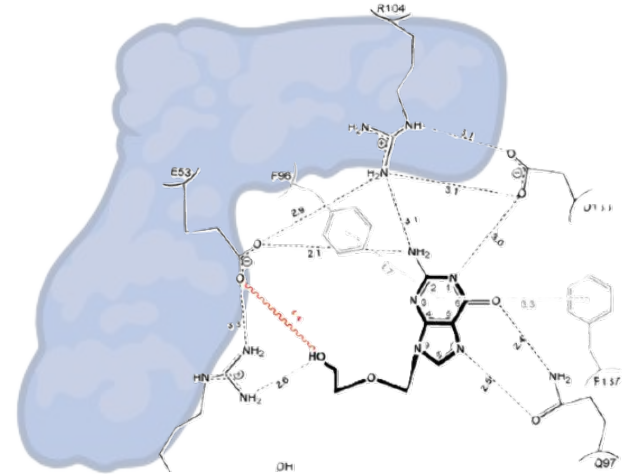
All of the nucleoside analogues rely on **viral kinases** to complete first phosphorylation



What about ganciclovir? [2][3]

All of the nucleoside analogues rely on **viral kinases** to complete first phosphorylation

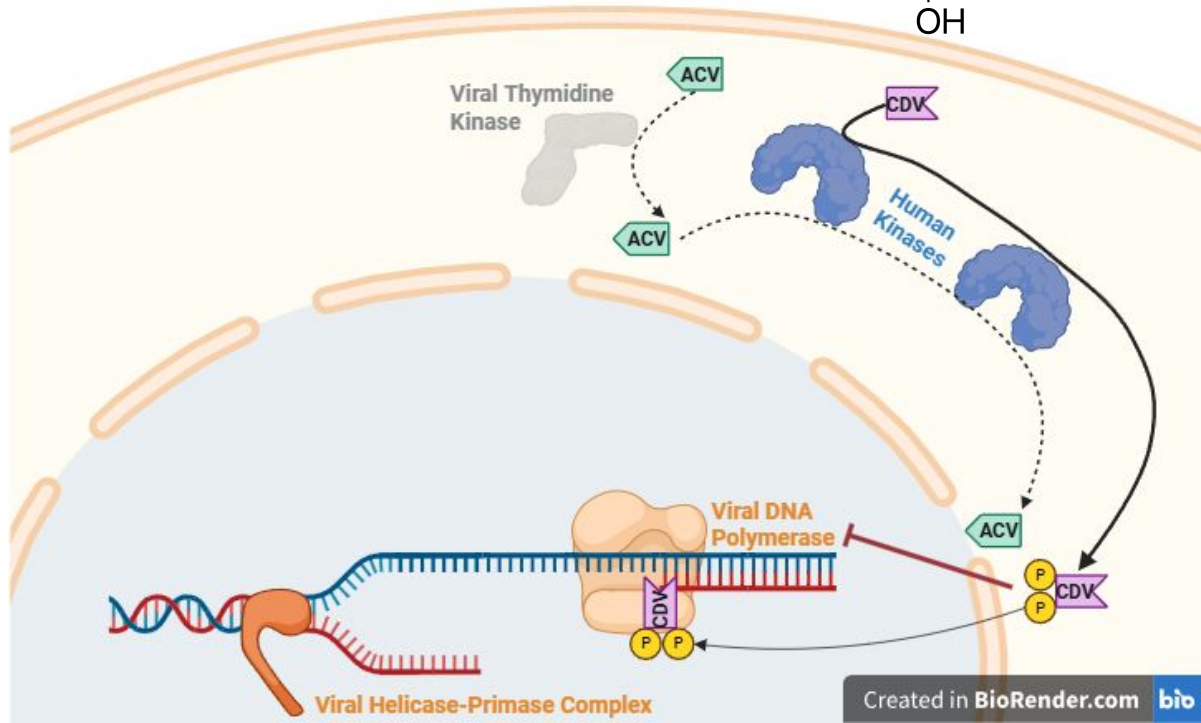
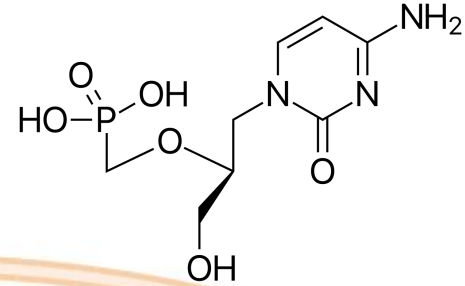
TK deficiency → **none of these will work**



Cidofovir

Nucleotide analog (meaning it already has one phos on it)

- Does **not** need viral kinases to become active



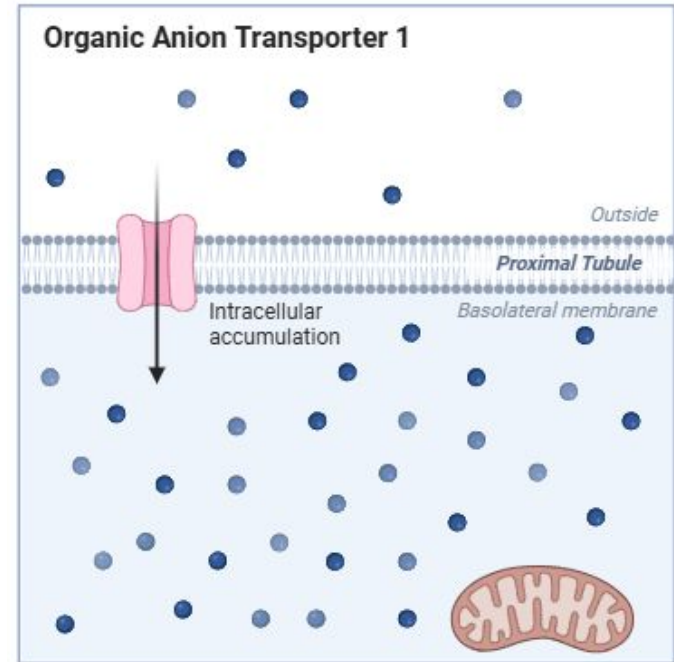
Cidofovir [5]

Nucleotide analog (meaning it already has one phos on it)

- Does **not** need viral kinases to become active

But can be **toxic** to human cells, namely the **kidneys**

- Increased uptake via **OAT1** → mitochondrial toxicity



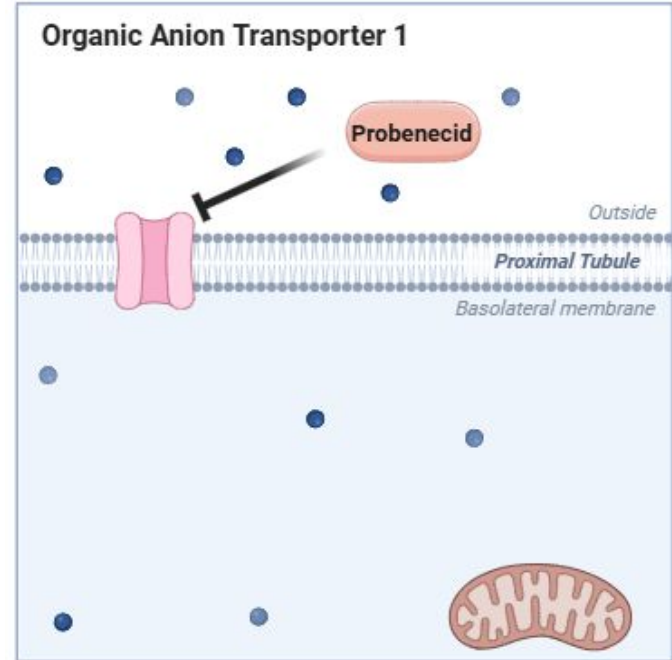
Cidofovir [5]

Nucleotide analog (meaning it already has one phos on it)

- Does **not need** viral **kinases** to become active

But can be **toxic** to human cells, namely the **kidneys**

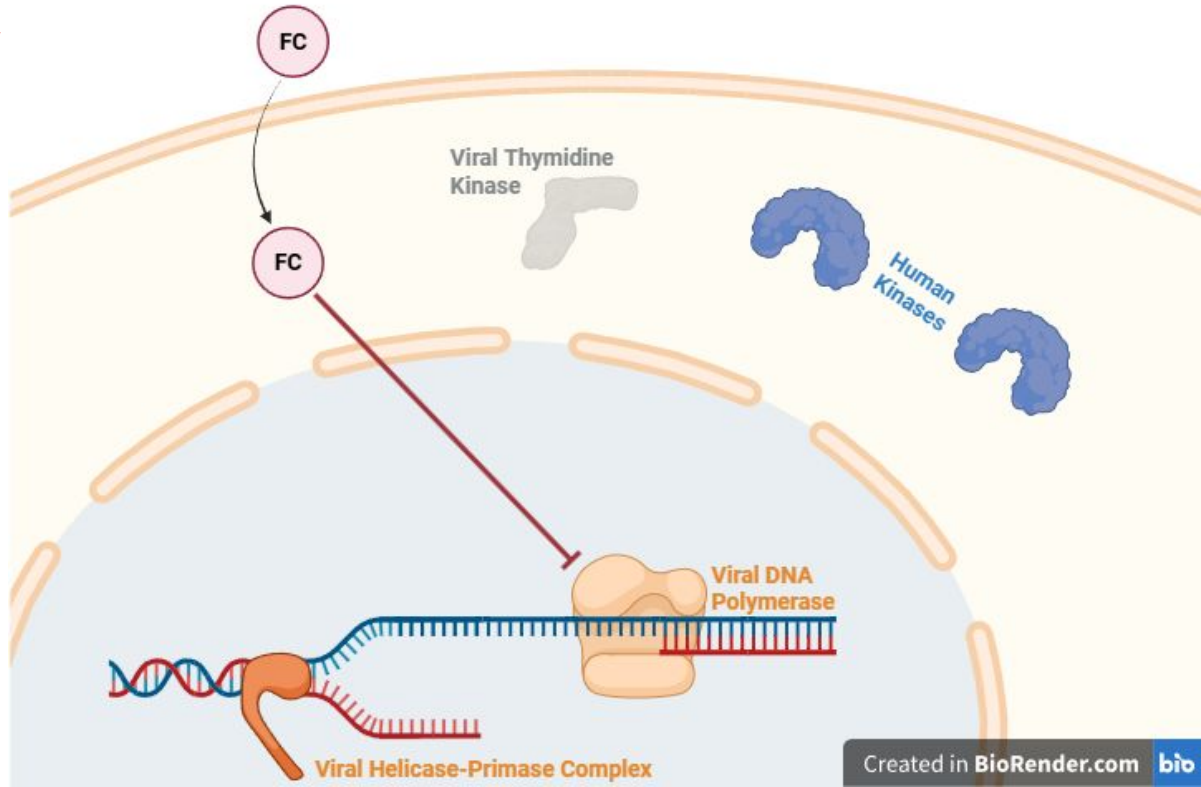
- Increased uptake via **OAT1** → mitochondrial toxicity
- Administer with **probenecid**



Foscarnet

Pyrophosphate analog → **directly inhibits DNA polymerase**

- Prevents binding of deoxynucleotide triphosphates to DNA pol

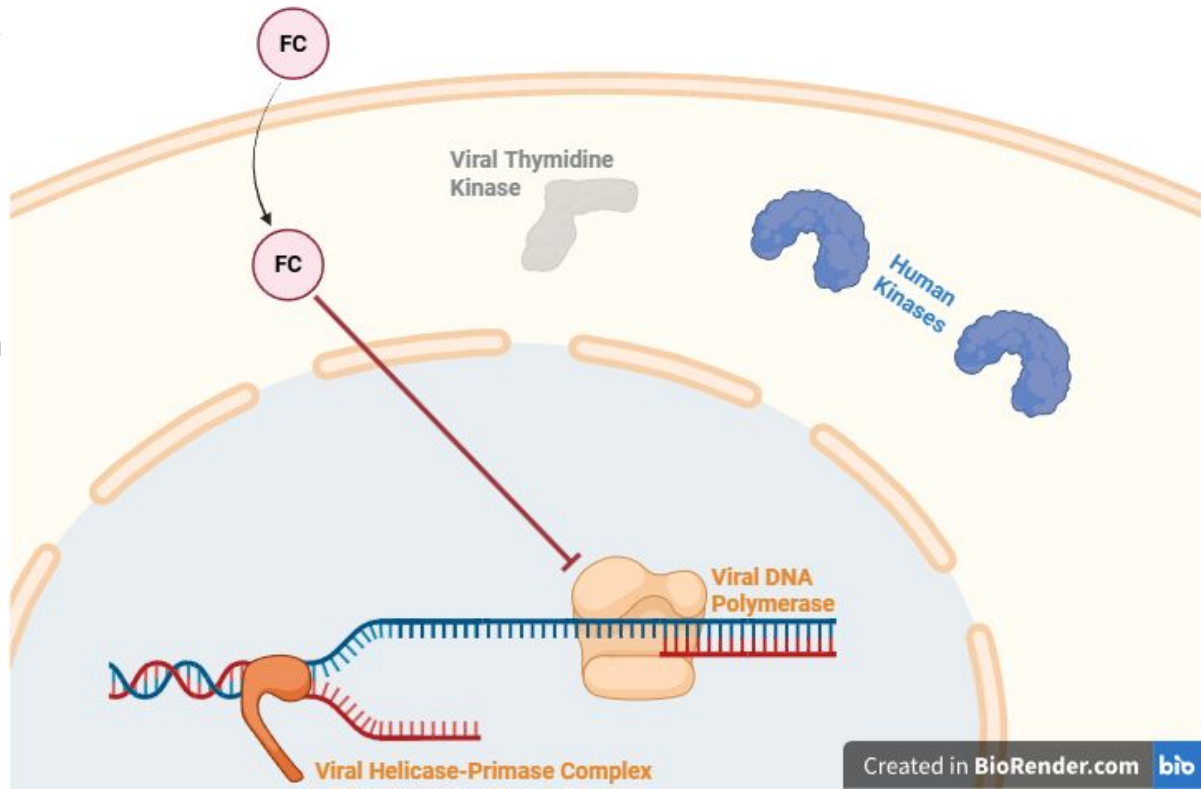


Foscarnet [6]

Pyrophosphate analog → **directly inhibits DNA polymerase**

Perhaps a little less cytotoxic than cidofovir

- Binds to **viral DNA pol** with **x1000 greater affinity** than human DNA pol



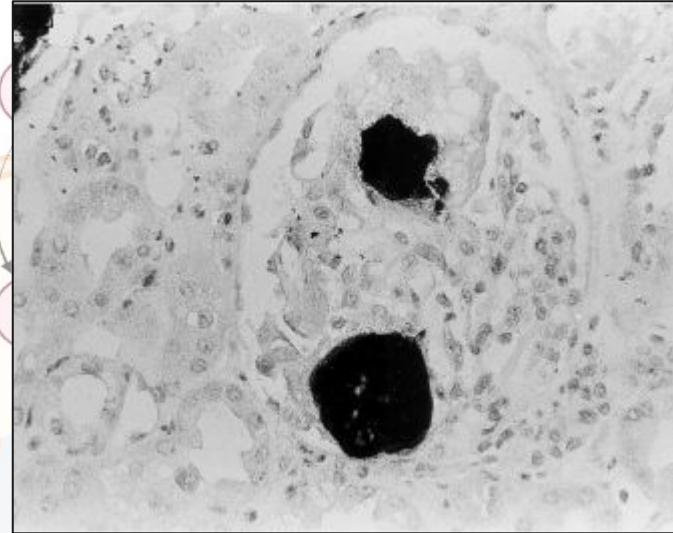
Foscarnet [6]

Pyrophosphate analog → **directly inhibits DNA polymerase**

Perhaps a little less cytotoxic than cidofovir

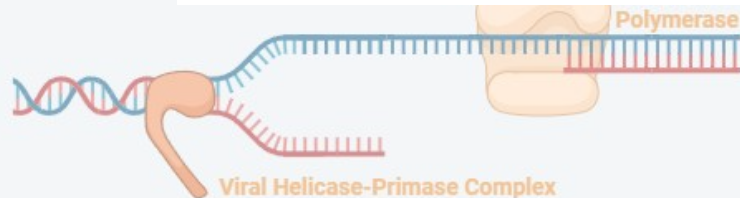
Still **quite nephrotoxic**

- Direct nephrotoxicity
- Crystal induced



Crystal nephropathy (black stain)

Zanetta et al (1999) PMID [10360595](https://pubmed.ncbi.nlm.nih.gov/10360595/)



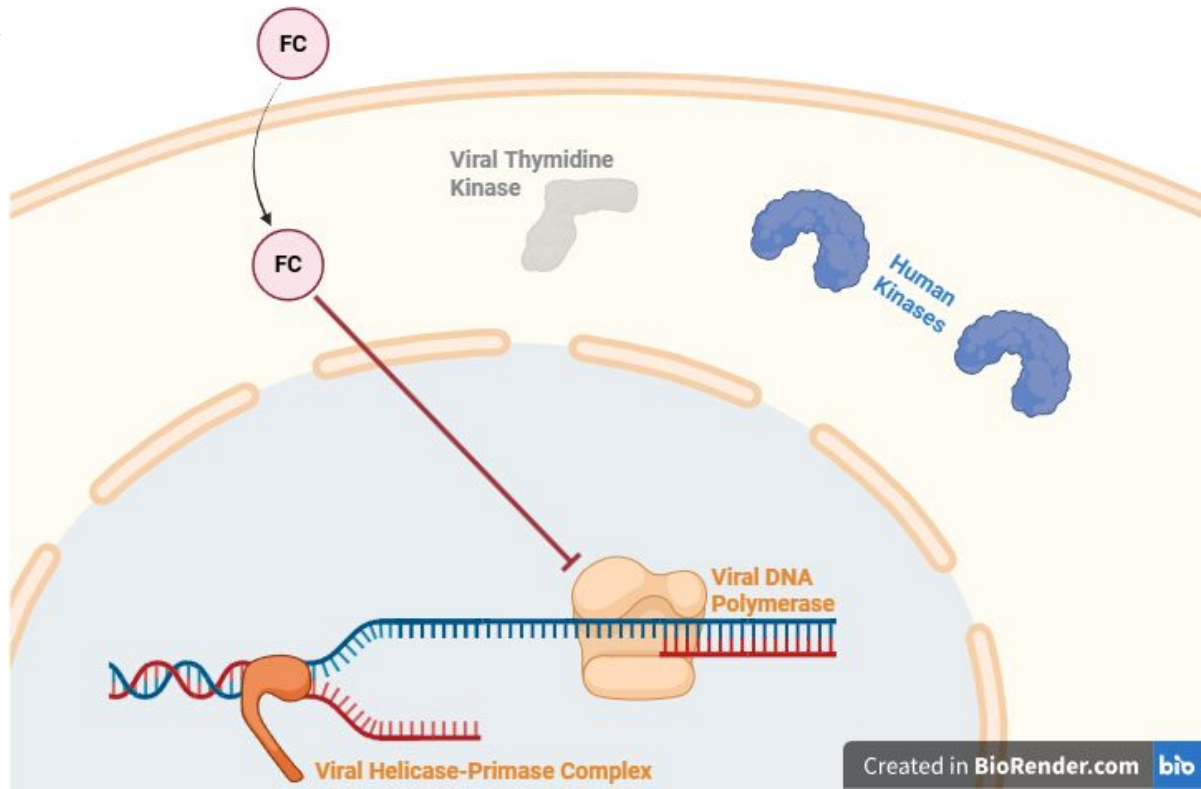
Foscarnet

Pyrophosphate analog → **directly inhibits DNA polymerase**

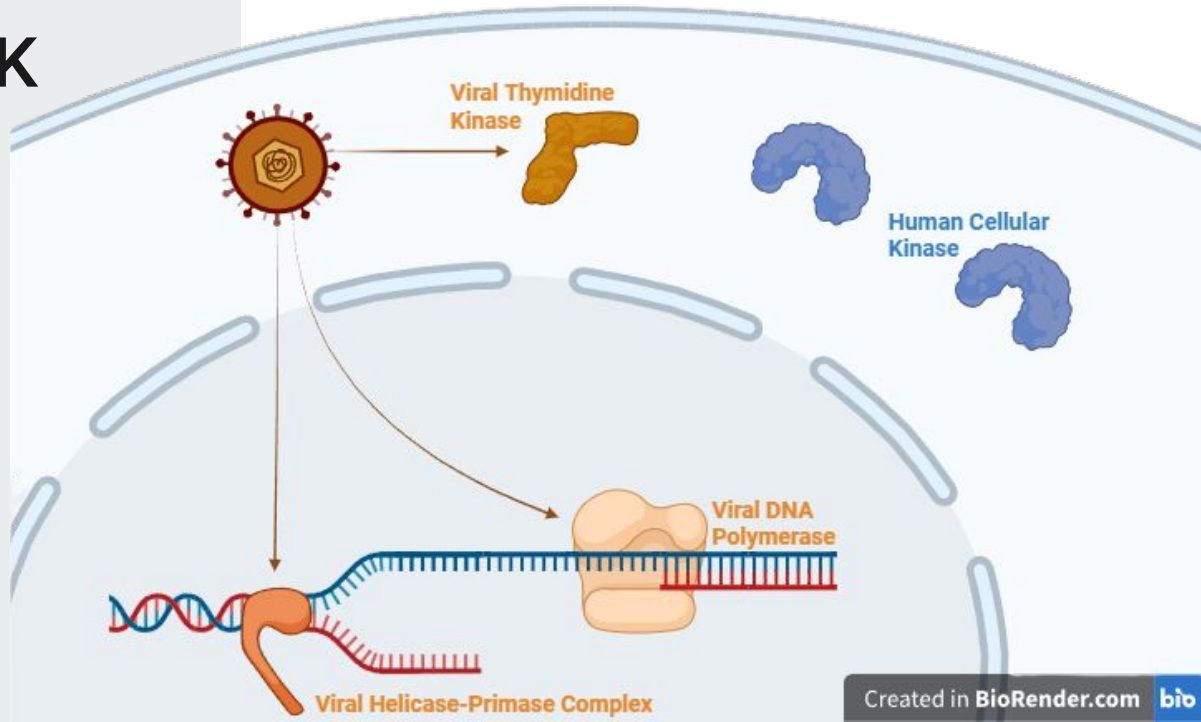
Perhaps a little less cytotoxic than cidofovir, but still **nephrotoxic**

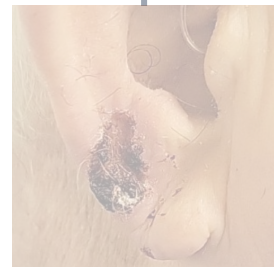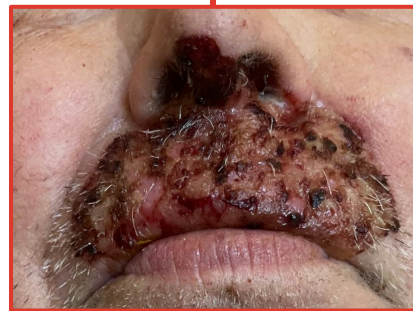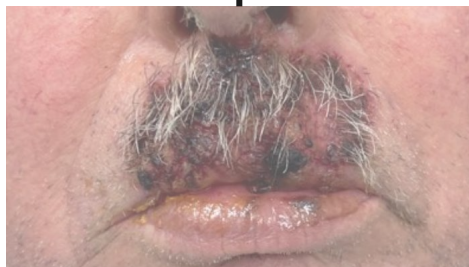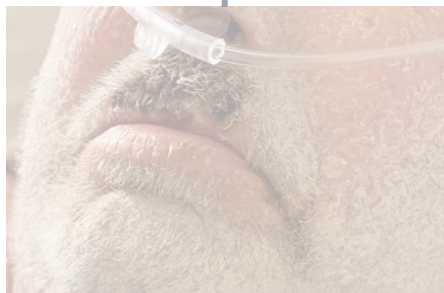
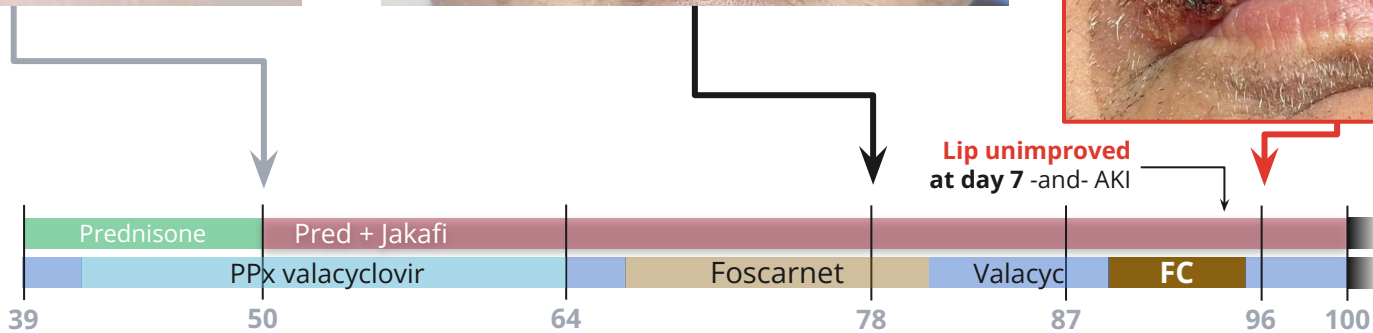
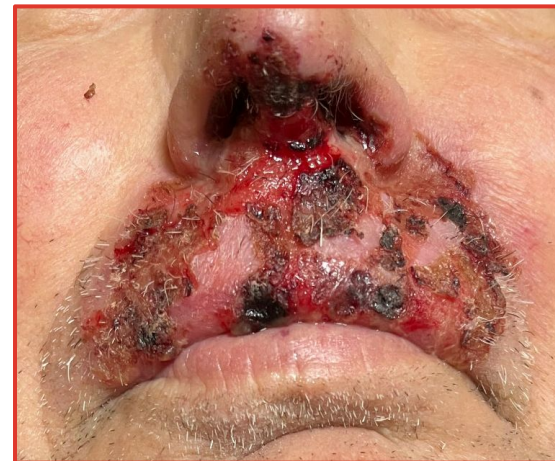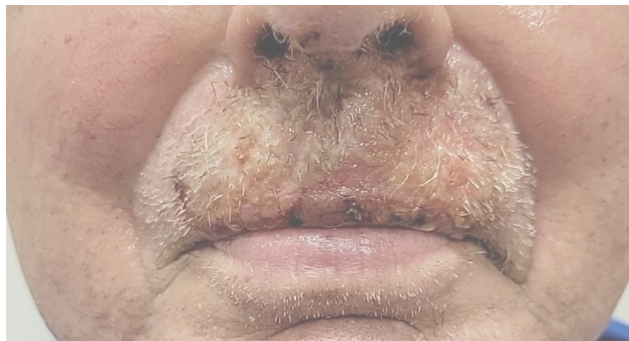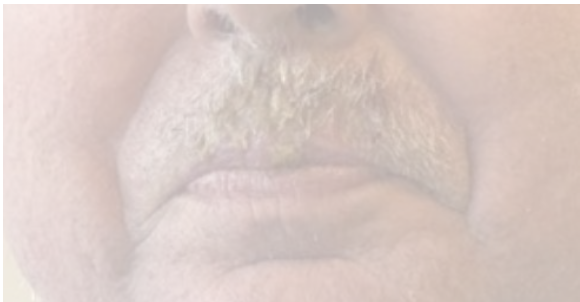
May also cause **genital ulcers**

- Likely a contact dermatitis due to high concentrations of foscarnet in urine



What if the problem is **not** TK deficiency?

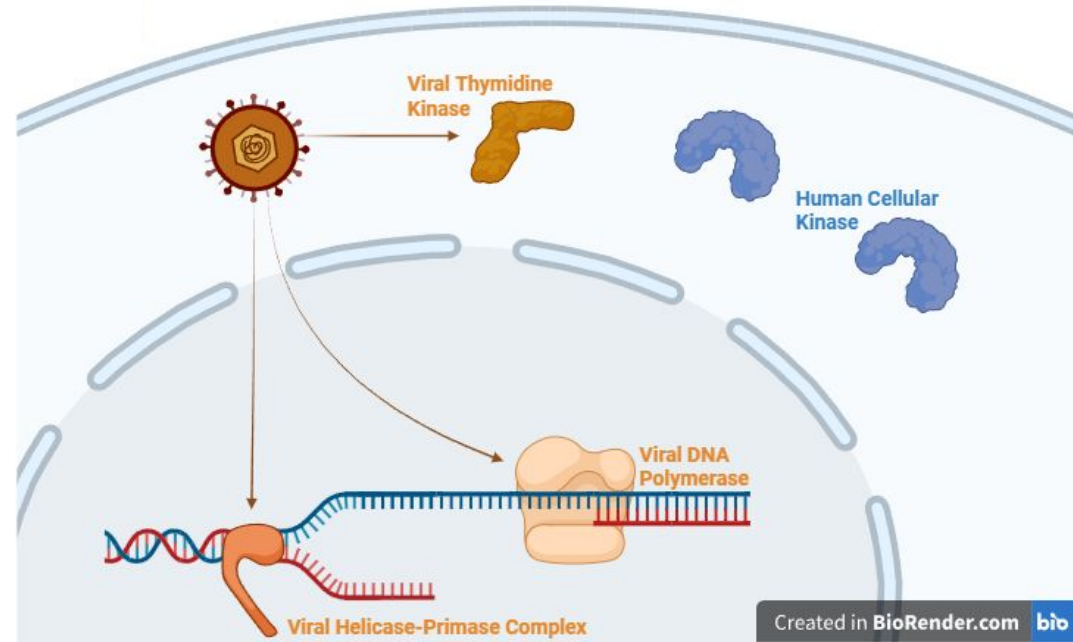




What if the problem is *not* TK deficiency?

TK deficiency is the most common reason for acyclovir resistance [2]

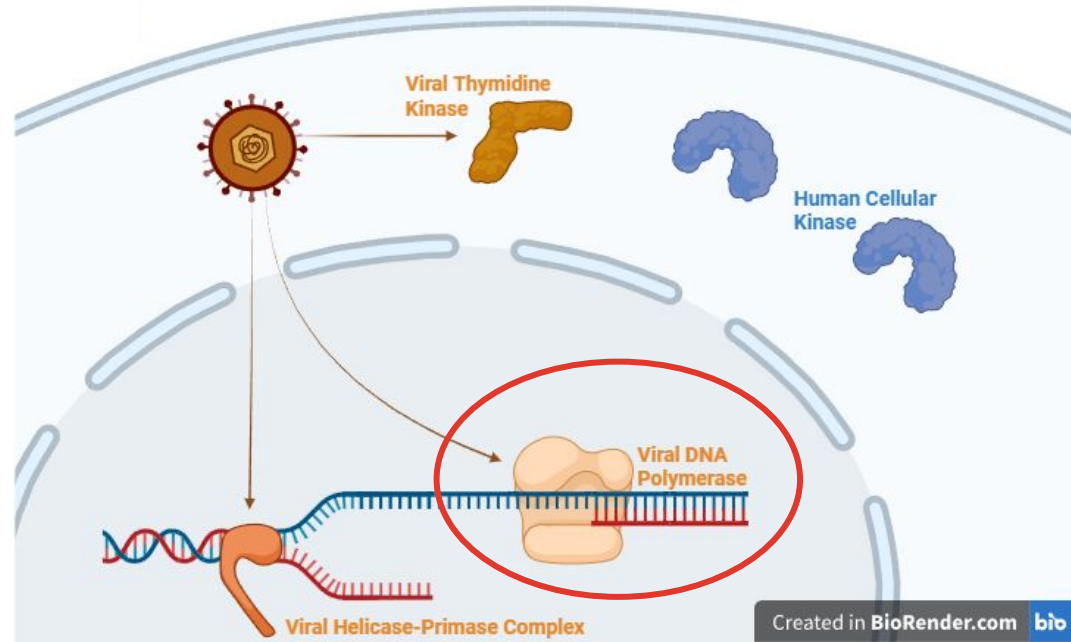
- But this is not the only reason



What if the problem is *not* TK deficiency?

TK deficiency is the most common reason for acyclovir resistance [2]

- Some viral mutations (namely those **targeting DNA polymerase**) can confer resistance to **multiple agents**

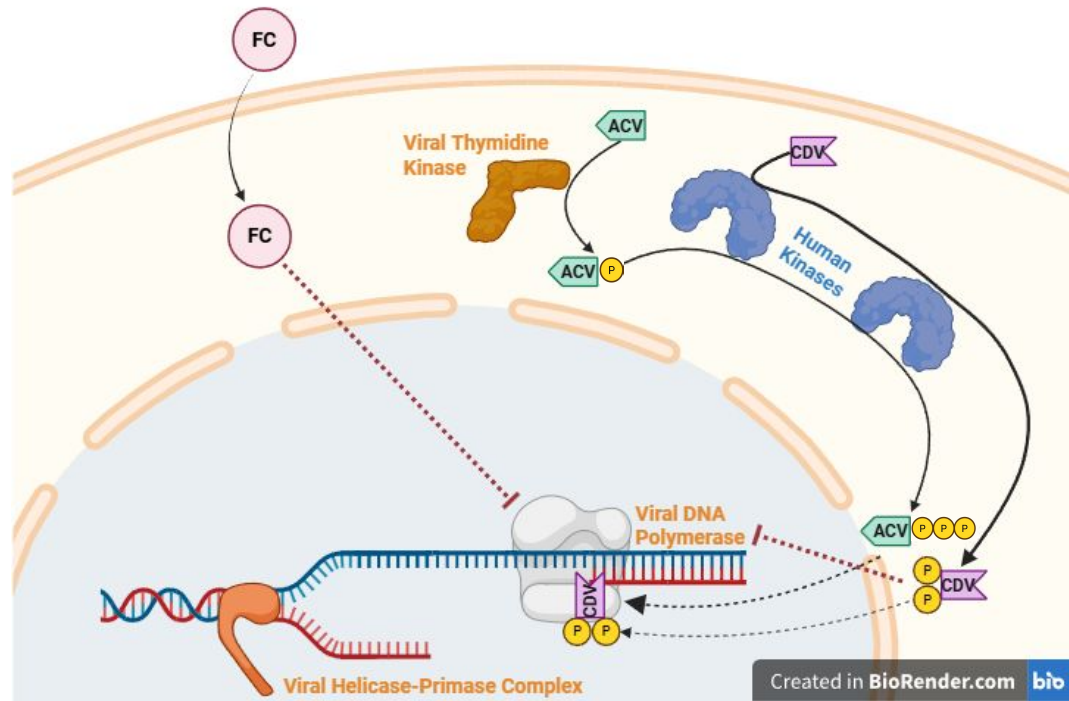


What if the problem is *not* TK deficiency? [2]

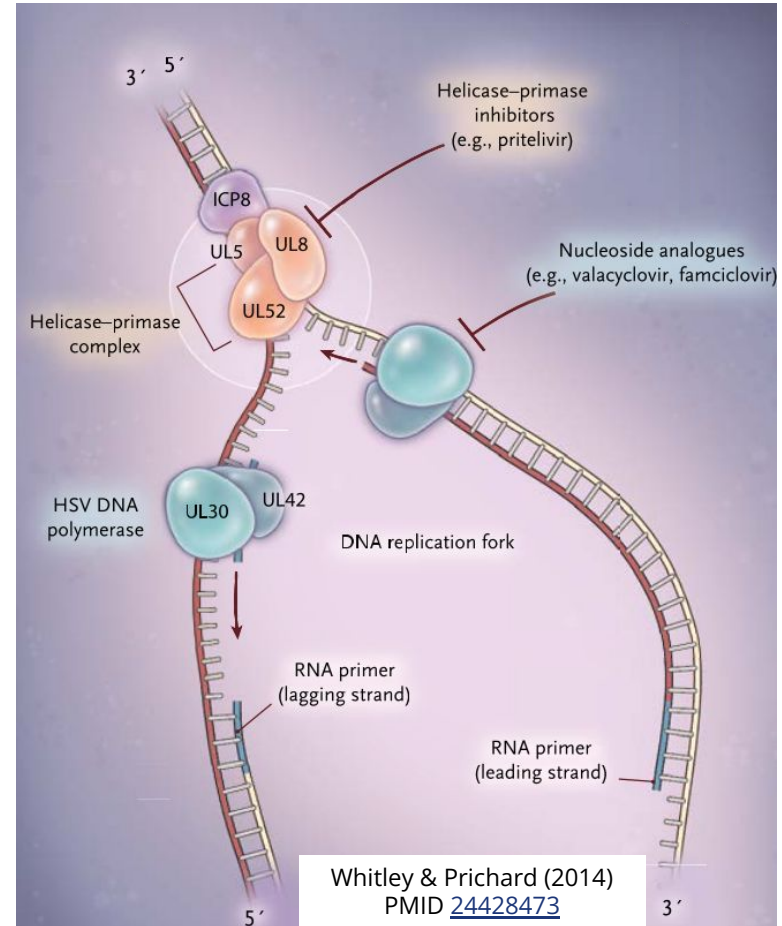
TK deficiency is the most common reason for acyclovir resistance

- Some viral mutations (namely those **targeting DNA polymerase**) can confer resistance to **multiple agents**

Examples (for HSV-1): Q727R, L778M, L802F, Y818C, W821M, G841C, R959H



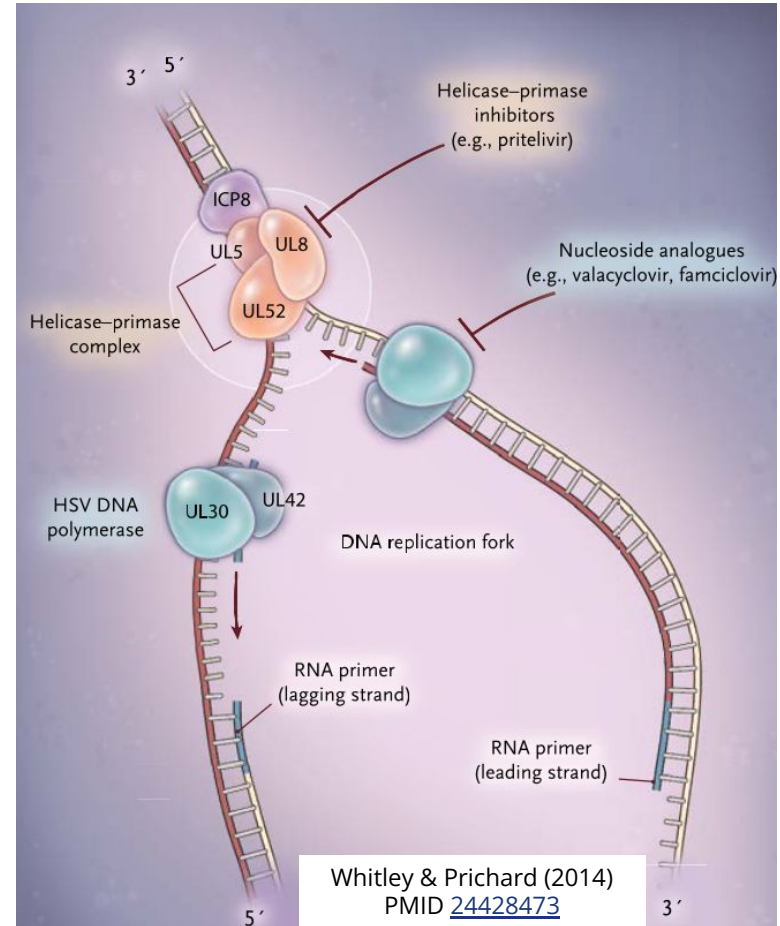
Helicase-Primase Inhibitors



Helicase-Primase Inhibitors [7]

Helicase: unwinds duplex DNA ahead of the fork & separates the double strand into two single strands

Primase: lays down RNA primers that the DNA polymerase extends



Helicase-Primase Inhibitors

Bypasses both TK and viral DNA polymerase

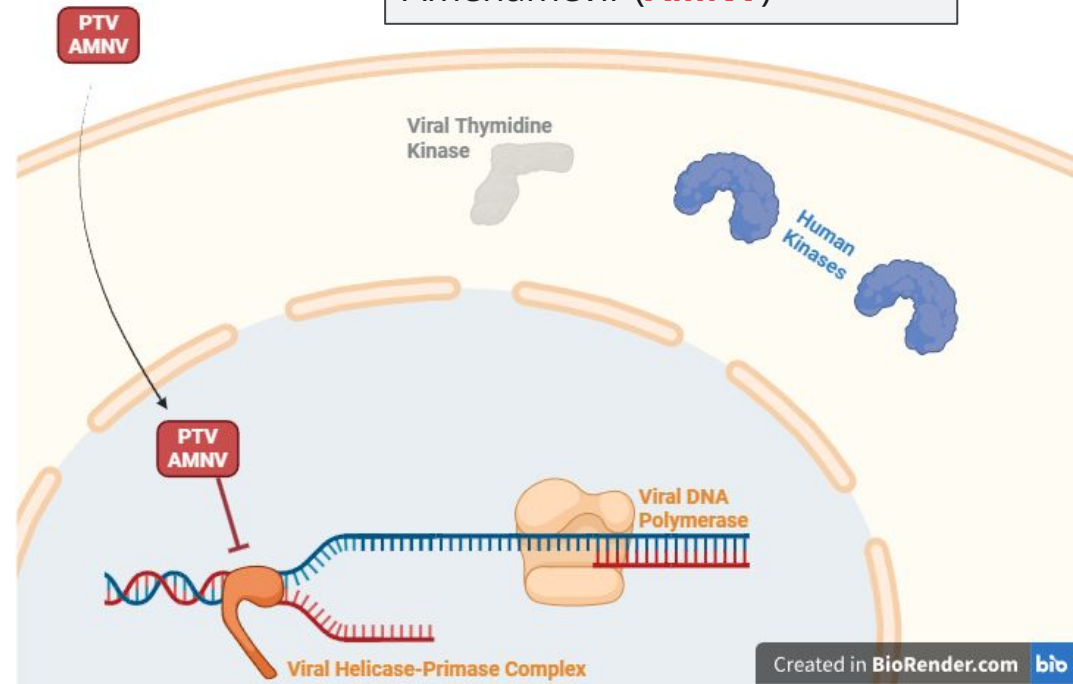
Two drugs (in trials or approved elsewhere):

- Pritelivir
- Amenamevir

Helicase-Primase Inhibitors

Pritelivir (**PTV**)

Amenamevir (**AMNV**)



Pritelivir [8]

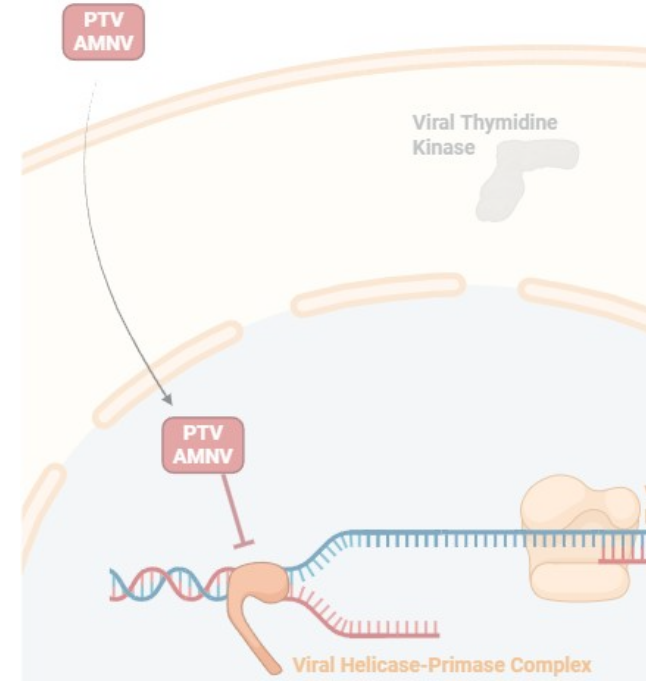
Wald (2014) [8] Phase II randomized trial

- Double blinded
- **Industry sponsored**

Helicase-Primase Inhibitors

Pritelivir (**PTV**)

Amenamevir (**AMNV**)



Pritelivir [8]

Wald (2014) Phase II randomized trial (industry sponsor)

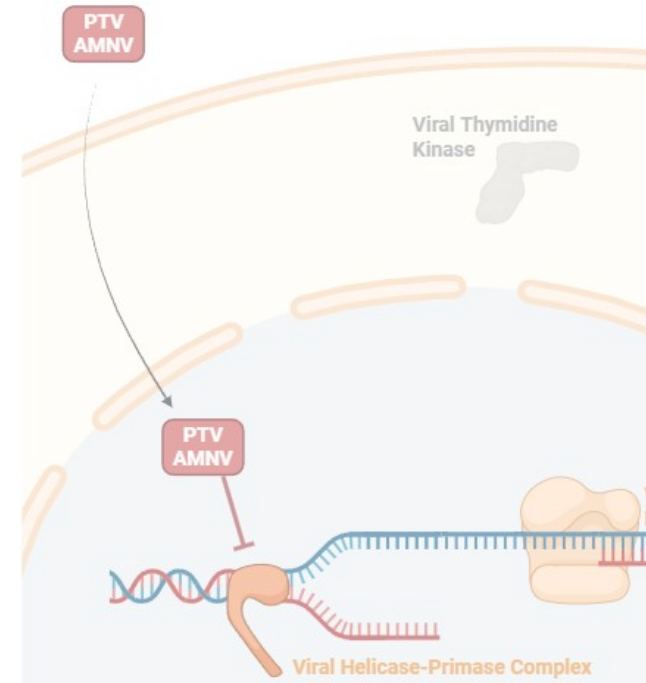
P: **Healthy adults** with HSV-2

- Seropositive for HSV-2
- **Recurrent** genital herpes (1-9 times per year)
- Immunocompetent
 - No HIV, HBV, HCV
- Not on other HSV meds
- **N = 150**

Helicase-Primase Inhibitors

Pritelivir (**PTV**)

Amenamevir (**AMNV**)



Pritelivir [8]

Wald (2014) Phase II randomized trial (industry sponsor)

P: Immunocompetent adults w/ recurrent HSV-2 (n=150)

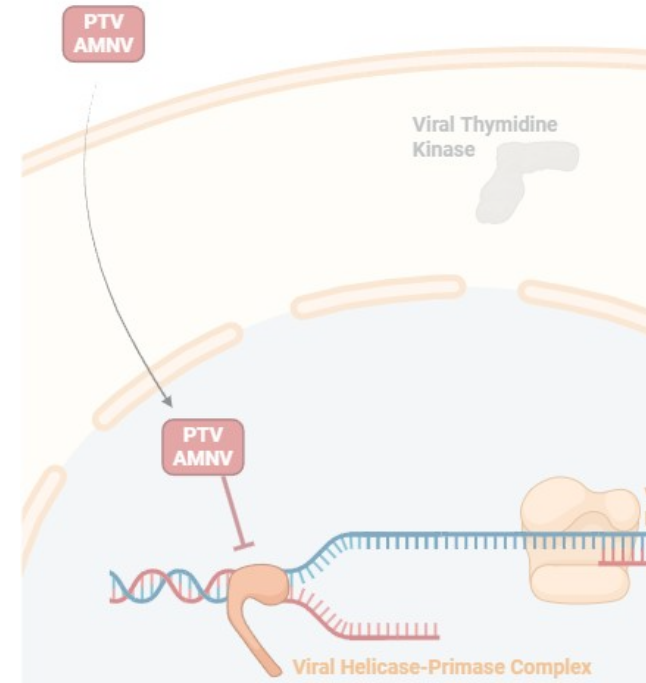
I: Pritelivir (at one of four doses)

- 5 mg daily
- 25 mg daily
- 75 mg daily
- 400 mg weekly

Helicase-Primase Inhibitors

Pritelivir (**PTV**)

Amenamevir (**AMNV**)



Pritelivir [8]

Wald (2014) Phase II randomized trial (industry sponsor)

P: Immunocompetent adults w/ recurrent HSV-2 (n=150)

I: Pritelivir (at one of four doses)

- 5 mg daily
- 25 mg daily
- 75 mg daily
- 400 mg weekly

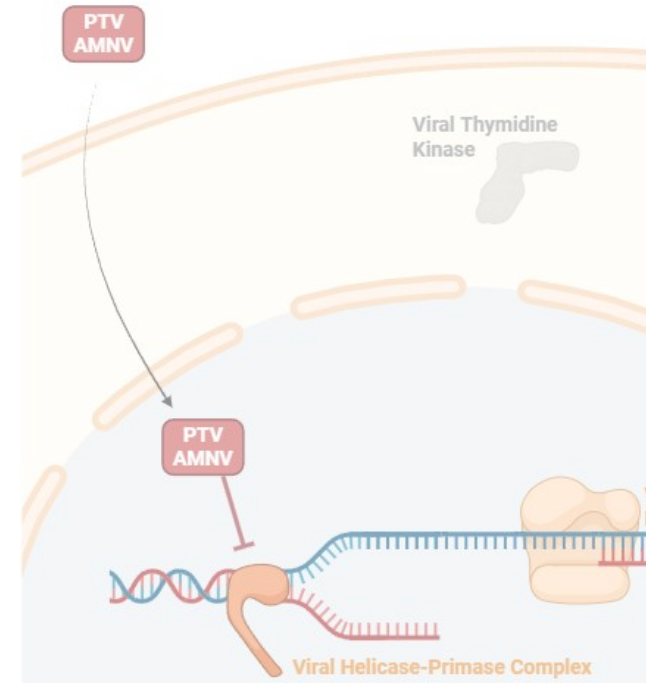
C: Placebo

- Randomized in a 1:1:1:1 manner

Helicase-Primase Inhibitors

Pritelivir (**PTV**)

Amenamevir (**AMNV**)



Pritelivir [8]

Wald (2014) Phase II randomized trial (industry sponsor)

P: Immunocompetent adults w/ recurrent HSV-2 (n=150)

I: Pritelivir (at one of four doses)

C: Placebo

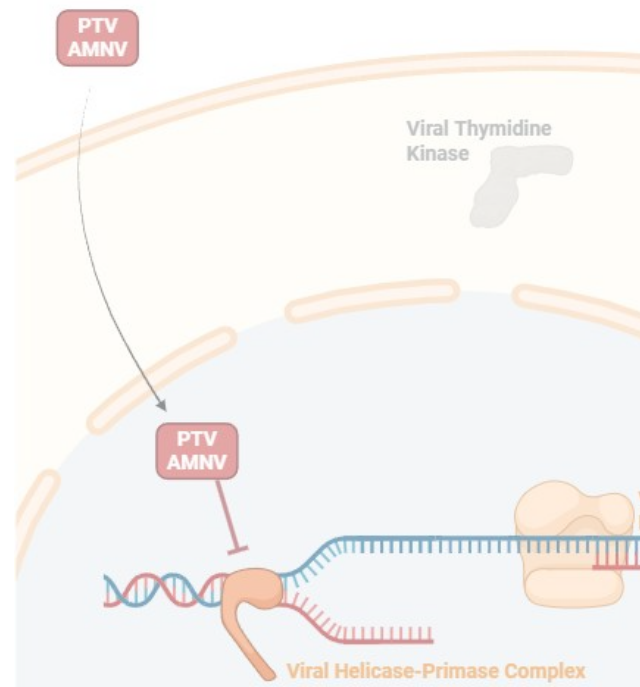
O: Rate of genital **HSV shedding** (primary outcome)

- Participants did **daily swabs** (even if no lesions)
- If **developed lesion**, did extra swab of lesions and came to **clinic within 24 hours**

Helicase-Primase Inhibitors

Pritelivir (**PTV**)

Amenamevir (**AMNV**)



Pritelivir [8]

Wald (2014) Phase II randomized trial (industry sponsor)

P: Immunocompetent adults w/ recurrent HSV-2 (n=150)

I: Pritelivir (at one of four doses)

C: Placebo

O: Rate of genital **HSV shedding** (primary outcome)

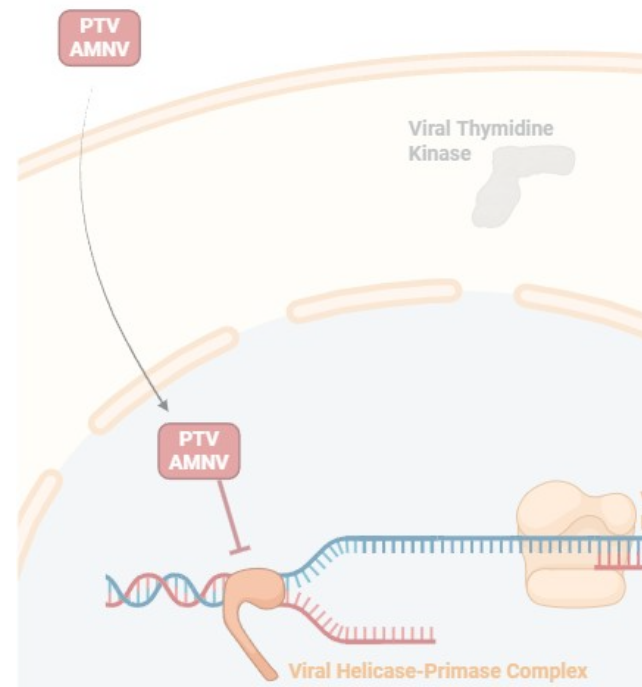
Secondary outcomes:

- Rates of lesions
- Reduction of HSV DNA copies
- Rates of subclinical shedding
- Safety / adverse events

Helicase-Primase Inhibitors

Pritelivir (**PTV**)

Amenamevir (**AMNV**)



Pritelivir [8]

Wald (2014) Phase II randomized trial (industry sponsor)

P: Immunocompetent adults w/ recurrent HSV-2 (n=150)

I: Pritelivir (at one of four doses)

C: Placebo

O: Rate of genital HSV shedding

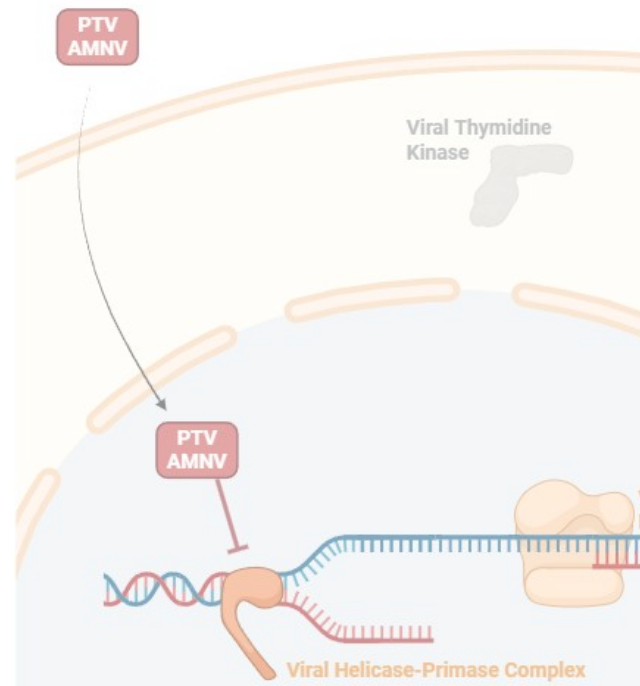
Before enrolling:

- Participants had median of 4 outbreaks per year
- 21% were on suppressive therapy

Helicase-Primase Inhibitors

Pritelivir (**PTV**)

Amenamevir (**AMNV**)



Pritelivir [8]

Wald (2014) Phase II randomized trial (industry sponsor)

P: Immunocompetent adults w/ recurrent HSV-2 (n=150)

I: Pritelivir (at one of four doses)

C: Placebo

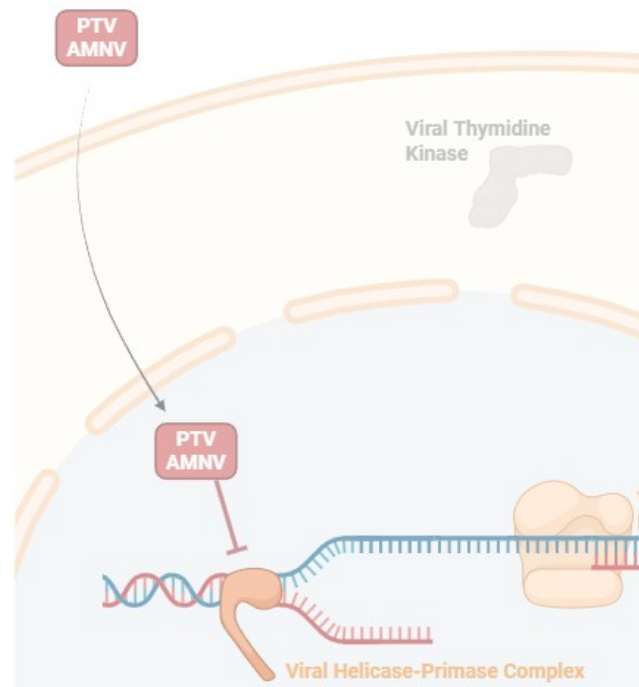
O: Rate of genital HSV shedding

	Placebo	PTV 5 mg daily	PTV 25 mg daily	PTV 75 mg daily	PTV 400 mg weekly
Days shedding	16.6% of days	18.2%	9.3%	2.1%	5.3%

Helicase-Primase Inhibitors

Pritelivir (**PTV**)

Amenamevir (**AMNV**)



Pritelivir [8]

Wald (2014) Phase II randomized trial (industry sponsor)

P: Immunocompetent adults w/ recurrent HSV-2 (n=150)

I: Pritelivir (at one of four doses)

C: Placebo

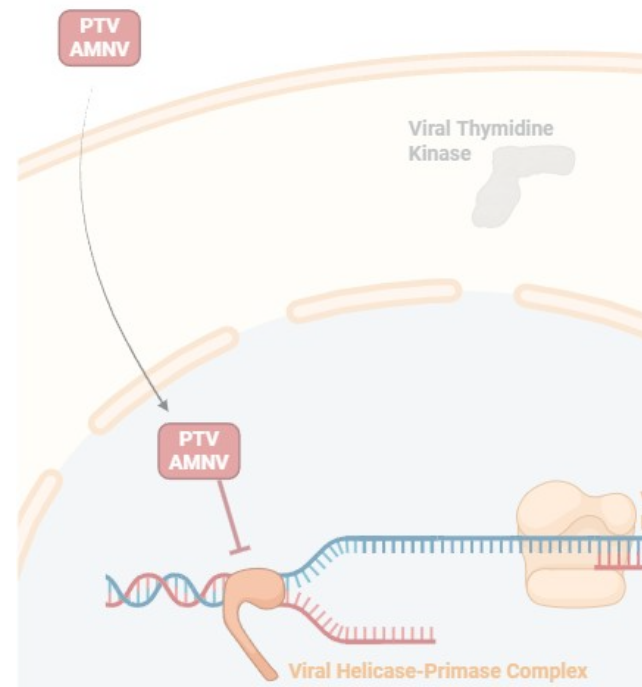
O: Rate of genital HSV shedding

Relative risk (ref: placebo group)	PTV 75 mg daily	PTV 400 mg weekly
Days shedding	0.13 (0.04 - 0.38)	0.32 (0.17 - 0.59)
Days with lesions	0.13 (0.02 - 0.70)	0.13 (0.03 - 0.25)

Helicase-Primase Inhibitors

Pritelivir (**PTV**)

Amenamevir (**AMNV**)



Pritelivir [8]

Wald (2014) Phase II randomized trial (industry sponsor)

P: Immunocompetent adults w/ recurrent HSV-2 (n=150)

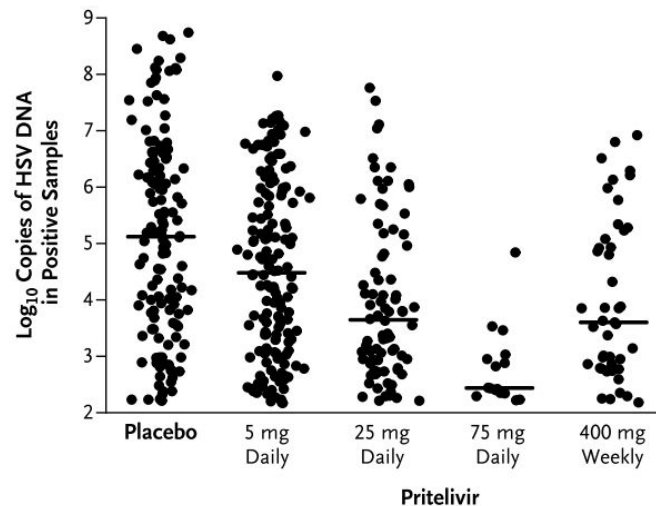
I: Pritelivir (at one of four doses)

C: Placebo

O: Rate of genital HSV shedding

Relative risk (ref: placebo group)	PTV 75 mg daily	PTV 400 mg weekly
Days shedding	0.13 (0.04 - 0.38)	0.32 (0.17 - 0.59)
Days with lesions	0.13 (0.02 - 0.70)	0.13 (0.03 - 0.25)

B



Pritelivir [8]

Wald (2014) Phase II randomized trial (industry sponsor)

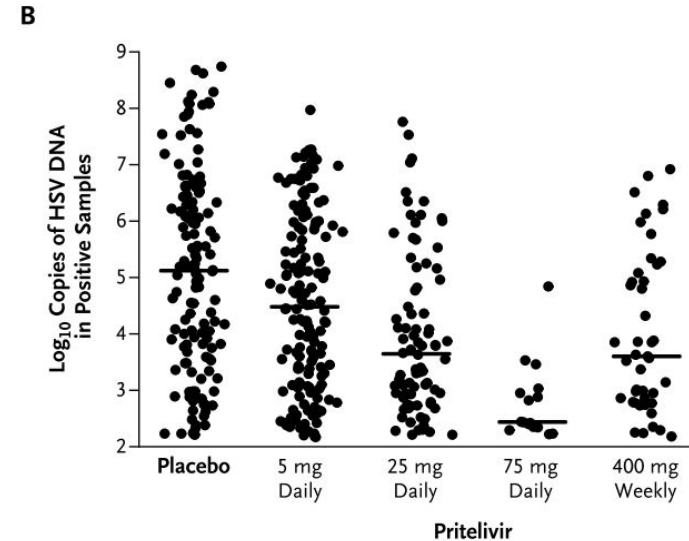
P: Immunocompetent adults w/ recurrent HSV-2 (n=150)

I: Pritelivir (at one of four doses)

C: Placebo

O: Rate of genital HSV shedding

- Similar rates of adverse events for
 - Drug compared to placebo
 - Across doses



Pritelivir [9]

Wald (2016) Phase II crossover RCT (industry sponsor)

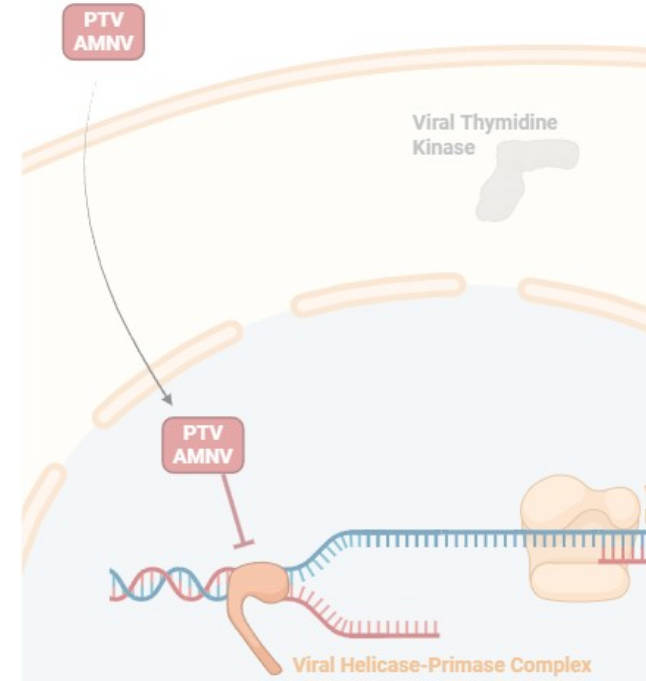
P: Healthy adults with recurrent HSV-2 (**same as before**)

- N = 91

Helicase-Primase Inhibitors

Pritelivir (**PTV**)

Amenamevir (**AMNV**)



Pritelivir [9]

Wald (2016) Phase II crossover RCT (industry sponsor)

P: Immunocompetent adults w/ recurrent HSV-2 (n=91)

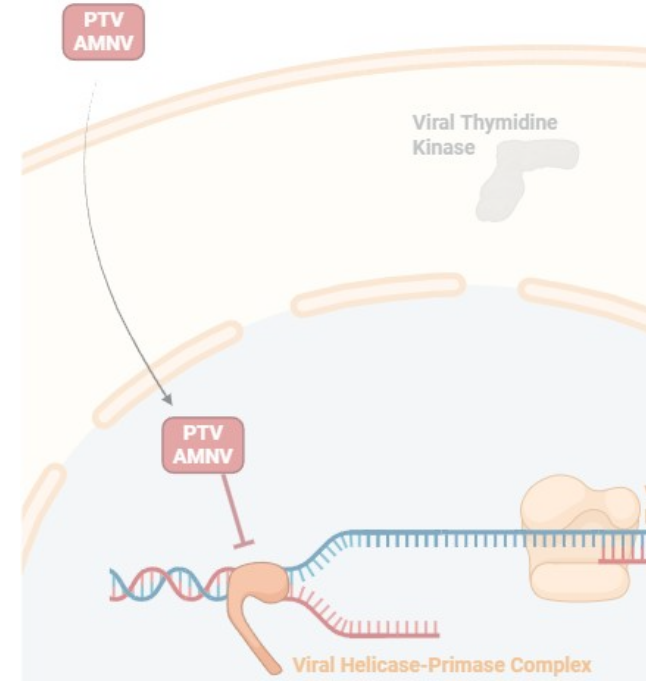
I: **Pritelivir** (100 daily) x 28 days

C: **Valacyclovir** (500 daily) x 28 days

Helicase-Primase Inhibitors

Pritelivir (**PTV**)

Amenamevir (**AMNV**)



Pritelivir [9]

Wald (2016) Phase II crossover RCT (industry sponsor)

P: Immunocompetent adults w/ recurrent HSV-2 (n=91)

I: Pritelivir (100 daily) x 28 days

C: Valacyclovir (500 daily) x 28 days

O: Rate of genital **HSV shedding** (primary outcome)

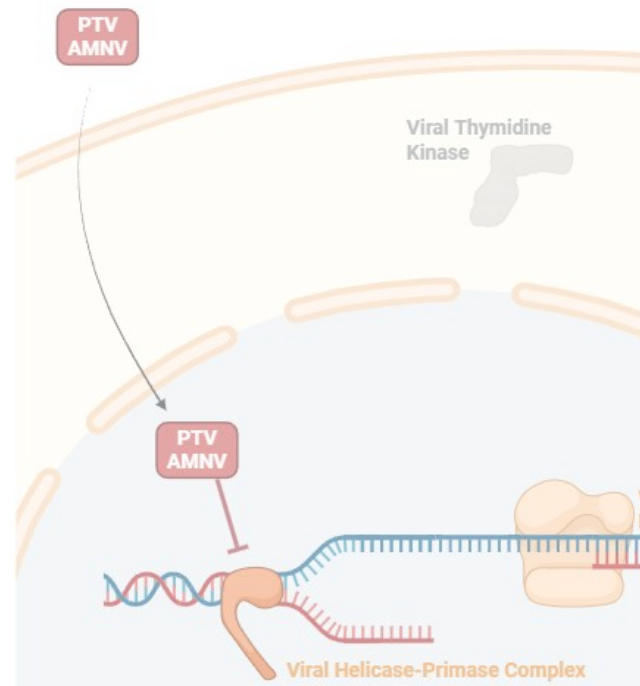
Secondary outcomes:

- Rates of lesions
- Reduction of HSV DNA copies
- Rates of subclinical shedding
- Adverse events

Helicase-Primase Inhibitors

Pritelivir (**PTV**)

Amenamevir (**AMNV**)



Pritelivir [9]

Wald (2016) Phase II crossover RCT (industry sponsor)

P: Immunocompetent adults w/ recurrent HSV-2 (n=91)

I: Pritelivir 100 daily x 28 days

C: **Valacyclovir** 500 daily x 28 days

O: Rate of genital HSV shedding

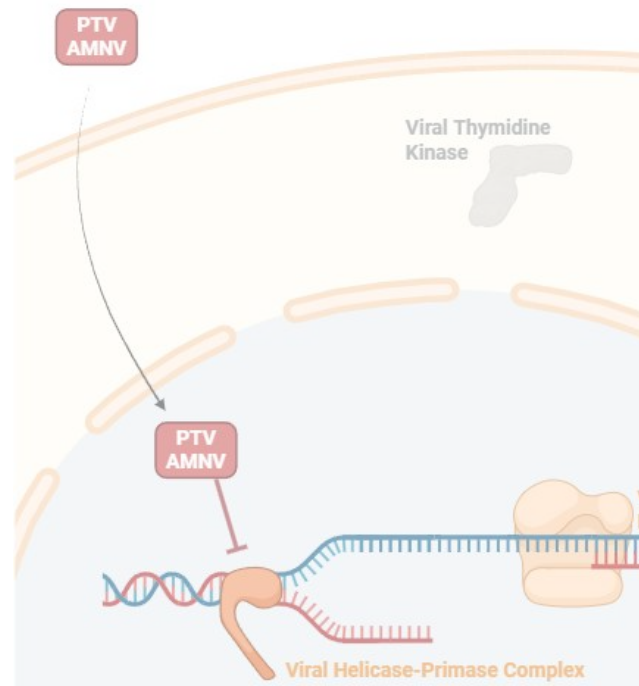
Terminated early

During study **FDA imposed a clinical hold** (an order to the sponsor to suspend ongoing investigation), based on **hematologic** and **dermatologic findings** such as dry skin, crusty skin lesions, and alopecia in a chronic toxicity study **involving monkeys**

Helicase-Primase Inhibitors

Pritelivir (**PTV**)

Amenamevir (**AMNV**)



Pritelivir [9]

Wald (2016) Phase II crossover RCT (industry sponsor)

P: Immunocompetent adults w/ recurrent HSV-2 (n=91)

I: Pritelivir 100 daily x 28 days

C: **Valacyclovir** 500 daily x 28 days

O: Rate of genital HSV shedding

Terminated early

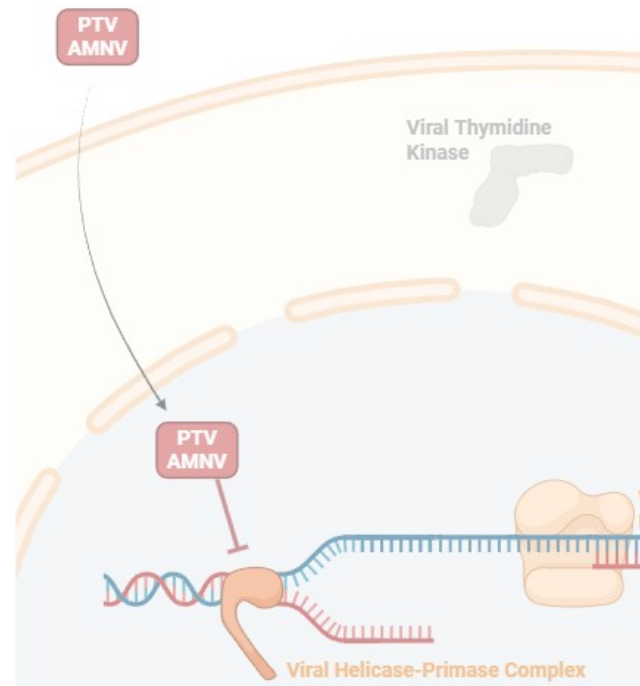
During study **FDA imposed a clinical hold**, based on hematologic and dermatologic findings in a chronic toxicity study involving monkeys.

Because the duration of the clinical hold was uncertain, the **sponsor terminated the study**

Helicase-Primase Inhibitors

Pritelivir (**PTV**)

Amenamevir (**AMNV**)



Pritelivir [9]

Wald (2016) Phase II crossover RCT (industry sponsor)

P: Immunocompetent adults w/ recurrent HSV-2 (n=91)

I: Pritelivir 100 daily x 28 days

C: **Valacyclovir** 500 daily x 28 days

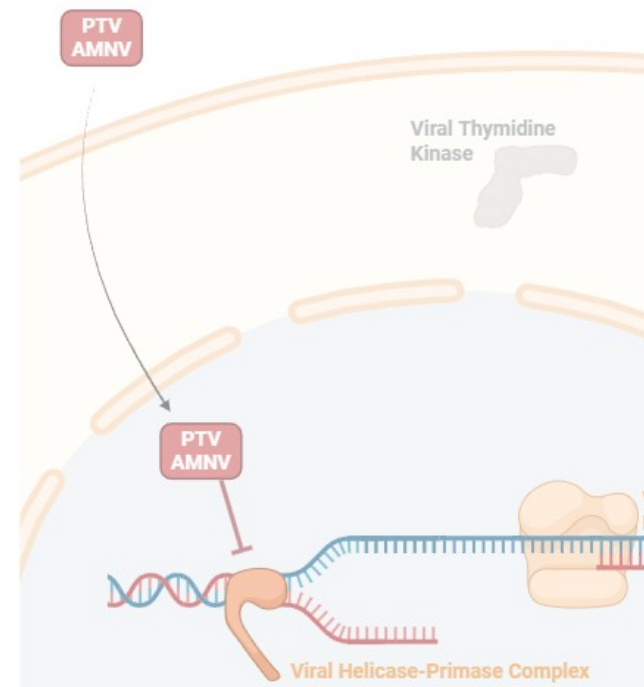
O: Rate of genital HSV shedding

Outcome	Valacyclovir	Pritelivir	Relative risk
Days shedding	5.3% of daily swabs	2.4% of daily swabs	0.42 (0.21 - 0.82)
Days with lesions	3.9% of days	1.9% of days	0.40 (0.17 - 0.96)

Helicase-Primase Inhibitors

Pritelivir (**PTV**)

Amenamevir (**AMNV**)



Pritelivir [9]

Wald (2016) Phase II crossover RCT (industry sponsor)

P: Immunocompetent adults w/ recurrent HSV-2 (n=91)

I: Pritelivir 100 daily x 28 days

C: **Valacyclovir** 500 daily x 28 days

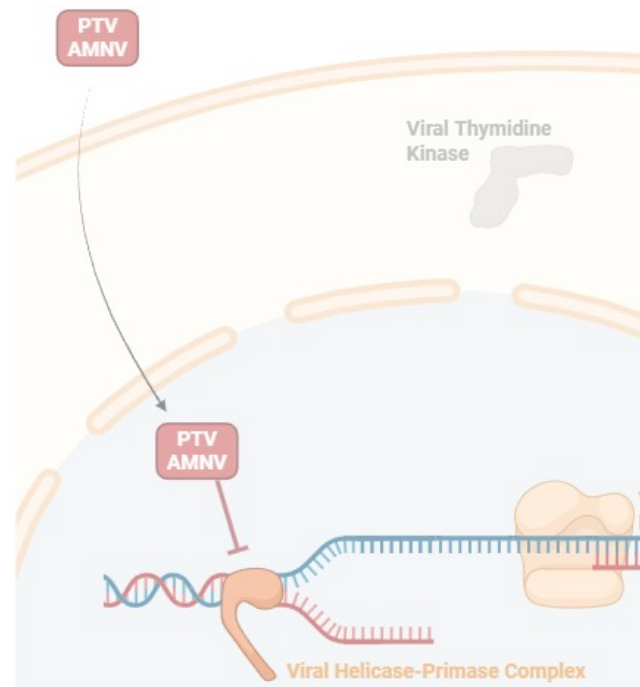
O: Rate of genital HSV shedding

- **Similar rates of adverse events**, but fairly high
- **Any AE:**
 - Valacyclovir: 69%
 - Pritelivir: 62%
- **Leading to discontinuation:**
 - 1.3% for both

Helicase-Primase Inhibitors

Pritelivir (**PTV**)

Amenamevir (**AMNV**)



Pritelivir



Has *breakthrough therapy designation* by FDA, with **ongoing phase III trial** ([NCT03073967](https://clinicaltrials.gov/ct2/show/study/NCT03073967))

Trial on Efficacy and Safety of Pritelivir for Treatment of Acyclovir-resistant **Mucocutaneous HSV Infections in Immunocompromised** Subjects

Part C: Pritelivir (vs foscarnet) in ACV-R HSV

Part D: Pritelivir in ACV-R and foscarnet-R / foscarnet intolerant HSV (enrollment closed)

Part E: Pritelivir in acyclovir susceptible HSV

Part F: Extension of Part D + those who had issues with foscarnet in Part C

Pritelivir



Has *breakthrough therapy designation* by FDA, with **ongoing phase III trial** ([NCT03073967](#))

Trial on Efficacy and Safety of Pritelivir for Treatment of Acyclovir-resistant **Mucocutaneous HSV Infections in Immunocompromised** Subjects

Expanded Access Program available from manufacturer for immunocompromised patients

Part C: Pritelivir (vs foscarnet) in ACV-R HSV

Part D: Pritelivir in ACV-R and foscarnet-R / foscarnet intolerant HSV (enrollment closed)

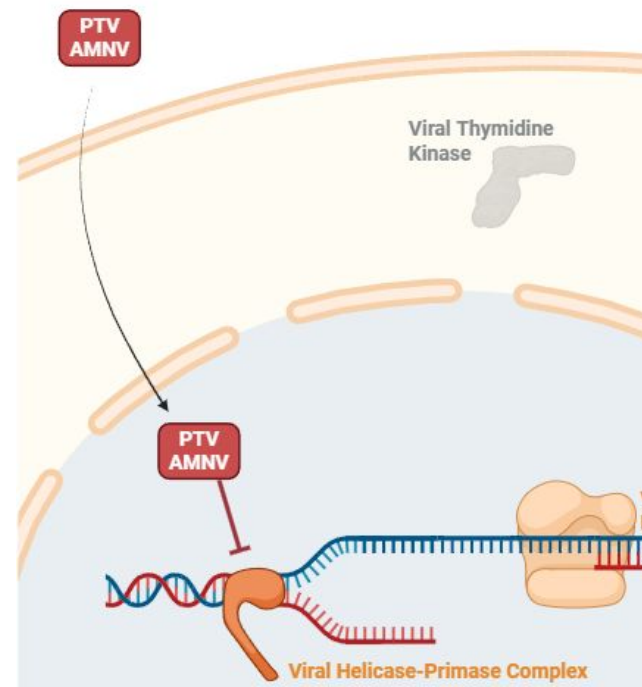
Part E: Pritelivir in acyclovir susceptible HSV

Part F: Extension of Part D + those who had issues with foscarnet in Part C

Amenamevir [10]

- Unlike pritelivir, amenamevir has **VZV activity** as well
 - Approved for VZV (namely **shingles**) in Japan in 2017
 - Therefore, we have more data on amenamevir (vs pritelivir)

Helicase-Primase Inhibitors
Pritelivir (**PTV**)
Amenamevir (**AMNV**)

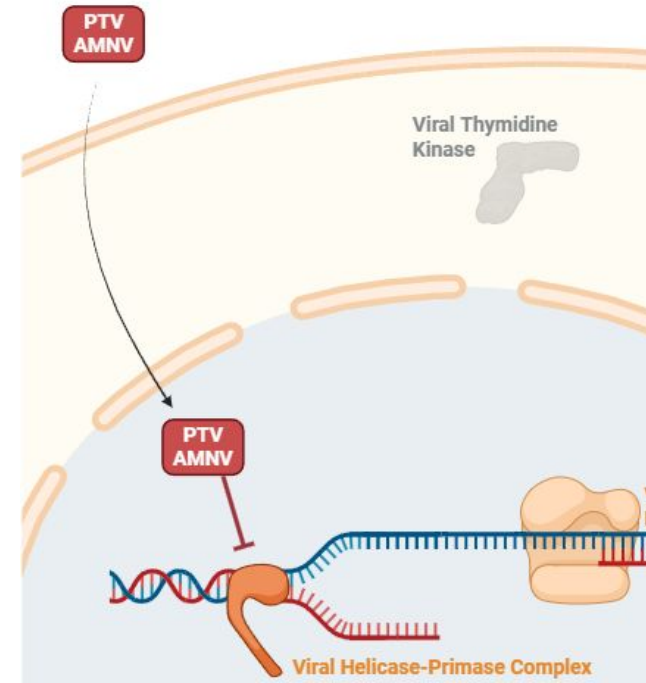


Amenamevir [10]

- Unlike pritelivir, amenamevir has **VZV activity**
- **Unlike acyclovir**, the antiviral activity of amenamevir is **not influenced** by viral **replication cycle**
 - When **started later in the disease course** amenamevir was **more effective than valacyclovir** (mouse models)

Helicase-Primase Inhibitors

Pritelivir (**PTV**)
Amenamevir (**AMNV**)



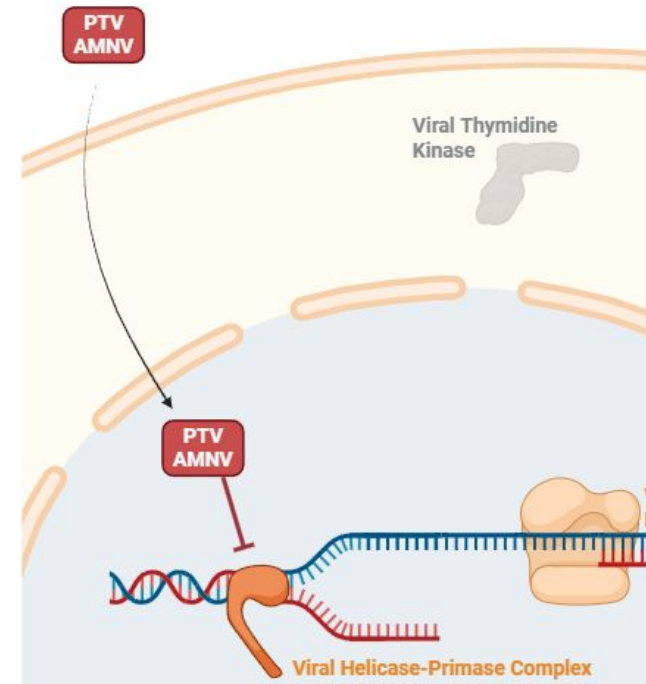
Amenamevir [10]

- Unlike pritelivir, amenamevir has **VZV activity**
- **Unlike acyclovir**, the antiviral activity of amenamevir is **not influenced** by viral **replication cycle**
 - When **started later in the disease course** amenamevir was **more effective than valacyclovir** (mouse models)
- May have a **synergistic effect** with acyclovir

Helicase-Primase Inhibitors

Pritelivir (**PTV**)

Amenamevir (**AMNV**)

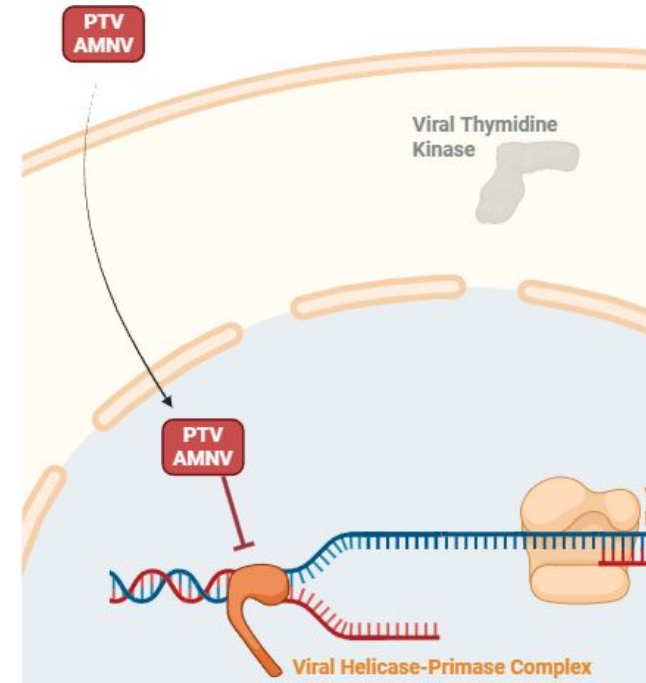


Amenamevir [10]

- Unlike pritelivir, amenamevir has **VZV activity**
- Unlike acyclovir, antiviral activity is **not influenced** by **replication cycle**; effective even late in disease course
- May have a **synergistic effect** with acyclovir
- Unlike TK deficiency, **HP deficiency** more drastically **affects viral fitness**
 - Amenamevir resistant strains have **attenuated growth** and are **less pathogenic** compared to wild type
 - Without HP, virus cannot replicate
 - **No cross-resistance** described between TK & HP

Helicase-Primase Inhibitors

Pritelivir (**PTV**)
Amenamevir (**AMNV**)

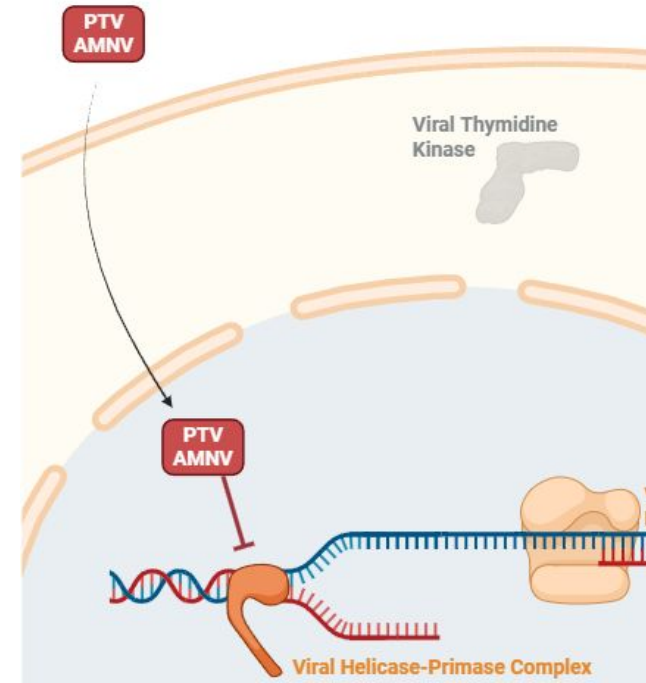


Amenamevir [10]

- Unlike pritelivir, amenamevir has **VZV activity**
- Unlike acyclovir, antiviral activity is **not influenced** by **replication cycle**; effective even late in disease course
- May have a **synergistic effect** with acyclovir
- Unlike TK deficiency, **HP deficiency** more drastically **affects viral fitness**
- **Post-marketing surveillance** implies it's **pretty safe**
 - Incidence of adverse drug reactions is **0.82%** (11 cases)
- Reported events (none were serious)
 - 4 cases of **GI upset**
 - 2 cases of **thrombocytopenia**
 - 1 case of **palpitations**

Helicase-Primase Inhibitors

Pritelivir (**PTV**)
Amenamevir (**AMNV**)



Amenamevir in clinical trials

Tyring 2012 ^[11] (phase 2, n=437)

P: Recurrent genital HSV (≥ 4 per year)

I: Amenamevir (@time of prodrome)

C: Placebo or Valtrex x 3 days

O: Time to lesion healing

- Better than placebo
- No better than Valtrex

Similar adverse events

Amenamevir in clinical trials

Tyring 2012 ^[11] (phase 2, n=437)

P: Recurrent **genital HSV** (≥ 4 per year)

I: Amenamevir (@time of prodrome)

C: **Placebo** or **Valtrex** x 3 days

O: **Time to lesion healing**

- Better than placebo
- No better than Valtrex

Similar adverse events

Kawashima 2017 ^[12] (phase 2, n=751)

P: Immunocompetent **VZV** (w/in 72h of Zoster onset)

I: Amenamevir (200 or 400) x 7 days

C: **Valtrex 1g TID** x 7 days

O: **No new lesions** forming **at day 4**

- Amenamevir 400 **non-inferior**
- Superior for those under 65

Similar adverse events

Amenamevir in clinical trials

Tyring 2012 ^[11] (phase 2, n=437)
P: Recurrent genital HSV (≥ 4 per year)
I: Amenamevir (@time of prodrome)
C: Placebo or Valtrex x 3 days
O: Time to lesion healing

- Better than placebo
- No better than Valtrex

Similar adverse events

Kawashima 2022 ^[13] (phase 3, n=264)
P: Recurrent genital HSV
I: Amenamevir 1.2g once (@time of prodrome)
C: Placebo alone
O: Time to lesion healing (median, days)

- Amenamevir: 4.0 days ($p = 0.002$)
- Placebo: 5.1 days

Similar adverse events

Kawashima 2017 ^[12] (phase 2, n=751)
P: Immunocompetent VZV (w/in 72h of Zoster onset)
I: Amenamevir (200 or 400) x 7 days
C: Valtrex 1g TID x 7 days
O: No new lesions forming at day 4

- Amenamevir 400 non-inferior
- Superior for those under 65

Similar adverse events

Amenamevir in clinical trials

Tyring 2012 ^[11] (phase 2, n=437)
P: Recurrent **genital** HSV (≥ 4 per year)
I: Amenamevir (@time of prodrome)
C: **Placebo** or **Valtrex** x 3 days
O: **Time to lesion healing**

- Better than placebo
- No better than Valtrex

Similar adverse events

Kawashima 2022 ^[13] (phase 3, n=264)
P: Recurrent **genital** HSV
I: Amenamevir 1.2g **once** (@time of prodrome)
C: **Placebo alone**
O: **Time to lesion healing** (median, days)

- Amenamevir: 4.0 days ($p = 0.002$)
- Placebo: 5.1 days

Similar adverse events

Kawashima 2017 ^[12] (phase 2, n=751)
P: Immunocompetent **VZV** (w/in 72h of Zoster onset)
I: Amenamevir (200 or 400) x 7 days
C: **Valtrex 1g TID** x 7 days
O: **No new lesions forming at day 4**

- Amenamevir 400 non-inferior
- Superior for those under 65

Similar adverse events

Kawashima 2023 ^[14] (phase 3, n=605)
P: Recurrent **herpes labialis**
I: Amenamevir 1.2g **once** (@time of prodrome)
C: **Placebo alone**
O: **Time to lesion healing** (median, days)

- Amenamevir: 5.1 days ($p = 0.008$)
- Placebo: 5.5 days

Shorter time to crusting (by **8 hours...**)
Similar adverse events

What would RFK do?

RCT of “natural” treatments

- **β-Glucan** from *Pleurotus ostreatus*
 - Versus placebo
- **Topical olive leaf extract**
 - Versus topical acyclovir

The introductions say **both of these agents** are also **active against HIV** *in vitro*

Move over, Biktarvy!

Urbancikova et al [15] (Evid Based Complement Alternat Med, 2020)

Randomized, multi-center, double blind, placebo controlled study looking at **pleuran** (insoluble β -1,3/1,6-D-glucan isolated from *Pleurotus ostreatus*)

- Adults & kiddos (> 6 y/o) with orolabial HSV
 - **Excluded** those who got **systemic** antivirals
 - Still **could receive** standard of care (**including topical antivirals**)



Pleurotus ostreatus AKA "oyster mushrooms" (Earth.com)

Urbancikova et al [15] (Evid Based Complement Alternat Med, 2020)

Randomized, multi-center, double blind, placebo controlled study looking at **pleuran** (insoluble β -1,3/1,6-D-glucan isolated from *Pleurotus ostreatus*)

- Adults & kiddos (> 6 y/o) with orolabial HSV
 - Excluded those who got systemic antivirals
 - Still **could receive** standard of care (**including topical antivirals**)
- 10 days of **treatment phase**
 - Daily vitamin C + Zinc + **300 mg pleuran** (n=49)
 - Daily vitamin C + Zinc (n=41)
- 120 days of **preventive phase**
 - Daily vitamin C + **100 mg pleuran**
 - Daily vitamin C

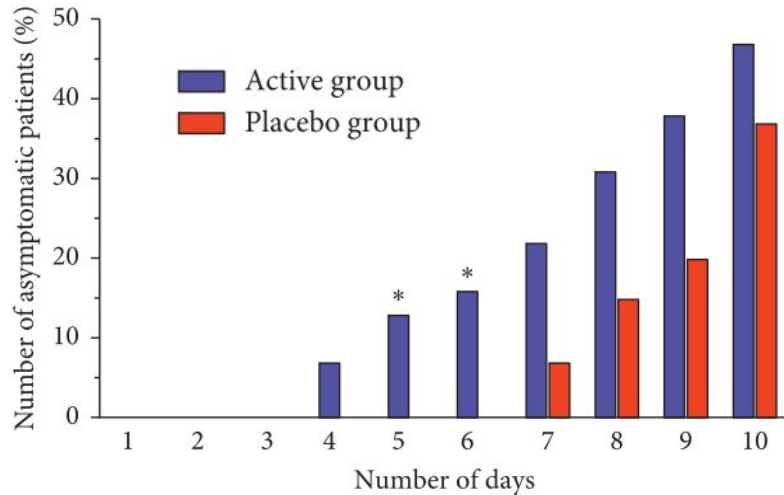


Pleurotus ostreatus AKA "oyster mushrooms" (Earth.com)

Urbancikova et al [15] (Evid Based Complement Alternat Med, 2020)

Active group had **shorter duration of symptoms (11.0 days)** compared to **placebo (12.2 days)**, $p=0.046$)

- This is a larger effect size than the amenamevir placebo trials...

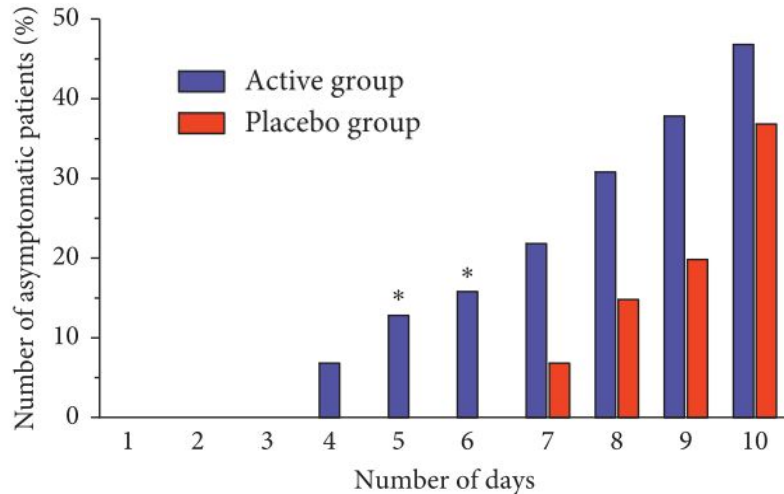


Pleurotus ostreatus AKA "oyster mushrooms" (Earth.com)

Urbancikova et al [15] (Evid Based Complement Alternat Med, 2020)

Active group had shorter duration of symptoms (11.0 days) compared to placebo (12.2 days, $p=0.046$)

- More patient in the placebo group (78%) received concomitant antiherpetic therapy than the active group (63%)

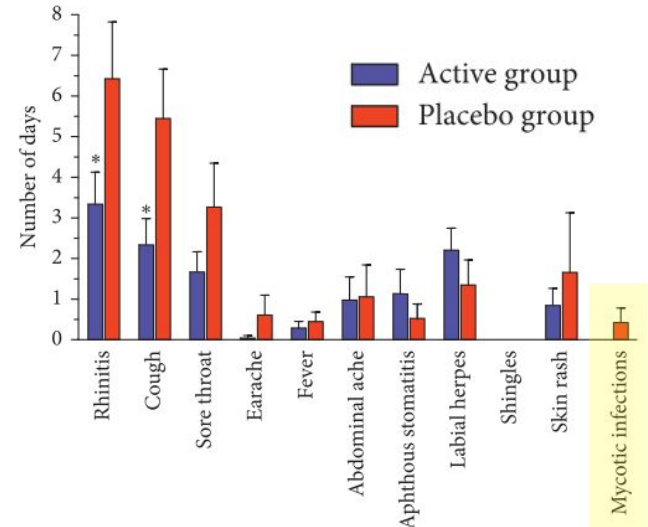


Pleurotus ostreatus AKA "oyster mushrooms" (Earth.com)

Urbancikova et al [15] (Evid Based Complement Alternat Med, 2020)

Active group had **shorter duration of symptoms (11.0 days)** compared to **placebo (12.2 days)**, $p=0.046$)

- More patient in the placebo group (**78%**) received **concomitant antiherpetic therapy** than the active group (**63%**)
- **No difference in recurrence** during preventive phase
- **No mycotic infections** in the active group (FYI)



Toulabi et al [16] (Explore, 2022)

Randomized, single-center, double blind, placebo controlled study looking at **topical olive leaf extract (OLE)** vs **topical acyclovir (ACY)**

- Adults with orolabial HSV (diagnosed clinically)
 - Excluded those who got systemic antivirals
- Olive leaf extract (n=33)
- Topical acyclovir (n=33)



Olive leaf (Wikipedia.com)

Toulabi et al [16] (Explore, 2022)

Randomized, single-center, double blind, placebo controlled study looking at **topical olive leaf extract (OLE)** vs **topical acyclovir (ACY)**

By **day 3 of treatment**, fewer subjects in the the **OLE group** had...

- Bleeding: **6.5%** --vs-- **25.8%** (p = 0.038)
- Pruritus: **12.9%** --vs-- **48.4%** (p = 0.002)
- Severe pain: **3.2%** --vs-- **35.5%** (p = 0.001)



Olive leaf (Wikipedia.com)

Learning points & take aways



Learning points & take aways

- The **acyclic nucleoside analogues**, such as **acyclovir**, are first line for treatment of HSV
- To become metabolically active, they must be first **be phosphorylated** by viral enzymes, namely **thymidine kinase** (TK)
 - Mutations in HSV's TK → acyclovir resistance
- For **TK-deficient HSV**, **foscarnet** and **cidofovir** are first line therapy
 - Somewhat limited by toxicity
 - Resistance to these agents (mutations in **viral DNA polymerase**) might **confer resistance to all** of the above drugs
- **Helicase-primase complex inhibitors** offer promising new treatment options
 - But then again, maybe rubbing olive oil on your face or eating mushrooms would work as well

