
Stomach aches

CLINID conference
Hunter Ratliff
07/31/2025

*Ages, dates, and other identifying information may have been changed
I have no conflict of interest in relation to this presentation*



Shortcuts



Case 1: [Start](#)

Case 2: [Start](#)

Case 3: [Start](#)

[Discussion:](#)

- **STOP-IT** (vs [PARACHUTE](#) trial)
- **DURAPOP**
- **CABI**

Takeaway slide

Case #1

Case 1: HPI



A 21 y/o M with no PMH p/w **sudden onset abdominal pain**

Case 1: HPI

A **21 y/o M** with no PMH p/w **sudden onset abdominal pain**

- Woke up with severe abdominal pain
 - Acute onset 3 hours after eating chicken wings
 - Constant pain generalized → worst BLQ
- Associated with nausea & emesis
 - Threw up over 20 times
 - Some diarrhea
- No association with urinary symptoms
 - No fevers or chills

Case 1: HPI

A **21 y/o M** with no PMH p/w **sudden onset abdominal pain**

- Woke up with severe abdominal pain
 - Acute onset 3 hours after eating chicken wings
 - Constant pain generalized → worst BLQ
- Associated with nausea & emesis
 - Threw up over 20 times
 - Some diarrhea
- No association with urinary symptoms
 - No fevers or chills

Medical Hx: None
Surgical Hx: None
Medications: None

Social history

- WVU student athlete
- No drugs, some EtOH
- Sexually active with “a few” female partners
 - Inconsistent condom use
 - No known STI Hx

Case 1: Physical Exam

A **21 y/o M** with no PMH p/w **sudden onset** (3 hours after after eating chicken wings)
generalized abdominal pain

Vitals: BP 177/71 | **Pulse 109** | **Temp 38.1°C** (100.6 °F) | **Resp 22** | SpO2 97% | BMI 22.7

Gen: In acute distress, **uncomfortable, constantly moving in bed**

HEENT: NCAT; anicteric sclerae

Resp: Respiratory effort is normal without distress

CV: RRR; no murmur, extremities perfused

GI: **abdominal tenderness** (in all quadrants), **tensing up abdomen** and unable to relax

Ext: no clubbing or cyanosis

Case 1: HPI

A **21 y/o M** with no PMH p/w **sudden onset abdominal pain**

- Woke up with severe abdominal pain
 - **Acute onset 3 hours** after eating chicken wings
 - **Constant pain** generalized → worst BLQ
- Associated with **nausea & emesis** x20
 - Threw up over 20 times
 - Some diarrhea
- No fevers/chills or urinary symptoms
- **Otherwise healthy** student athlete, drinks some, sexually active

Labs

WBC: **0.8** (**ANC <0.10**; abs **lymph 0.48**)

Hgb: 16 Platelets: 250

Glu: **207** HCO3: 18 pH: **7.49**

Cr: 0.9 LFTs: Normal

Lactate: **5.1**

UA: (+) glucose, (+) ketones

Physical Exam

VS: 38.1°C | 177/71 | 109 bmp

Gen: Uncomfortable, constantly moving in bed

GI: Diffuse TTP, tensing up abdomen, unable to relax

Case 1: HPI

A **21 y/o M** with no PMH p/w **sudden onset abdominal pain**

- Woke up with severe abdominal pain
 - **Acute onset 3 hours** after eating chicken wings
 - **Constant pain** generalized → worst BLQ
- Associated with **nausea & emesis** x20
 - Threw up over 20 times
 - Some diarrhea
- No fevers/chills or urinary symptoms
- **Otherwise healthy** student athlete, drinks some, sexually active

Labs

WBC: **0.8** (**ANC <0.10**; abs **lymph 0.48**)

Hgb: 16 Platelets: 250

Glu: **207** HCO₃: 18 pH: **7.49**

Cr: 0.9 LFTs: Normal

Lactate: **5.1**

UA: (+) glucose, (+) ketones

Physical Exam

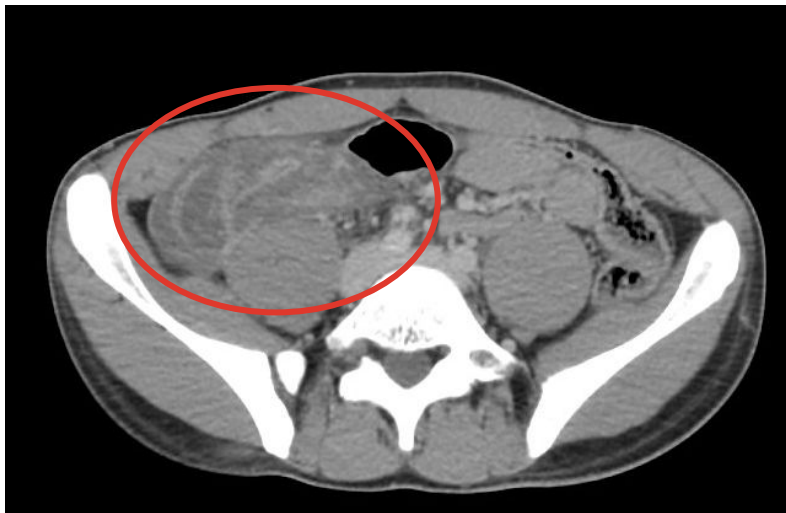VS: 38.1°C | 177/71 | 109 bmp

Gen: Uncomfortable, constantly moving in bed

GI: Diffuse TTP, tensing up abdomen, unable to relax

Next step?

Case 1: Radiographic findings



CT A/P (with contrast)

There is fluid in the distal esophagus. No bowel obstruction. There is a complex, edematous grouping of bowel in the right lower quadrant of the abdomen. The appendix is not clearly defined. There is free fluid in the pelvis and in the right lower quadrant of the abdomen.

IMPRESSION:

Likely **acute infectious or inflammatory process of the cecum and terminal ileum**, with **suspected superimposed ileocolic intussusception**. Consider repeat examination with the benefit of enteric contrast as clinically indicated.

Case 1: Operative course

Emergent Ex-lap (acute abdomen = OR now)

- Woke up with **severe abdominal pain**
 - **Acute onset** 3 hours after eating chicken wings
 - **Constant pain** generalized → worst BLQ
- Associated with **nausea & emesis**
- **Otherwise healthy** student athlete, drinks some, sexually active

Labs

WBC: **0.8** (ANC <0.10; abs lymph 0.48)

Hgb: 16

Platelets: 250

Glu: **207**

HCO₃: 18

pH: **7.49**

Cr: 0.9

LFTs: Normal

Lactate: **5.1**

UA: (+) glucose, (+) ketones

Physical Exam

VS: **38.1°C** | 177/71 | **109** bmp

Gen: Uncomfortable, **constantly moving in bed**

GI: Diffuse TTP, **tensing up abdomen**, unable to relax

Case 1: Operative course

Emergent Ex-lap (acute abdomen = OR now)

Procedure:

1. Exploratory laparotomy
2. Ileocectomy with anastomosis
3. SPY angiography

Operative Report

Peritonitis with 1L transudative ascites, **no perforation/contamination**, tight ileocolic intussusception not attempted to reduce. **Open ileocectomy** with anastomosis

Case 1: Operative course

Emergent Ex-lap (acute abdomen = OR now)

Procedure:

1. Exploratory laparotomy
2. Ileocectomy with anastomosis
3. SPY angiography
4. Resection of ileocolic anastomosis
5. Temporary abdominal closure with abthera negative pressure vacuum therapy

Operative Report

Peritonitis with 1L transudative ascites, **no perforation/contamination**, tight ileocolic intussusception not attempted to reduce. **Open ileocectomy** with anastomosis, **ischemia of anastomosis** on SPY angiography with **persistent lactic acidosis and vasopressor requirement** therefore **resected anastomosis** and **left open and in discontinuity**

Case 1: Operative course

Returns to OR the next day

Operative Report

Abtherra dressing was removed. Abdomen was irrigated. Small bowel & colonic staple lines appeared well perfused and generally the **bowel appeared healthy**. Spy angiography showed **good uptake** in both the small bowel and colon. Did side to side ileocolic anastomosis then closed the common enterotomy. A **portion of omentum was noted to be ischemic** with thrombosed vessels and **this portion was excised using ligasure**. Did x-rays which showed no retained sponges or instruments. **The fascia & skin were then closed**

Procedure:

1. RE opening Ex-lap
2. SPY angiography
3. Ileocolonic Anastomosis
4. Partial omentectomy
5. Fascia & skin closure

Admission

OR #1 (day 1)
Ileocectomy w/
intra-op anastomotic
ischemia, left open

OR #2 (day 2)
Ileocolonic anastomosis,
partial omentectomy,
bowel closure

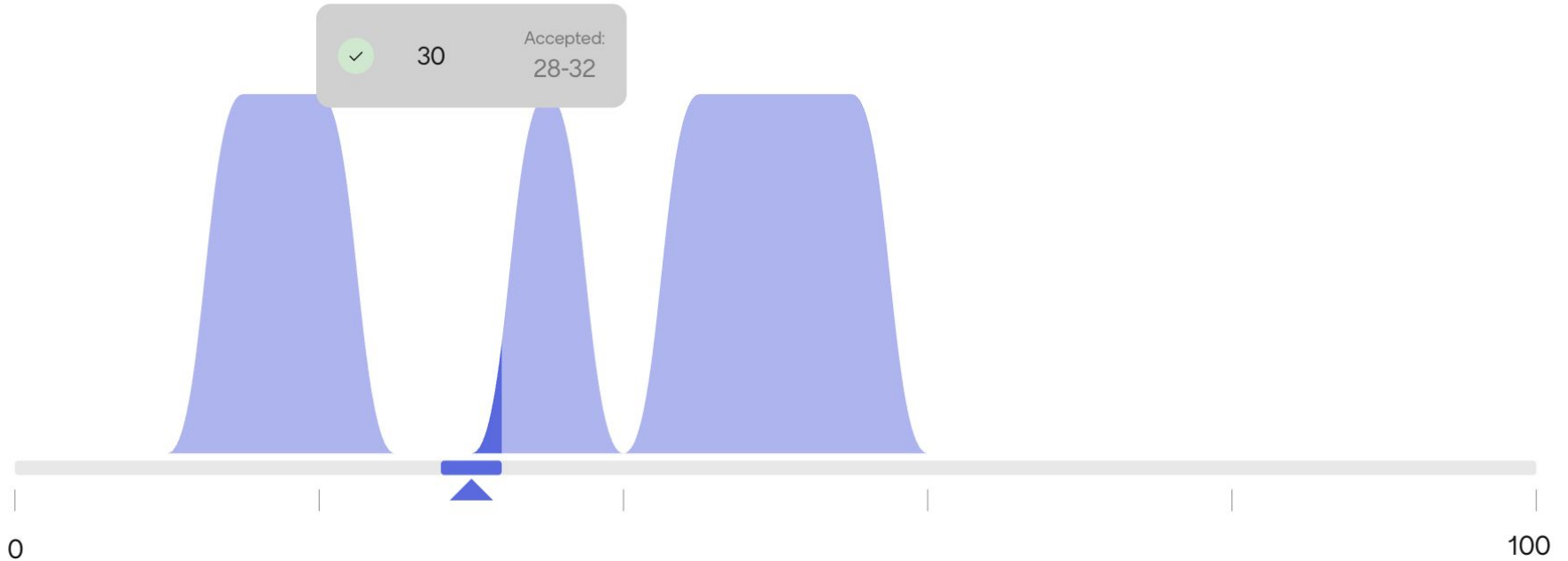
How many cIAI
have I seen in the
past year?

Starter question



The number of (unique) patients on my list is around 330

How many **complicated intra-abdominal infections** do you think I've seen at WVU?



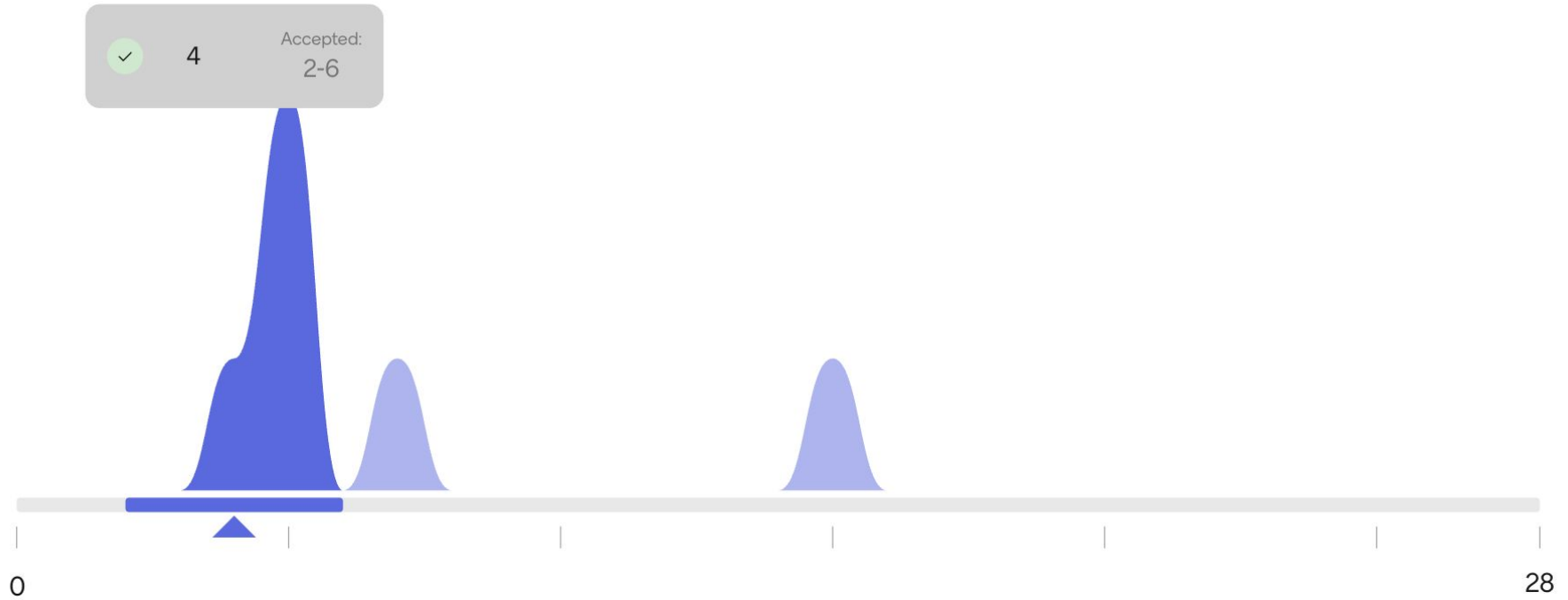
**[Q1.1] They didn't
consult us, but how
long would you give
antibiotics?**

Select a number



Assuming patient has good clinical
response

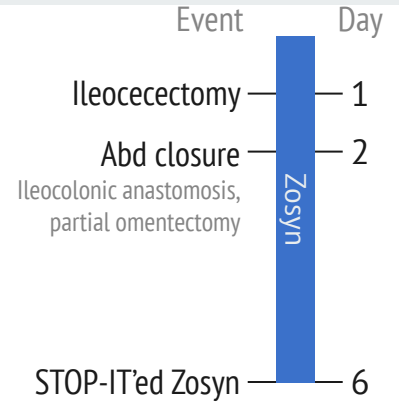
[Q1.1] Duration of antibiotics after source control



Case 1: Post-operative course




Finished 4 days of Zosyn (from source control)



Case 1: Post-operative course

Finished 4 days of Zosyn (from source control)

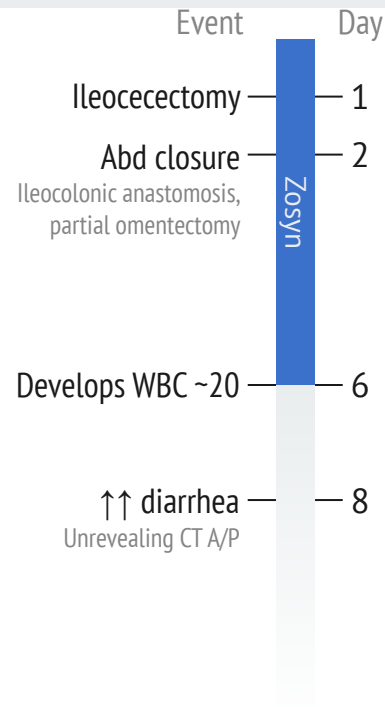
- Shortly after, develops leukocytosis to the 17-20 range



Case 1: Post-operative course

Finished 4 days of Zosyn (from source control)

- Shortly after, develops leukocytosis to the 17-20 range
- Then increased diarrhea
 - CT A/P (IV contrast only) at this time is unrevealing



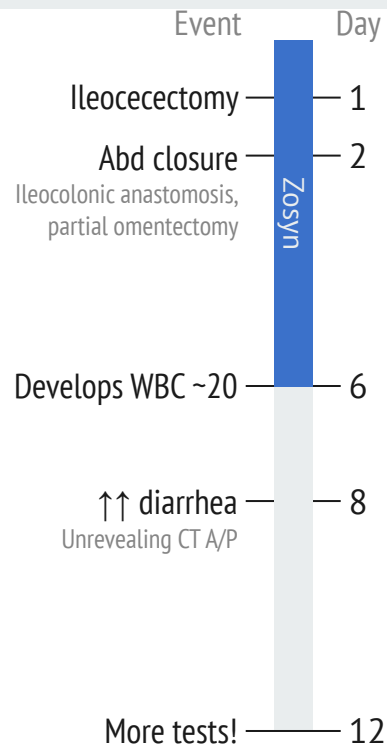
Case 1: Post-operative course

Finished 4 days of Zosyn (from source control)

- Shortly after, develops leukocytosis to the 17-20 range
- Then increased diarrhea
 - CT A/P (IV contrast only) at this time is unrevealing

Due to *ongoing leukocytosis*, surgery orders:

- C diff screening
- Repeat CT scan
- (still no antimicrobials)



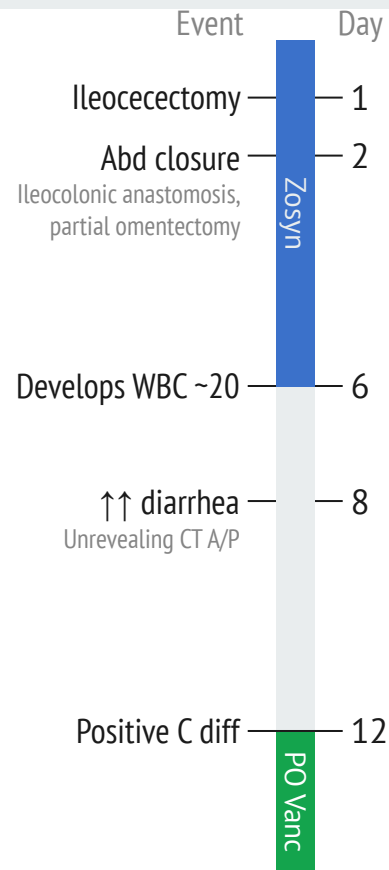
Case 1: Post-operative course

Finished 4 days of Zosyn (from source control)

- Shortly after, develops leukocytosis to the 17-20 range
- Then increased diarrhea
 - CT A/P (IV contrast only) at this time is unrevealing

Due to *ongoing leukocytosis*:

- **Positive C diff** → **Start PO vanc**
- Repeat CT scan



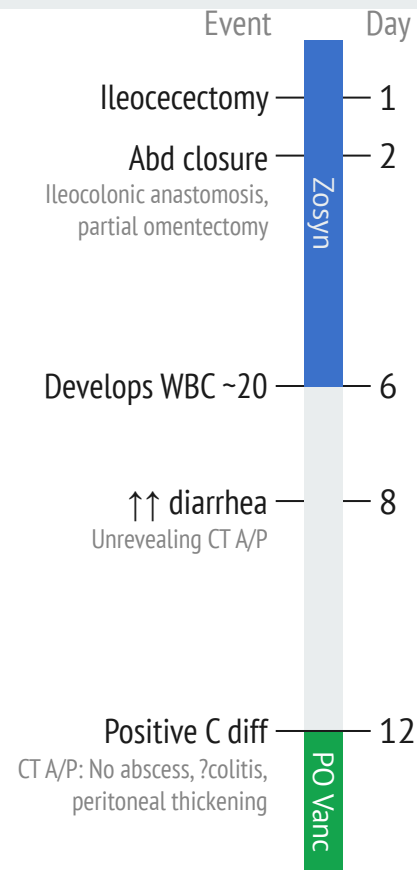
Case 1: Post-operative course

Finished 4 days of Zosyn (from source control)

- Shortly after, develops leukocytosis to the 17-20 range
- Then increased diarrhea
 - CT A/P (IV contrast only) at this time is unrevealing

Due to *ongoing leukocytosis*:

- **Positive C diff** → Start PO vanc
- Repeat CT scan → No abscess, maybe colitis, some peritoneal thickening



Case 1: Post-operative course

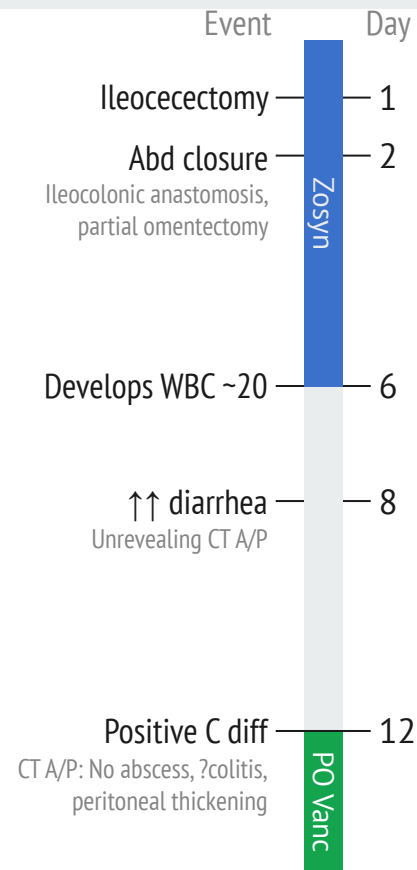
Finished 4 days of Zosyn (from source control)

- Shortly after, develops leukocytosis to the 17-20 range
- Then increased diarrhea
 - CT A/P (IV contrast only) at this time is unrevealing

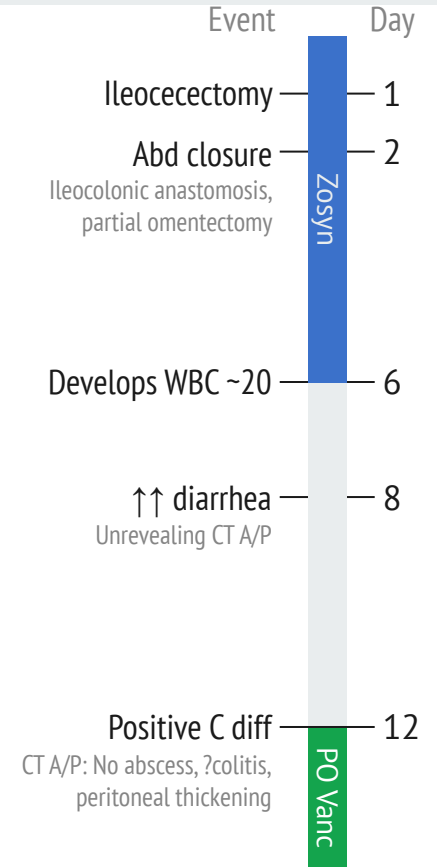
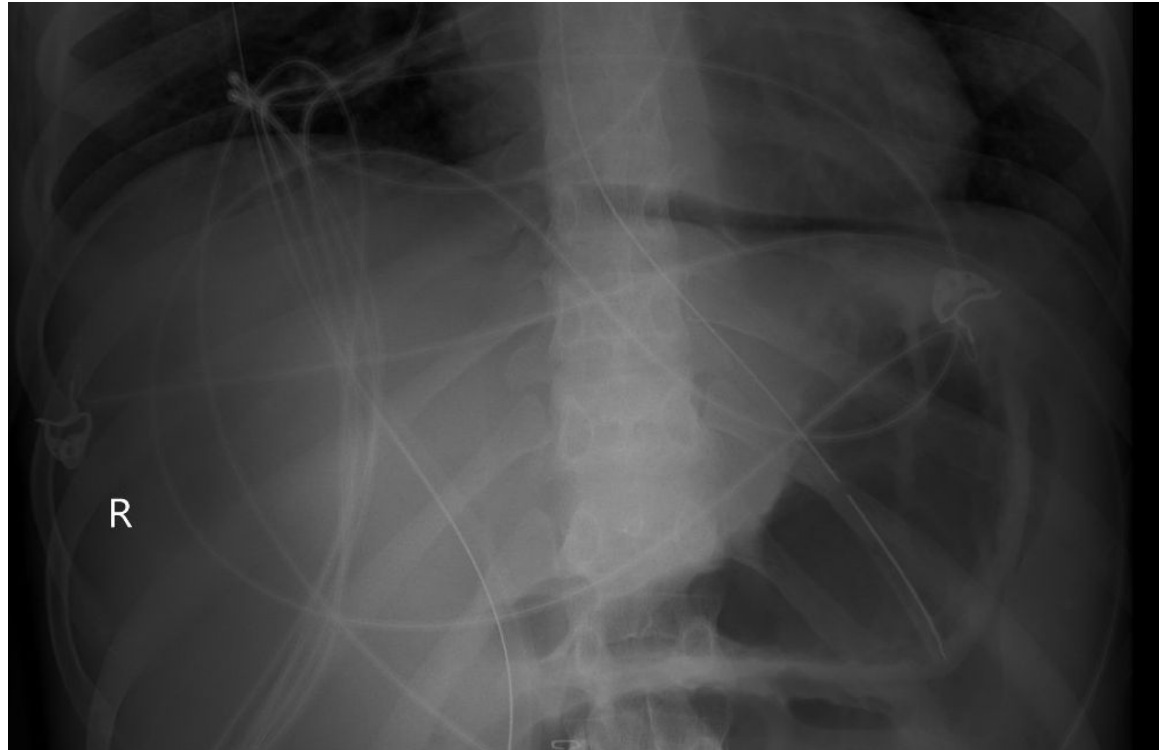
Due to *ongoing leukocytosis*:

- **Positive C diff** → Start PO vanc
- Repeat CT scan → No abscess, maybe colitis, some peritoneal thickening

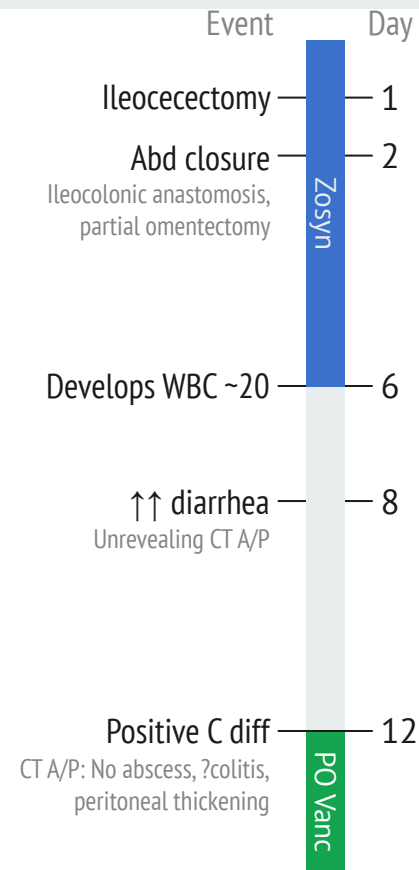
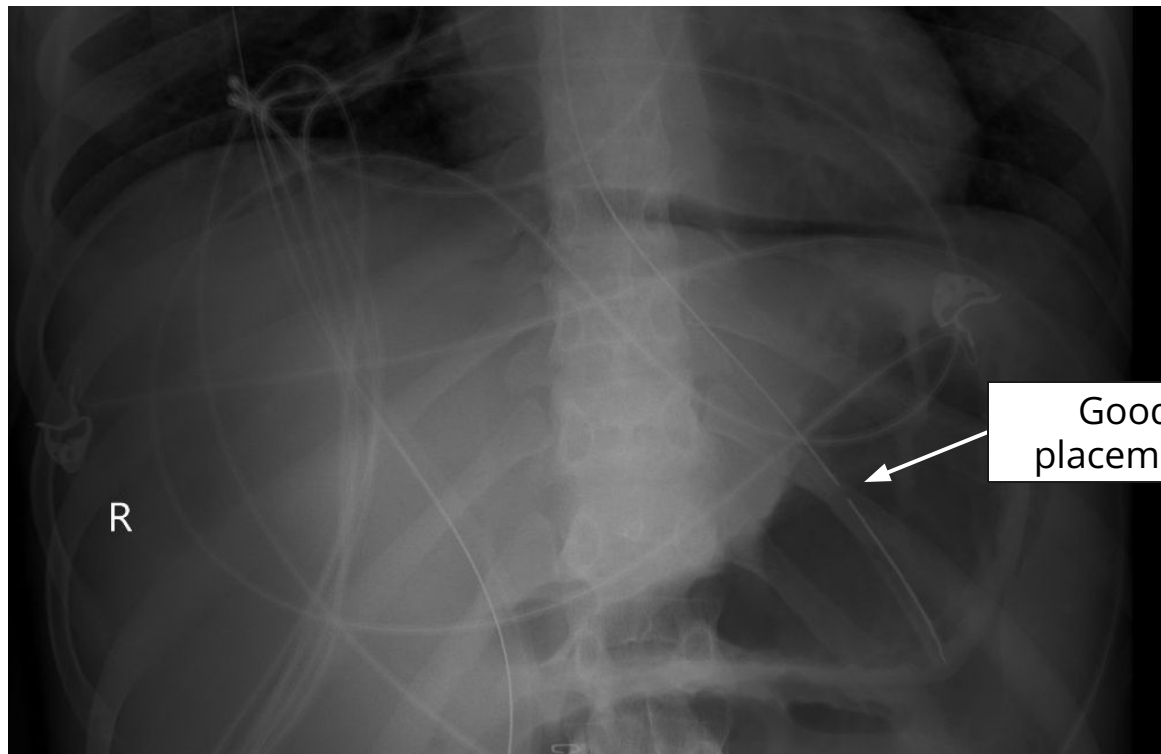
Next day, **ordered a KUB** to check dobhoff...



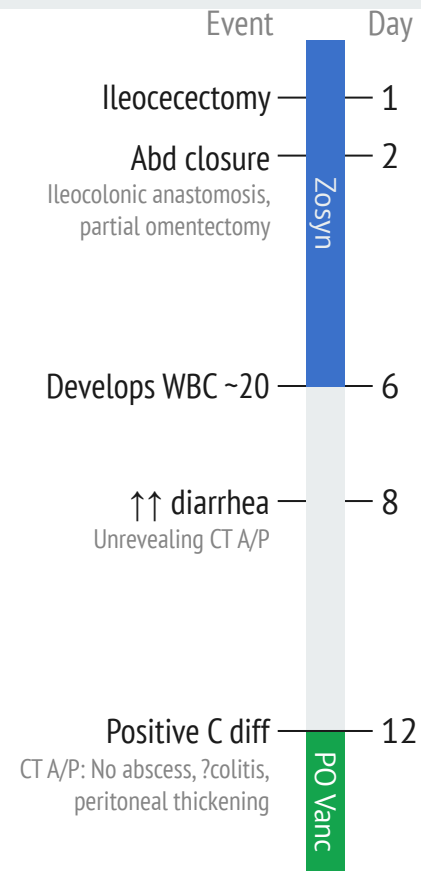
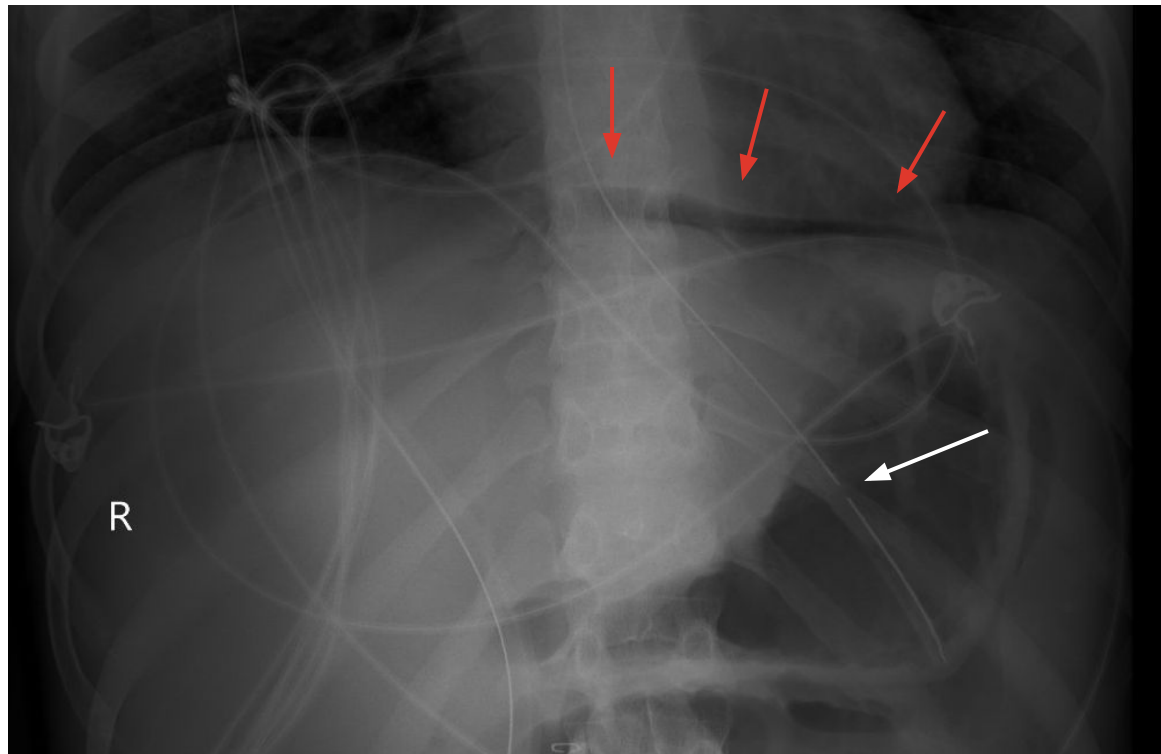
Case 1: Post-operative course



Case 1: Post-operative course



Case 1: Post-operative course



Case 1: Post-operative course

Finished 4 days of Zosyn (from source control)

- Shortly after, develops leukocytosis to the 17-20 range
- Then increased diarrhea
 - CT A/P (IV contrast only) at this time is unrevealing

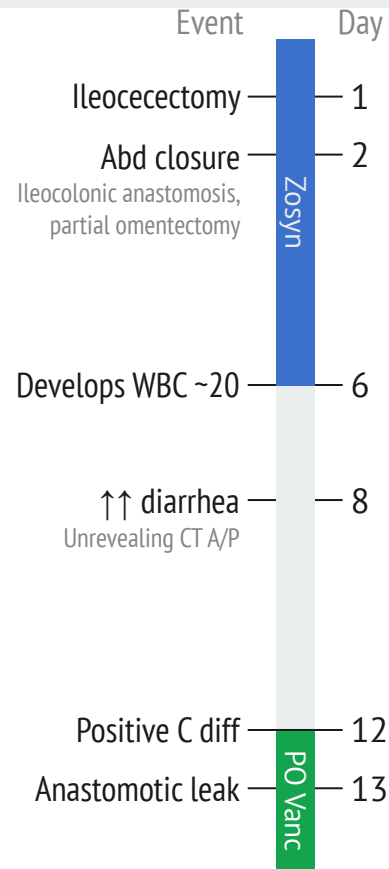
Due to *ongoing leukocytosis*:

- Positive C diff → Start PO vanc
- Repeat CT scan → No abscess, maybe colitis, some peritoneal thickening

↑↑ **pneumoperitoneum on KUB** → Repeat CT scan

CT A/P (Day 13)

↑↑ pneumoperitoneum & ↑↑ rim-enhancing fluid/ascites with **significant free air adjacent to the ileocolonic anastomosis** suspicious for **anastomotic leak**



Case 1: Post-operative course

Finished 4 days of Zosyn (from source control)

- Shortly after, develops leukocytosis to the 17-20 range
- Then increased diarrhea
 - CT A/P (IV contrast only) at this time is unrevealing

Due to *ongoing leukocytosis*:

- Positive C diff → Start PO vanc
- Repeat CT scan → No abscess, maybe colitis, some peritoneal thickening

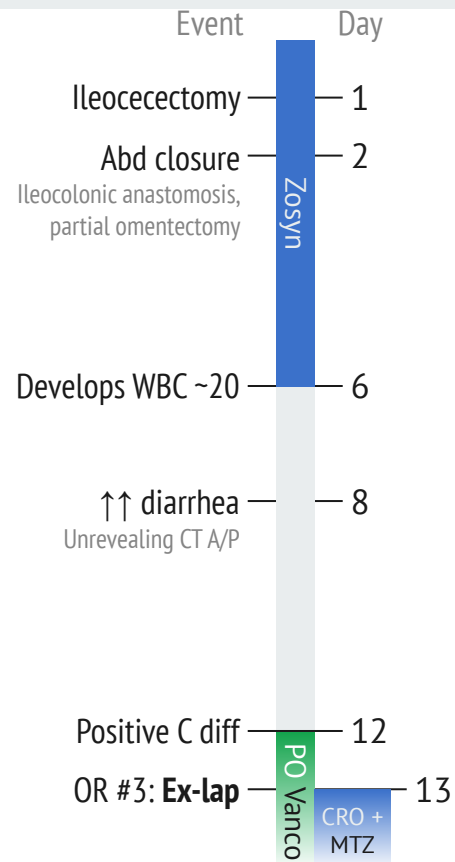
↑↑ **pneumoperitoneum on KUB** → **Ex-lap**

Procedure:

1. Reopening recent exlap
2. Abdominal washout
3. Partial omentectomy
4. Application of Abthera

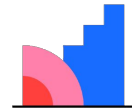
Operative Report

1.5 L of **purulent ascites, foul smelling**, no clear evidence of enteric contents. Fibrinous adhesions throughout. **Necrotic appearing omentum**



[Q1.2] Which pathogens need to be covered?

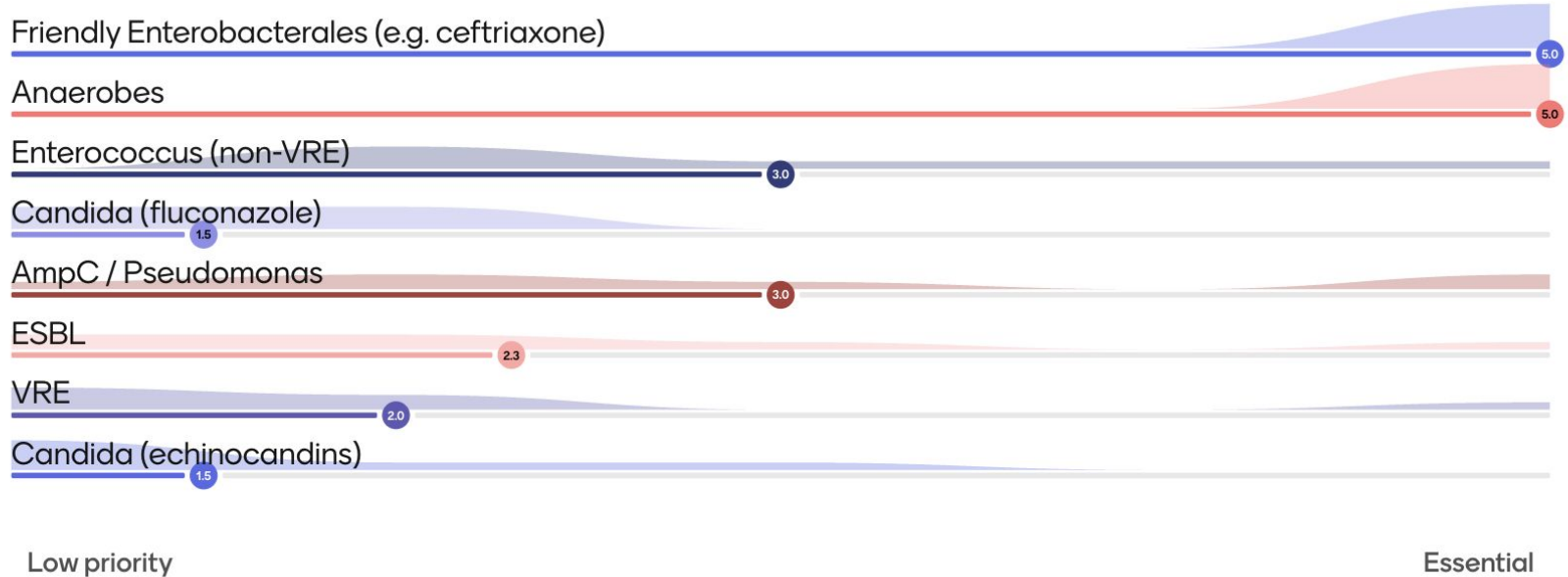
Scales slider



Mentimeter

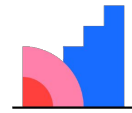
1. Friendly Enterobacterales (e.g. ceftriaxone)
2. Anaerobes
3. Enterococcus (non-VRE)
4. Candida (fluconazole)
5. AmpC / Pseudomonas
6. ESBL
7. VRE
8. Candida (echinocandins)

[Q1.2] How strongly do you feel we need to cover...



**[Q1.3] Given C diff +
perf, would you feel
the need to cover C
diff outside of the
bowel?**

Multiple choice, all that apply



Mentimeter

1. Not at all
2. Flagyl (IV) would suffice
3. Vancomycin (IV) would suffice
4. Peritoneal cavity lavage with fidaxomicin!!

[Q1.3] Theoretically, do you feel we need to cover C diff outside of the bowel lumen?



3 Not at all



3 Flagyl (IV) would suffice



1 Vancomycin (IV) would suffice

0 Peritoneal cavity lavage with fidaxomicin!!

Case 1: Post-operative course

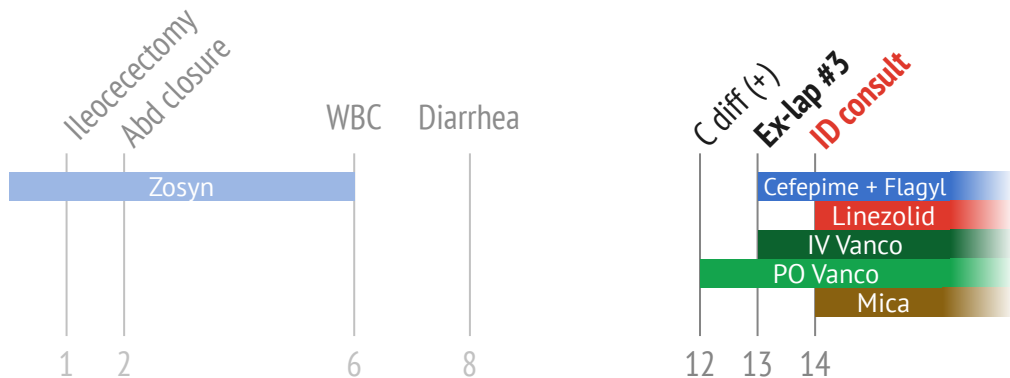
We are consulted, and follow him through **numerous trips to the OR**

Operative Report (#3)

1.5 L of **purulent ascites**, **foul smelling**, no clear evidence of enteric contents. Fibrinous adhesions throughout. **Necrotic appearing omentum**

Procedures: (#3)

1. Reopening recent exlap
2. Abdominal washout
3. Partial omentectomy
4. Application of Abthera



Case 1: Post-operative course

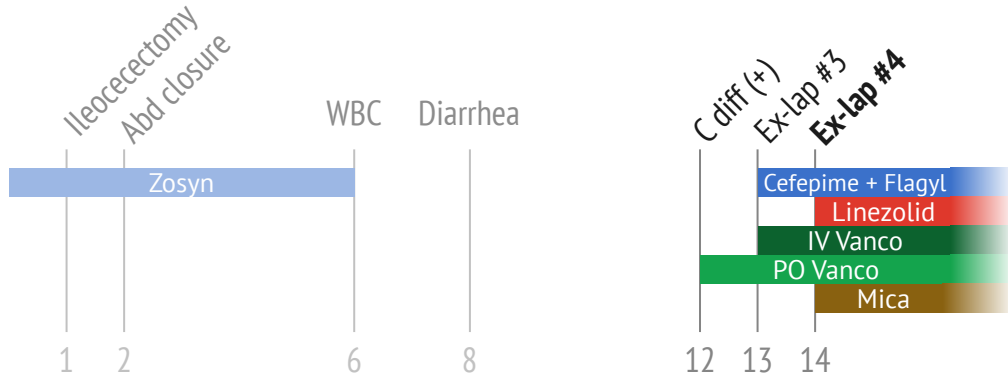
We are consulted, and follow him through **numerous trips to the OR**

Operative Report (#4)

Malodorous purulent ascites with **necrotizing peritoneum** most notably in the RLQ. **Purulent pockets released** between loops of small bowel

Procedures: (#4)

1. Reopening recent exlap
2. Abdominal washout
3. Peritoneal debridement
4. Application of Abthera



Case 1: Post-operative course

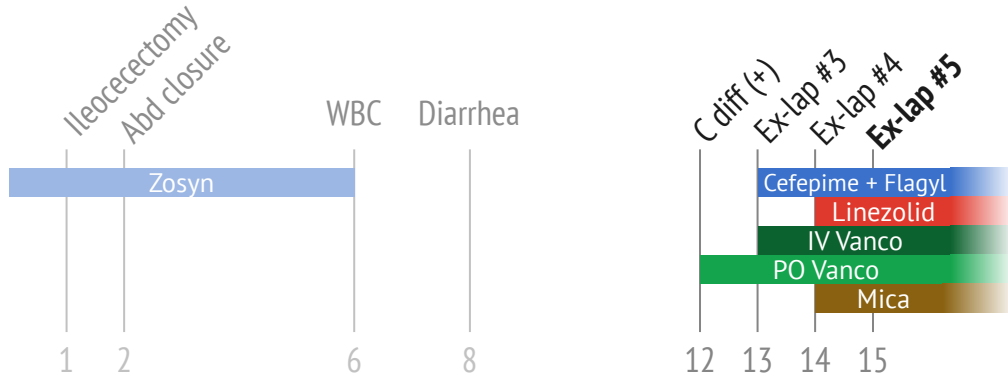
We are consulted, and follow him through **numerous trips to the OR**

Operative Report (#5)

Improvement in purulent ascites. There were **still multiple interloop fluid pockets** and fibrinous exudate. The **peritoneum was drastically improved**, pink and viable appearing

Procedures: (#5)

1. Reopening recent exlap
2. Abdominal washout
3. Temporary abdominal closure with AbThera



Case 1: Post-operative course

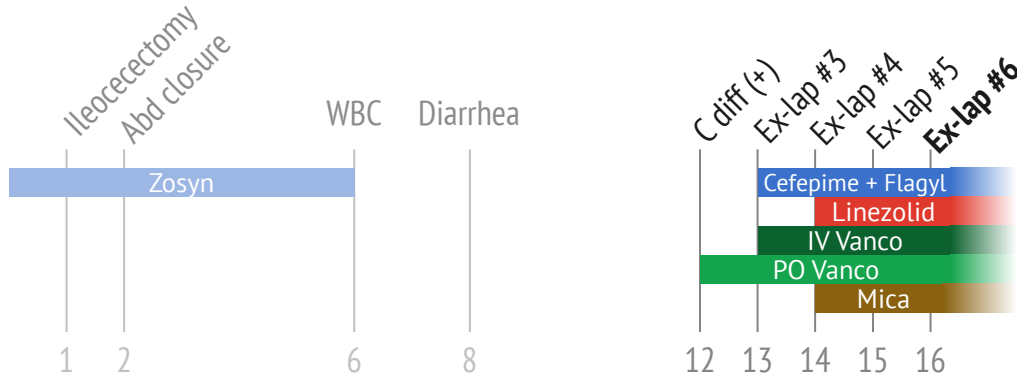
We are consulted, and follow him through **numerous trips to the OR**

Operative Report (#6)

Only **slightly murky**, though nonbilious, **fluid in pelvis**. Newly appreciated **bile staining to loops of small bowel** in proximity to RLQ. No enterotomy seen. **Anastomosis intact** w/ excellent perfusion diffusely. **Fascia closed**

Procedures: (#6)

1. Reopening recent exlap
2. Abdominal washout
3. Spy angiography
4. Wound vac application to abdominal wound
5. Abdominal closure



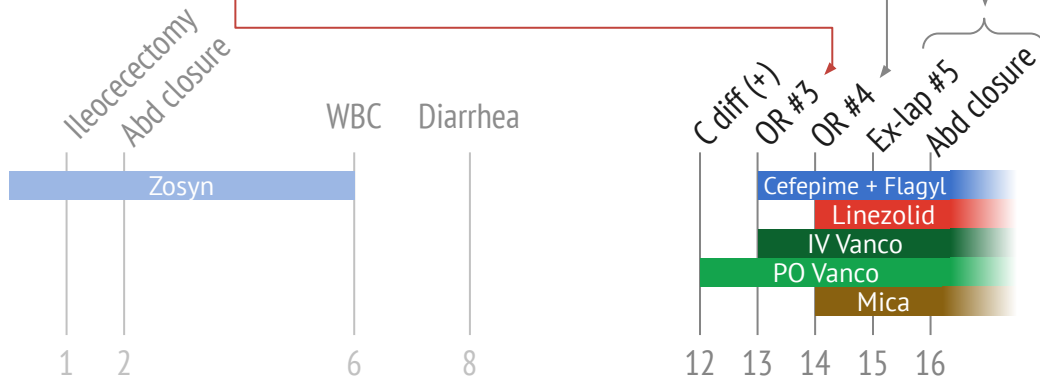
Case 1: Post-operative course

Multiple laparotomies → closure on day 16

Ex-lap #3: Day 13
 3+ Strep Anginosus
 2+ E faecalis
 2+ E coli
 3+ Mixed anaerobes

Ex-lap #4: Day 14
 1+ Strep Anginosus
 2+ E faecalis
 2+ E coli
 2+ Mixed anaerobes

Ex-laps #5 & 6:
 No micro sent

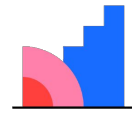


	E coli	E faecalis
Ampicillin	Resist	S
Amox/clav	Int	---
Pip/tazo	S	---
Cefazolin	Resist	---
Ceftriaxone	S	---
Ceftaz	S	---
Cefepime	S	---
Carbapenems	S	---
Quinolones	S	---
Aminogly	S	Synergy
Tetracycline	Resist	---
Tigecycline	---	S
TMP/SMX	S	---
Daptomycin	---	S
Linezolid	---	S
Vancomycin	---	S

	Anaerobes	Strep anginosus
No suscept	---	---

[Q1.4] Minimum duration of therapy

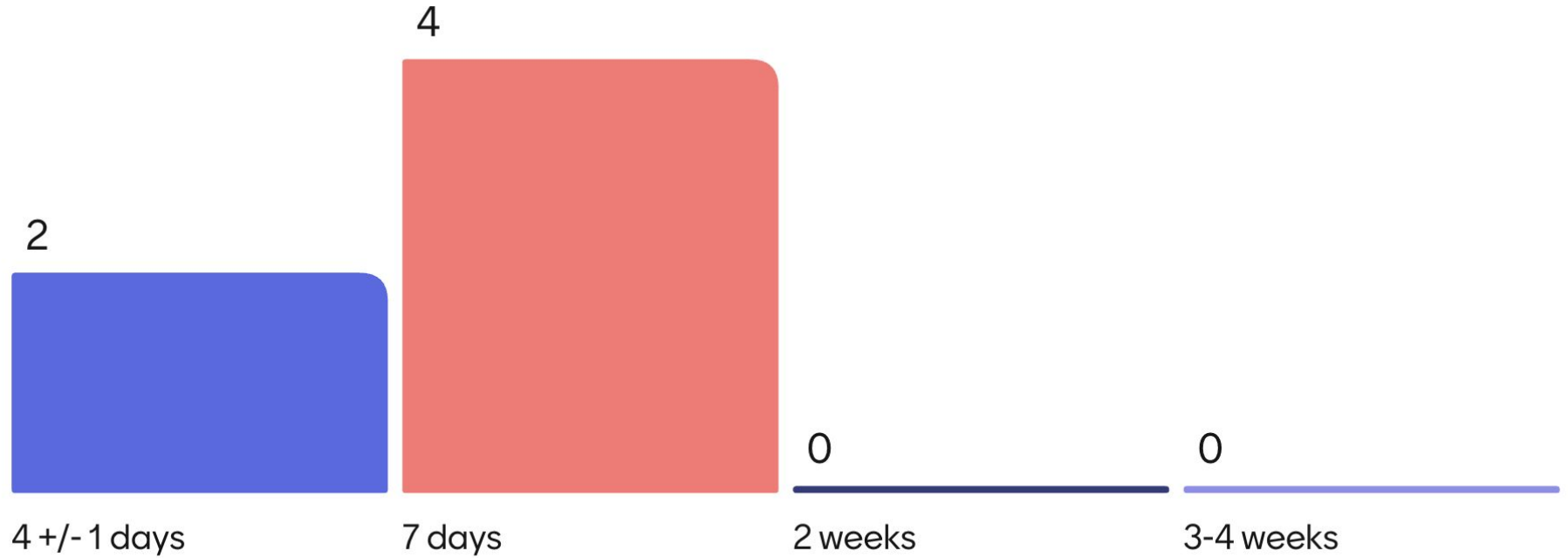
Multiple choice



Mentimeter

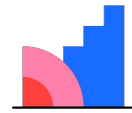
- 4 +/- 1 days
- 1 week
- 2 weeks
- 3-4 weeks

[Q1.4] What is your minimum duration?



[Q1.5] What will guide your decision to stop antimicrobials?

Assign 100 points

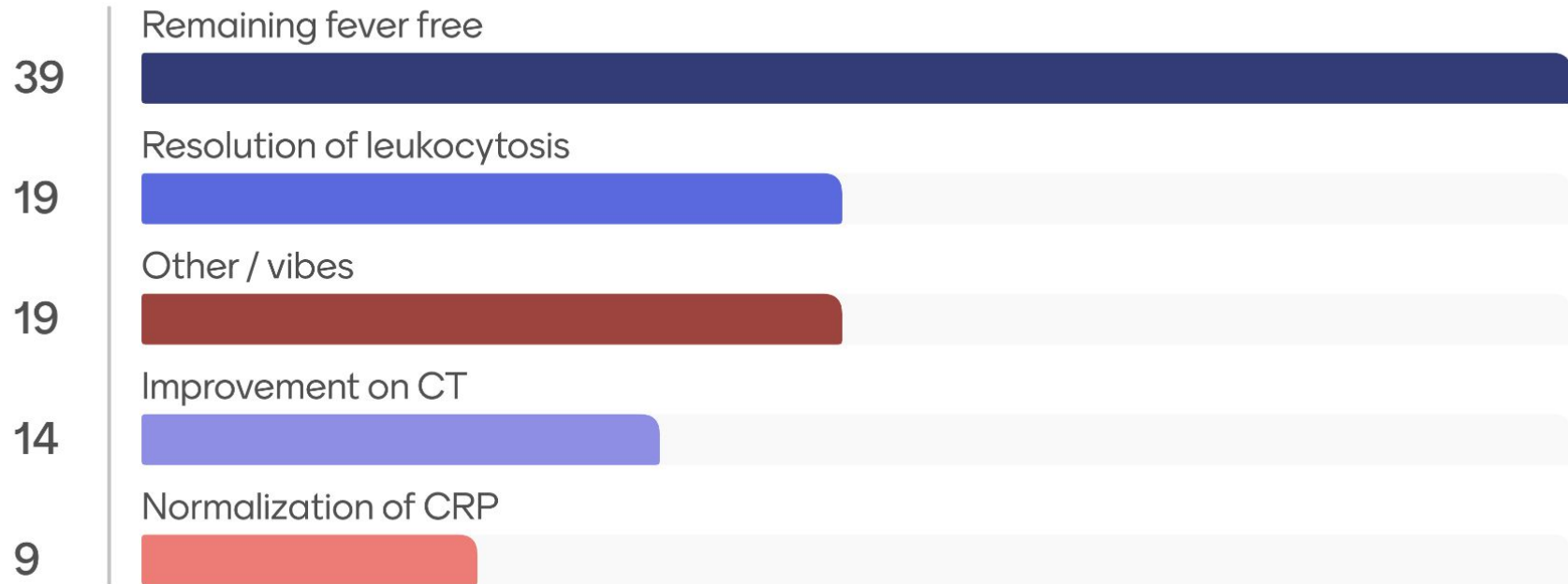


Mentimeter

- Resolution of WBC
- Normalizing the CRP
- Fever free
- Radiographic findings
- "Vibes"

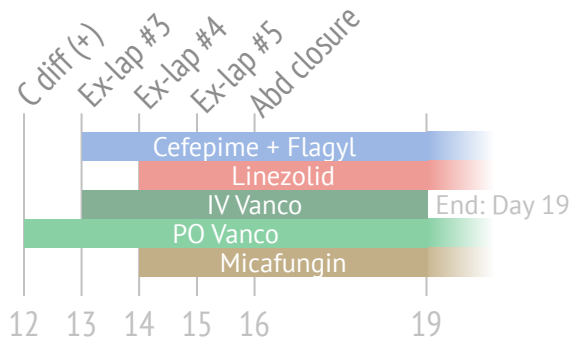
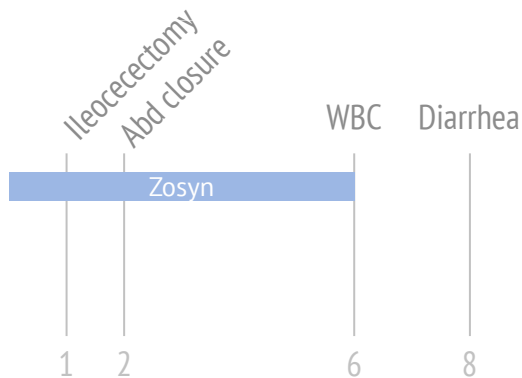
Alternatively what are you closely watching that may make you extend Tx?

[Q1.5] What will you use to guide the **decision to stop**?



Case 1: Post-operative course

Concerns that **enteric contents** may be coming from one of the JP drains..?



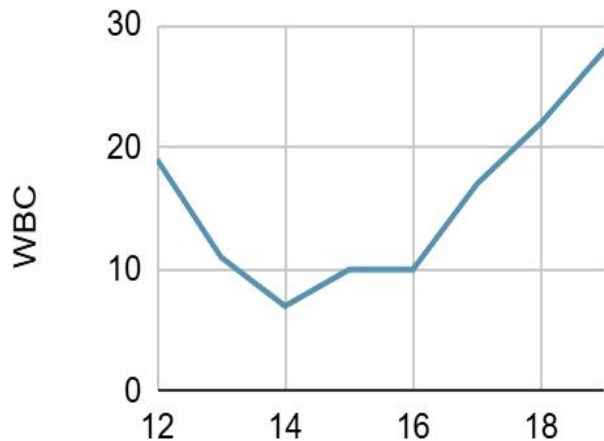
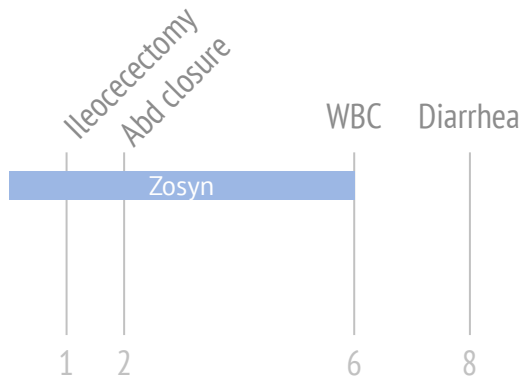
From OR #3	E coli	E faecalis
Ampicillin	Resist	S
Amox/clav	Int	---
Pip/tazo	S	---
Ceftriaxone	S	---
Cefepime	S	---
Carbapenems	S	---
Quinolones	S	---
Aminogly	S	Synergy
Tetracycline	Resist	---
Daptomycin	---	S
Linezolid	---	S
Vancomycin	---	S

3+ Strep anginosus

3+ Mixed anaerobes

Case 1: Post-operative course

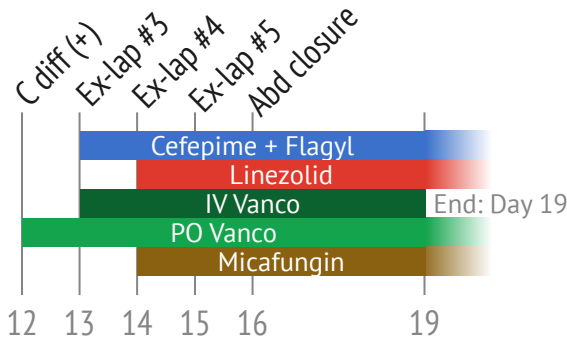
Concerns that **enteric contents** may be coming from one of the JP drains..?



From OR #3	E coli	E faecalis
Ampicillin	Resist	S
Amox/clav	Int	---
Pip/tazo	S	---
Ceftriaxone	S	---
Cefepime	S	---
Carbapenems	S	---
Quinolones	S	---
Aminogly	S	Synergy
Tetracycline	Resist	---
Daptomycin	---	S
Linezolid	---	S
Vancomycin	---	S

3+ Strep anginosus

3+ Mixed anaerobes



Case 1: Post-operative course

Concerns that **enteric contents** may be coming from one of the JP drains..?

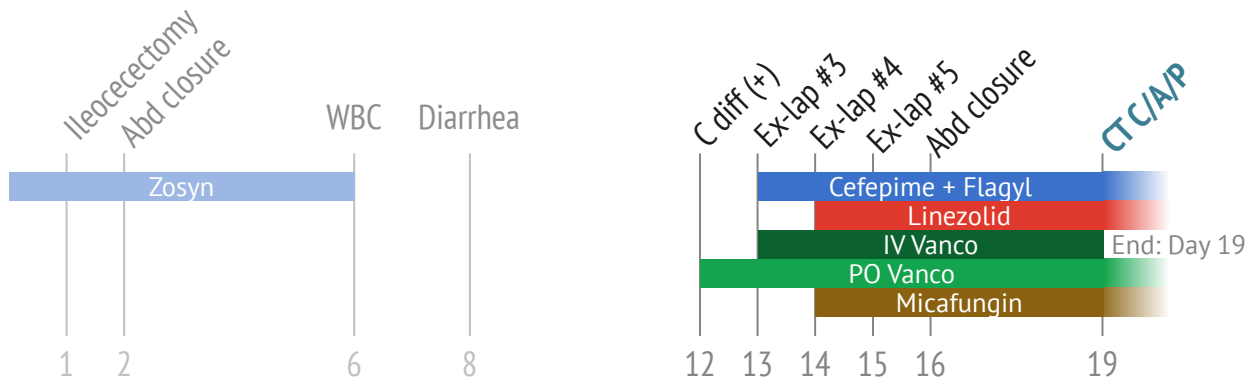
CT A/P (Day 19)

Bilateral drains in the abdomen. Small **loculated fluid collection anterior to bladder** (might be in the abdominal wall), measures **3.6 x 1.3 x 3.3 cm** with **small foci of air**

From OR #3	E coli	E faecalis
Ampicillin	Resist	S
Amox/clav	Int	---
Pip/tazo	S	---
Ceftriaxone	S	---
Cefepime	S	---
Carbapenems	S	---
Quinolones	S	---
Aminogly	S	Synergy
Tetracycline	Resist	---
Daptomycin	---	S
Linezolid	---	S
Vancomycin	---	S

3+ Strep anginosus

3+ Mixed anaerobes

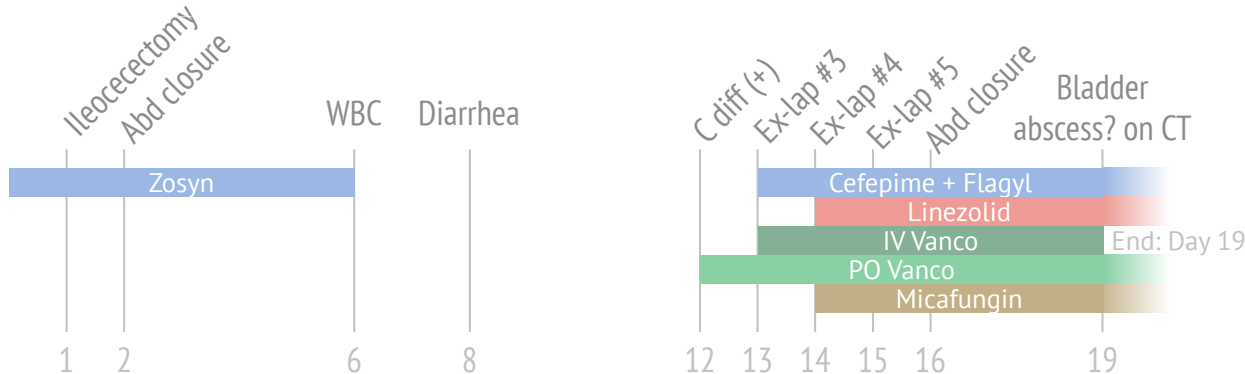


Case 1: After sign off

Sign off recommendations

- Stop **micafungin**
- Continue **cefepime + Flagyl + Zyvox**
 - At **least 14 days** from last OR
 - Call back if no source control (**did not ask them to call IR**)
- Continue **PO vanc taper for 10 days** after finishing systemic antibiotics

CT A/P (Day 19)
3.6 cm loculated collection anterior to bladder



From OR #3	E coli	E faecalis
Ampicillin	Resist	S
Amox/clav	Int	---
Pip/tazo	S	---
Ceftriaxone	S	---
Cefepime	S	---
Carbapenems	S	---
Quinolones	S	---
Aminogly	S	Synergy
Tetracycline	Resist	---
Daptomycin	---	S
Linezolid	---	S
Vancomycin	---	S
3+ Strep anginosus		
3+ Mixed anaerobes		

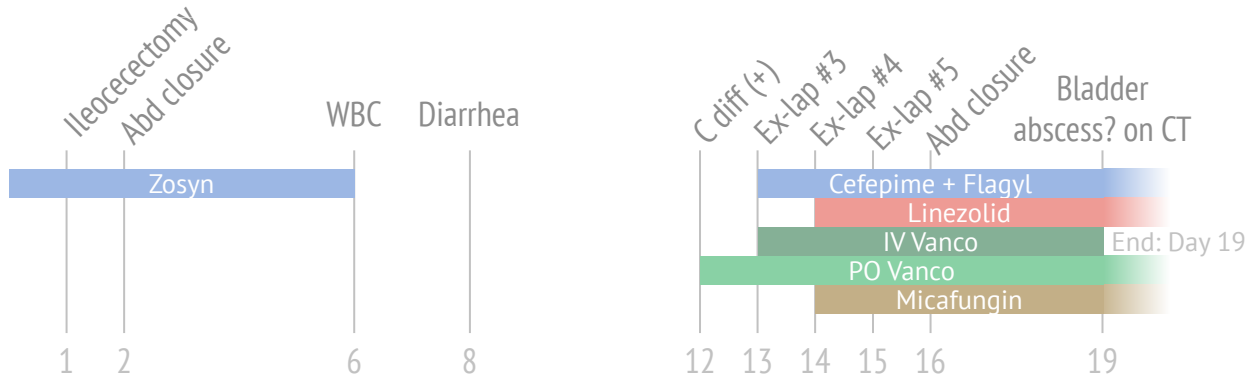
Case 1: After sign off

Sign off recommendations

- Stop **miconazole**
- Continue **cefepime + Flagyl + Zyvox**
 - At **least 14 days** from last OR
 - Call back if no source control (**did not ask them to call IR**)
- Continue **PO vanc taper for 10 days** after finishing systemic antibiotics

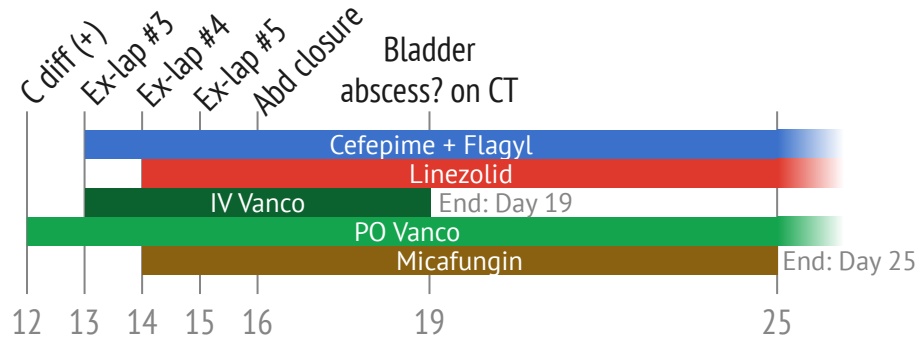
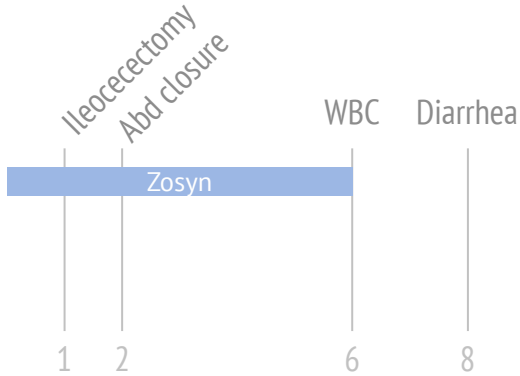
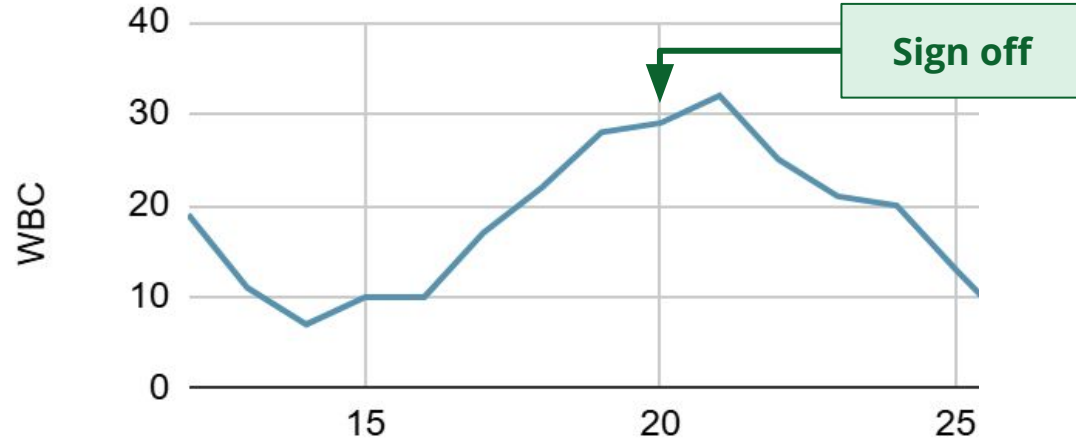Do you agree with this plan?

CT A/P (Day 19)
3.6 cm loculated collection anterior to bladder

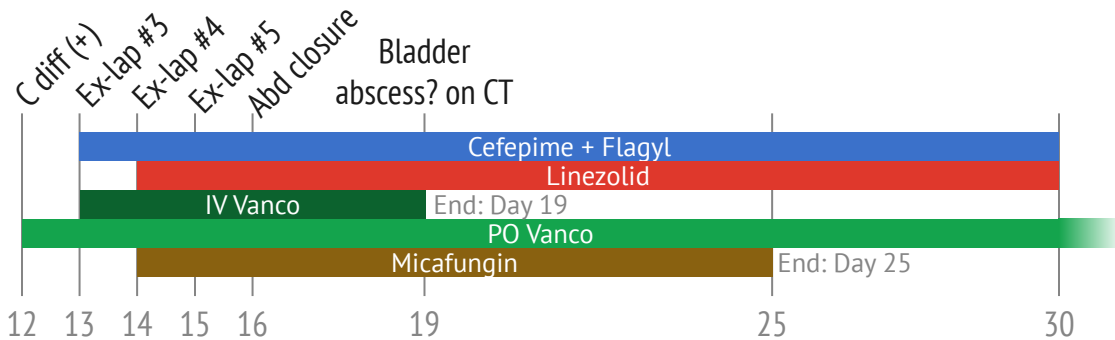
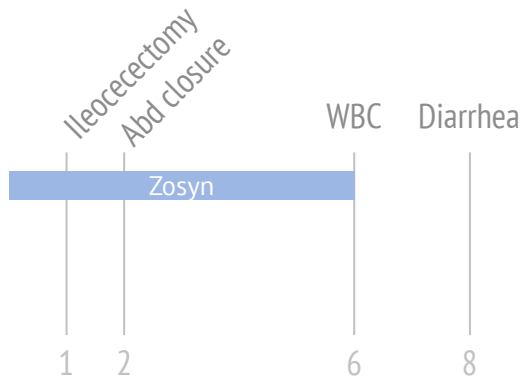
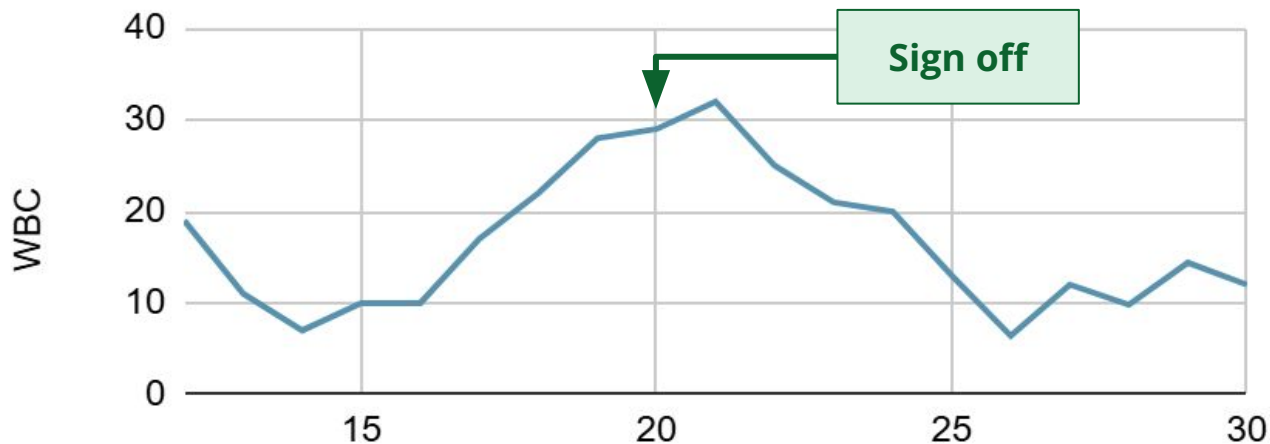
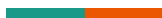

From OR #3	E coli	E faecalis
Ampicillin	Resist	S
Amox/clav	Int	---
Pip/tazo	S	---
Ceftriaxone	S	---
Cefepime	S	---
Carbapenems	S	---
Quinolones	S	---
Aminogly	S	Synergy
Tetracycline	Resist	---
Daptomycin	---	S
Linezolid	---	S
Vancomycin	---	S
3+ Strep anginosus		
3+ Mixed anaerobes		

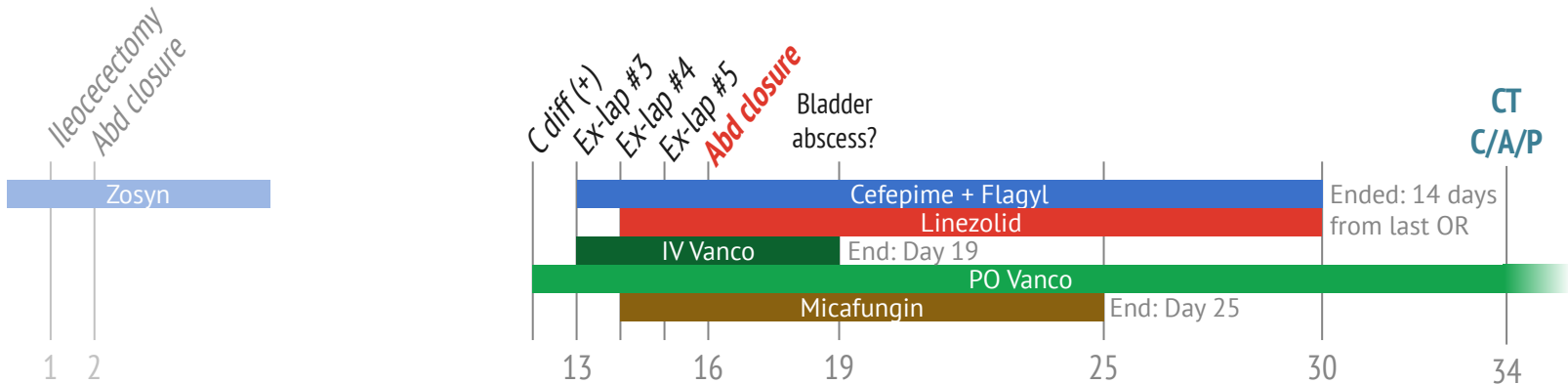
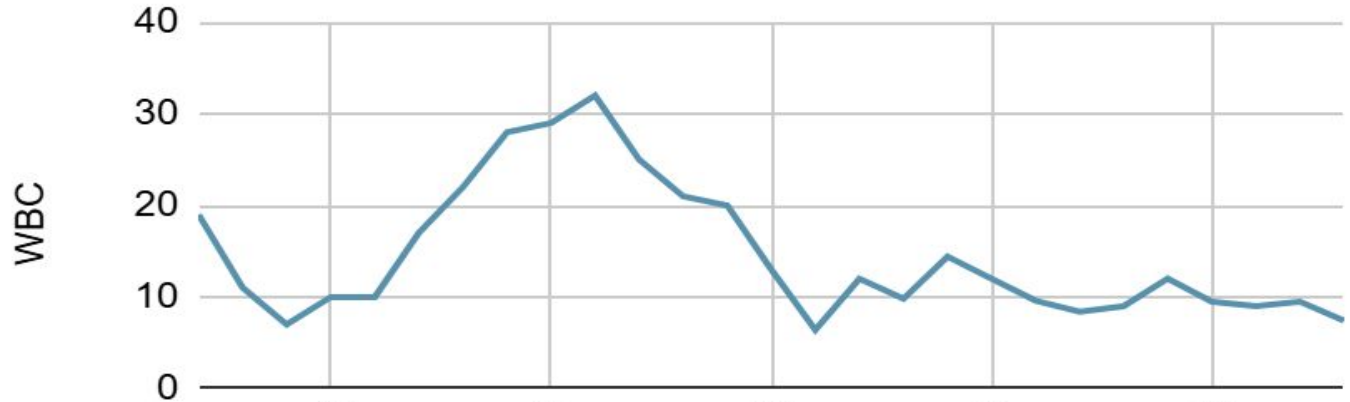
Case 1: After sign off



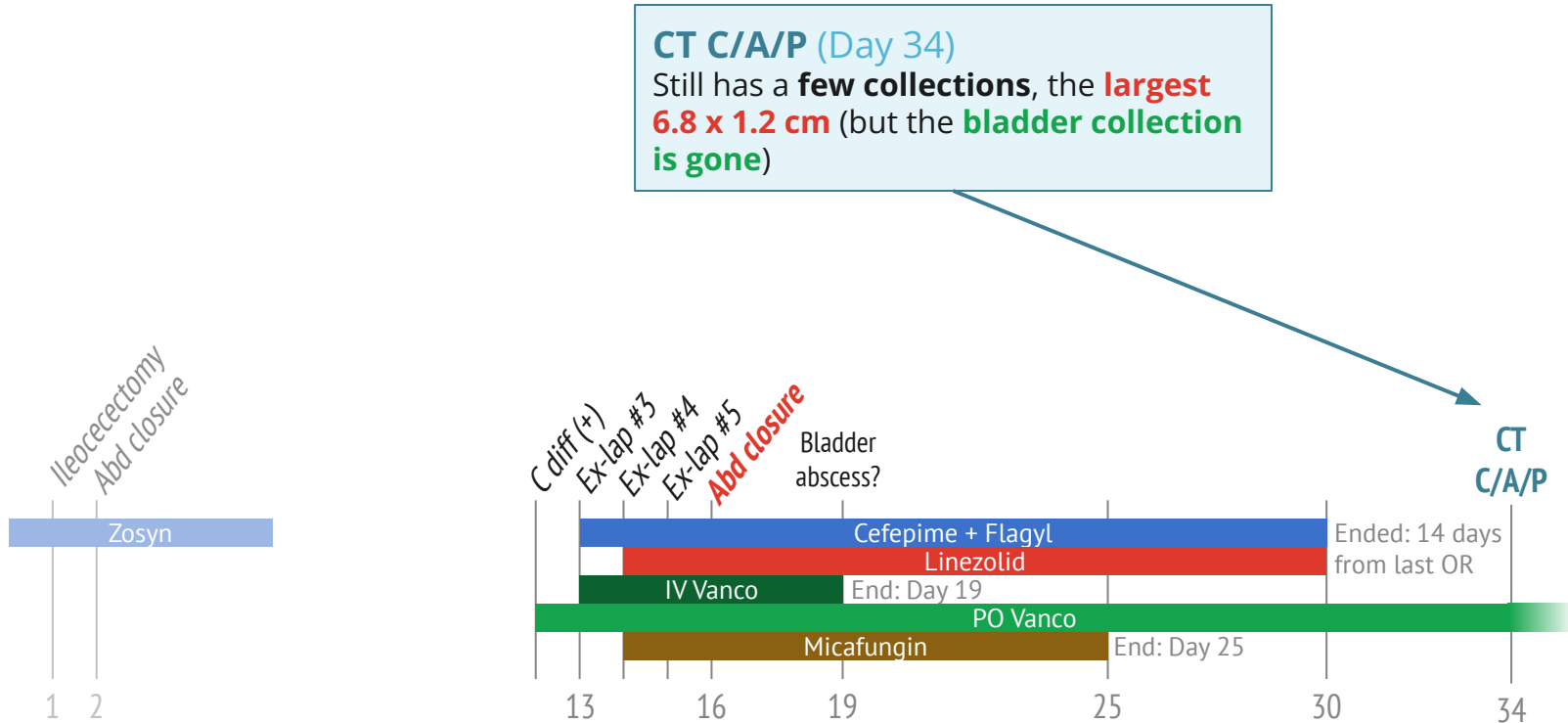
Case 1: After sign off



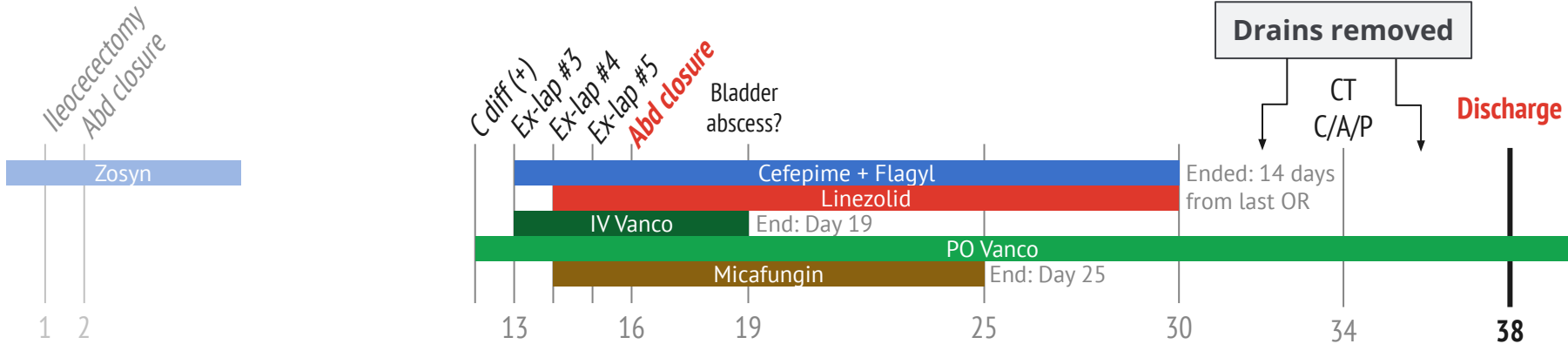
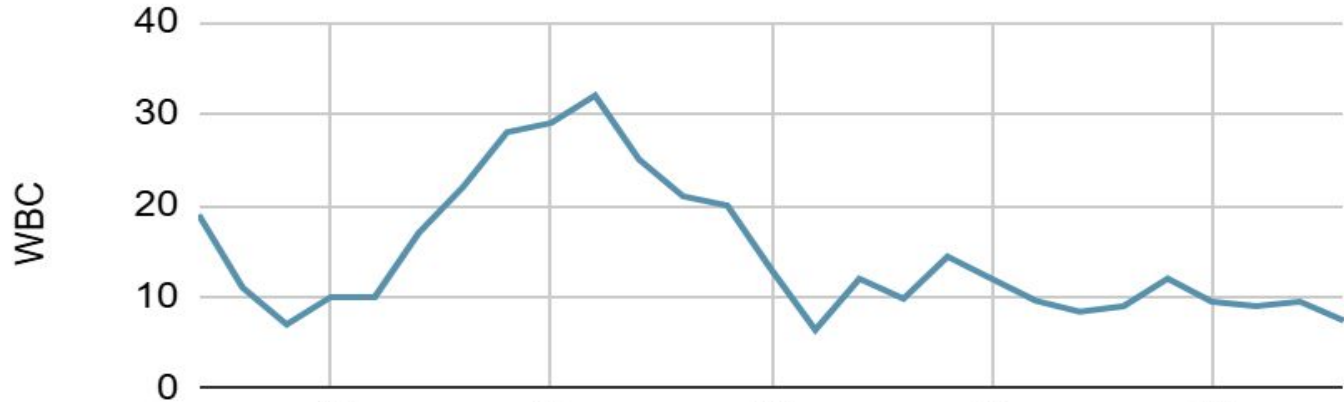
Case 1: After antibiotics finished



Case 1: After antibiotics finished



Case 1: After antibiotics finished



Case #2

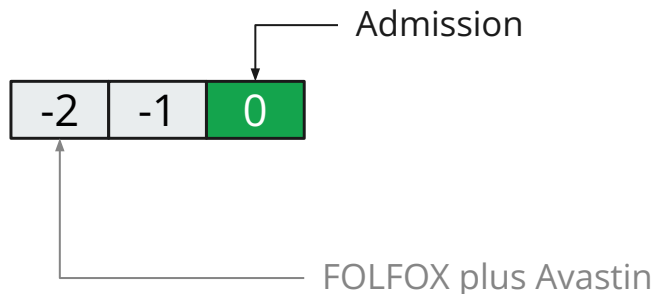
Case 2: Initial care

A **52 y/o F** with PMH including metastatic rectal cancer on chemotherapy p/w **rectal pain** & **septic shock**

Case 2: Initial care

A **52 y/o F** with PMH including metastatic rectal cancer on chemotherapy p/w **rectal pain & septic shock**

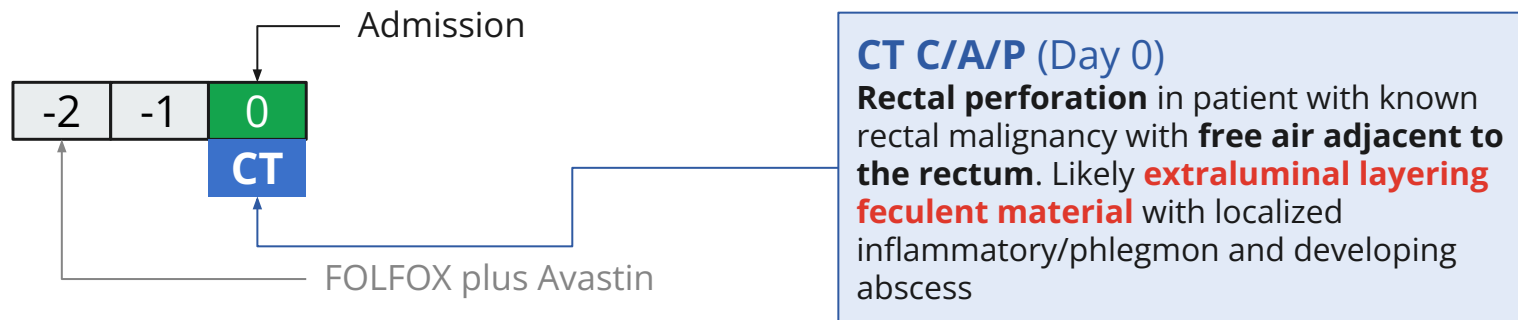
- Last dose of **chemo** (FOLFOX plus Avastin) was **2 days before admission** (AKA **day 0**)
- Leukopenic (0.8) and hypotensive on admission → **Admitted to SICU**



Case 2: Initial care

A **52 y/o F** with PMH including metastatic rectal cancer on chemotherapy p/w **rectal pain** & **septic shock**

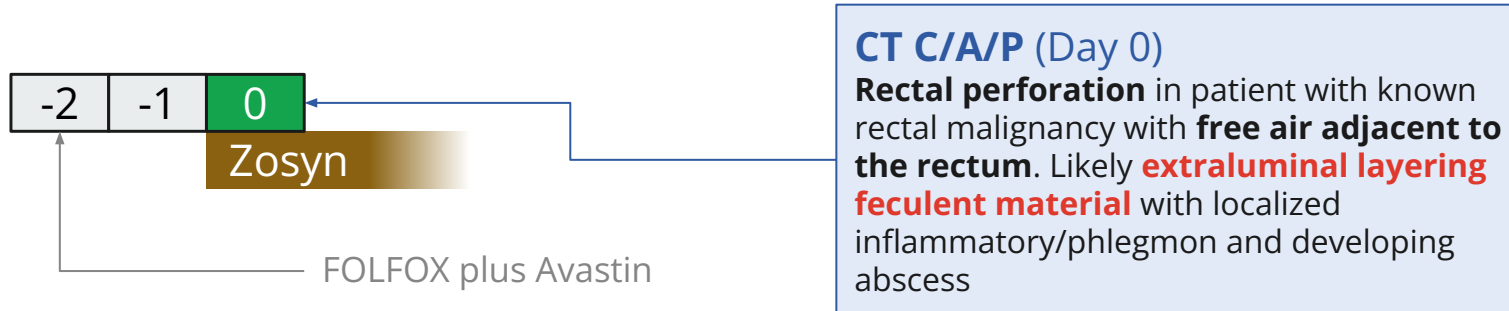
- Last dose of **chemo** (FOLFOX plus Avastin) was **2 days before admission**
- Leukopenic (0.8) and hypotensive on admission → **Admitted to SICU**
- **CT C/A/P** showed **rectal perforation**



Case 2: Initial care

A **52 y/o F** with PMH including metastatic rectal cancer on chemotherapy p/w **rectal pain** & **septic shock**

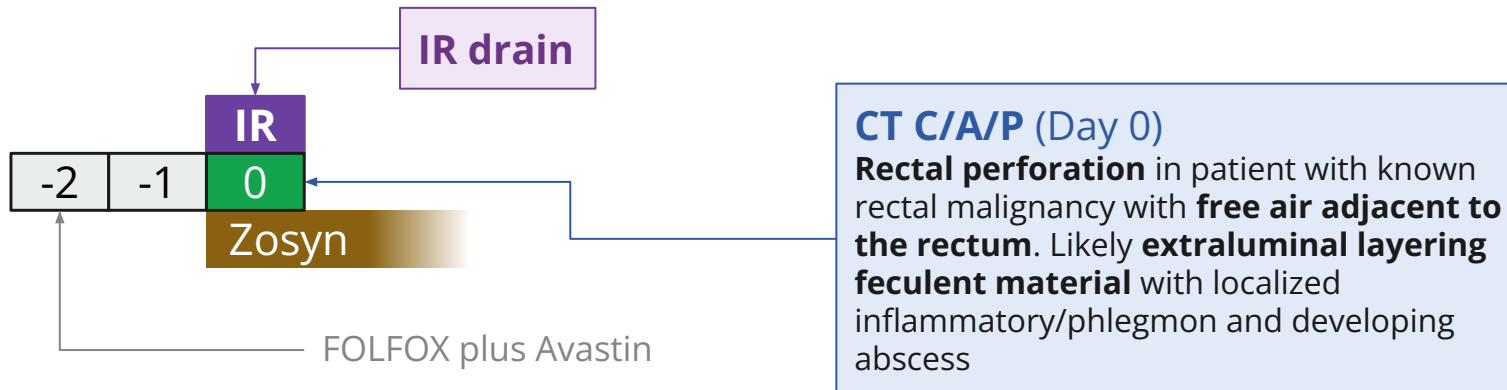
- Last dose of **chemo** (FOLFOX plus Avastin) was **2 days before admission**
- Leukopenic (0.8) and hypotensive on admission → **Admitted to SICU**
- **CT C/A/P** showed **rectal perforation** → Started on **Zosyn**



Case 2: Initial care

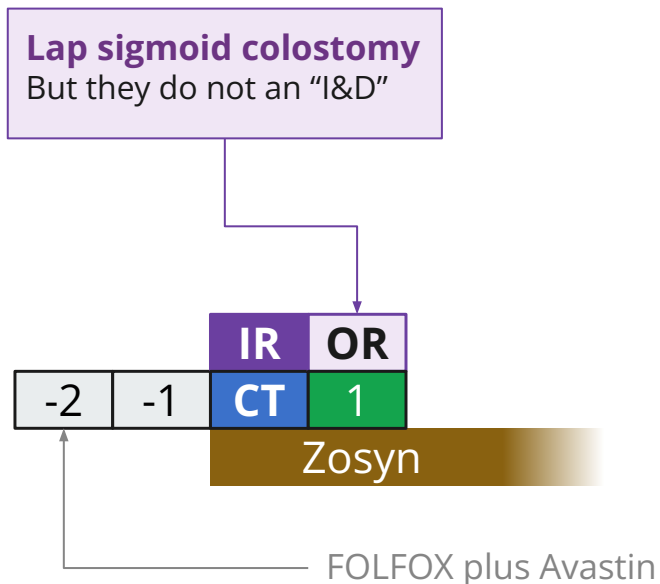
A **52 y/o F** with PMH including metastatic rectal cancer on chemotherapy p/w **rectal pain** & **septic shock**

- Last dose of **chemo** (FOLFOX plus Avastin) was **2 days before admission**
- Leukopenic (0.8) and hypotensive on admission → **Admitted to SICU**
- **CT C/A/P** showed **rectal perforation** → Started on **Zosyn**
- **Percutaneous drain** placed by IR



Case 2: Initial care

A 52 y/o F with PMH including metastatic rectal cancer on chemo p/w sepsis from **rectal perf**



CT C/A/P (Day 0)

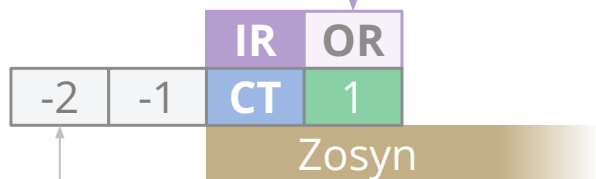
Rectal perforation w/ free air in mesorectum.
Extraluminal layering feculent material with developing abscess

Case 2: Initial care

A 52 y/o F with PMH including metastatic rectal cancer on chemo p/w sepsis from **rectal perf**

There was **some slightly murky ascites** fluid but **no pus or stool** or evidence of peritoneal contamination...

Lap sigmoid colostomy
But they do not an "I&D"



FOLFOX plus Avastin

CT C/A/P (Day 0)

Rectal perforation w/ free air in mesorectum.
Extraluminal layering feculent material with developing abscess

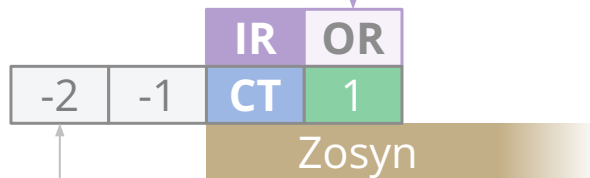
Case 2: Initial care

A 52 y/o F with PMH including metastatic rectal cancer on chemo p/w sepsis from **rectal perf**

Lap sigmoid colostomy

But they do not an "I&D"

There was **some slightly murky ascites** fluid but **no pus or stool** or evidence of peritoneal contamination...We proceeded to mobilize the lateral attachments of the sigmoid colon to the **inner-sigmoidal fossa** and **deepened this dissection** to mobilize along the white line.



FOLFOX plus Avastin

White line of Toldt

The **layer of fascia** that **separates the mesocolon** (layer of fatty tissue and connective tissue that surrounds colon) & **retroperitoneum**

CT C/A/P (Day 0)

Rectal perforation w/ free air in mesorectum.
Extraluminal layering feculent material with developing abscess

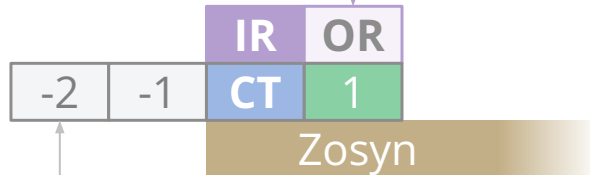
Case 2: Initial care

A 52 y/o F with PMH including metastatic rectal cancer on chemo p/w sepsis from **rectal perf**

Lap sigmoid colostomy

But they do not an "I&D"

There was **some slightly murky ascites** fluid but **no pus or stool** or evidence of peritoneal contamination...We proceeded to mobilize the lateral attachments of the sigmoid colon to the **inner-sigmoidal fossa** and deepened this dissection to mobilize along the white line. There was induration/**edema underlying this from the perforation** that **I did not want to unroof** so **I limited the dissection** once we felt that we had good length for a loop colostomy



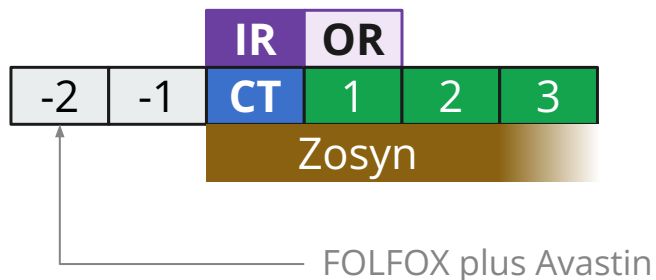
FOLFOX plus Avastin

CT C/A/P (Day 0)

Rectal perforation w/ free air in mesorectum.
Extraluminal layering feculent material with developing abscess

Case 2: Post-op

- Did well post-op
- Off of pressors & transferred out of SICU



CT C/A/P (Day 0)

Rectal perforation w/ free air in mesorectum.

Extraluminal layering feculent material with developing abscess

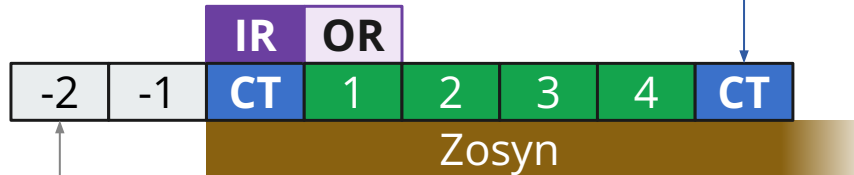
BOWEL: There is free air adjacent to the rectum contains within the subperitoneal space

PERITONEAL CAVITY: Trace free fluid adjacent to the rectum with free peritoneal air

Case 2: Post-op

CT A/P (Day 5)

Interval placement of drain into the complex **perirectal and presacral abscess** with **mildly decreased size** of the complex collection (largest measures **5.7 x 3.5 cm**)



FOLFOX plus Avastin

BOWEL: No bowel obstruction. Circumferential wall thickening of the mid to distal rectum corresponds to the known rectal malignancy. There are postsurgical changes from creation of an descending loop colostomy.

There is a complex collection of extraluminal fluid and air within the mesorectum which extends posteriorly along the presacral soft tissues which is concerning for rectal perforation with associated abscess/phlegmonous changes. Since [CT on Day 0], there has been interval placement of a transgluteal approach pigtail drain into the left aspect of the mesorectum with decreased complex fluid and air. The largest pocket of residual complex fluid and air measures 5.7 x 3.5 cm.

PERITONEAL CAVITY: No intraperitoneal free air is visible.

CT C/A/P (Day 0)

Rectal perforation w/ free air in mesorectum.
Extraluminal layering feculent material with developing abscess

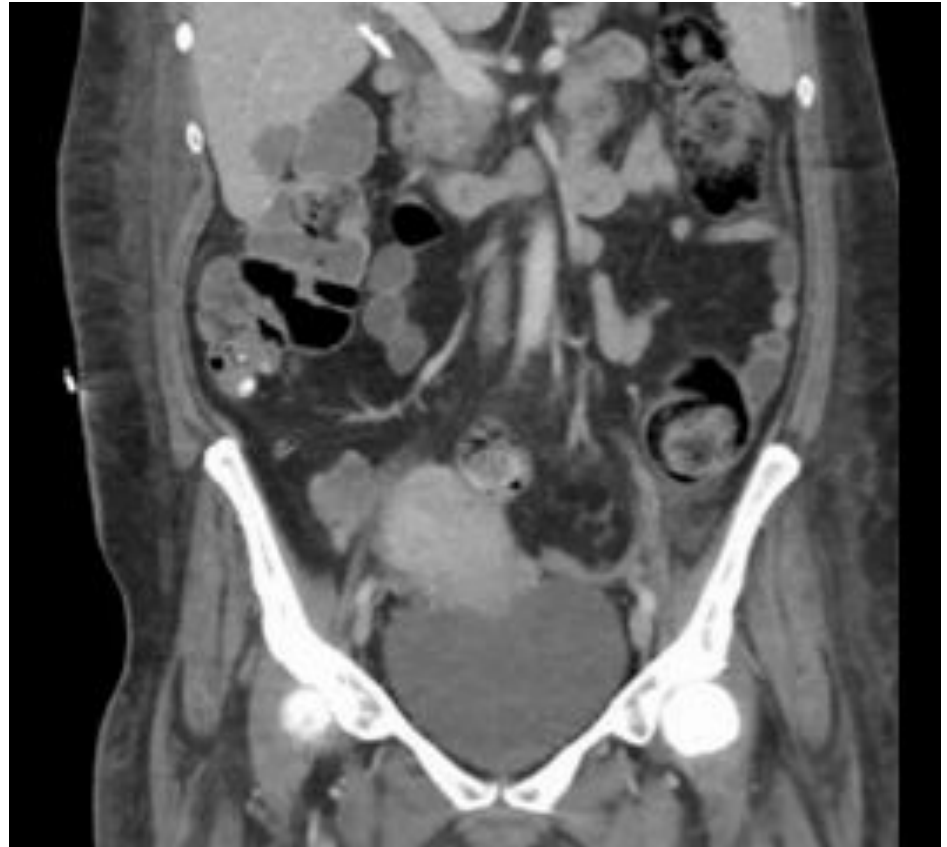
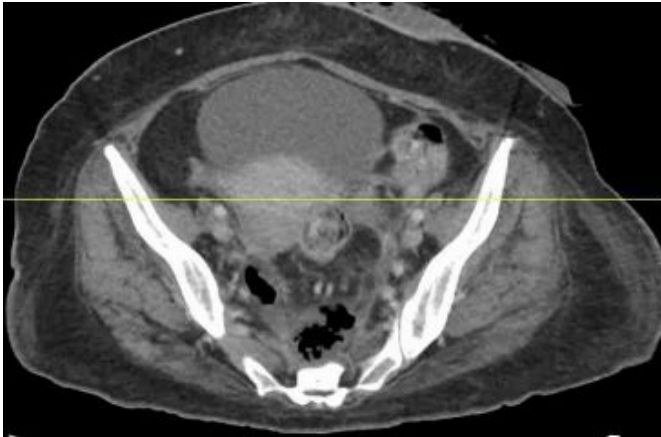
BOWEL: There is free air adjacent to the rectum contains within the subperitoneal space

PERITONEAL CAVITY: Trace free fluid adjacent to the rectum with free peritoneal air

Case 2: Post-op

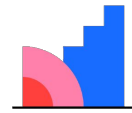
CT A/P (Day 5)

Interval placement of drain into the complex **perirectal and presacral abscess** with **mildly decreased size** of the complex collection (largest measures **5.7 x 3.5 cm**)



[Q2.1] Do we have source control? In the sense that...

Likert



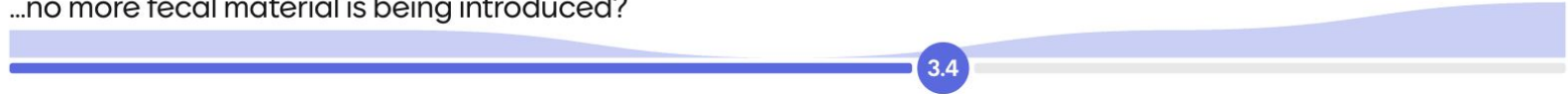Mentimeter

Teasing out to difference between preventing ongoing contamination, restoring normal anatomy, and eliminating the focus of infection

- ...no more fecal material is being introduced?
- ...all of the infected material is out of the abdomen?
- ...the IR drain will prevent collection from enlarging?
- ...a JP drain will eventually eliminate the bio-burden?

[Q2.1] Do we have source control? In the sense that...


...no more fecal material is being introduced?



...all of the infected material is out of the abdomen?



...the IR drain will prevent collection from enlarging?



...a JP drain will eventually eliminate the bio-burden?

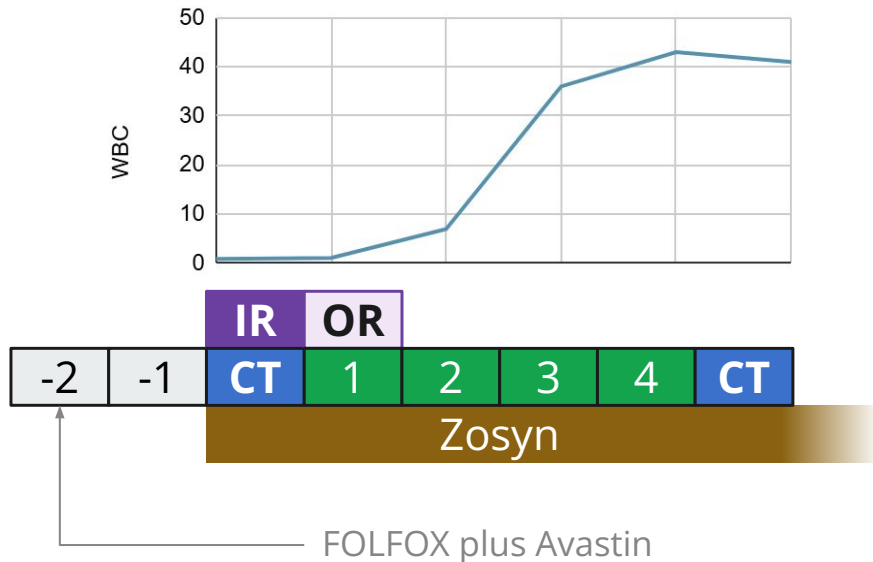


Strongly disagree

Strongly agree

Case 2: Initial care

A 52 y/o F with PMH including metastatic rectal cancer on chemo p/w sepsis from **rectal perf**



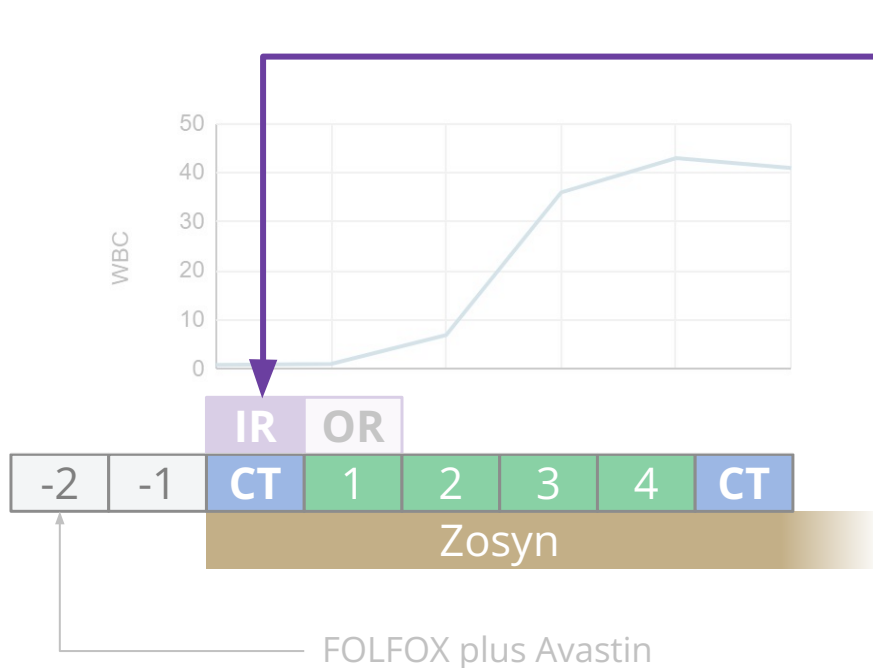
CT A/P (Day 5)

Interval placement of drain into the complex **perirectal and presacral abscess** with **mildly decreased size** of the complex collection (largest measures **5.7 x 3.5 cm**)

CT C/A/P (Day 0)

Rectal perforation w/ free air in mesorectum. **Extraluminal layering feculent material** with developing abscess

Case 2: Initial care



IR drain	3+ E coli	3+ E coli	3+ strep mitis	3+ strep anginosus
Ampicillin	Resist	S	S	S
Amox/clav	S	S	---	---
Pip/tazo	S	S	---	---
Cefazolin	Resist	---	---	---
Ceftriaxone	S	S	S	S
Ceftaz	S	S	---	---
Cefepime	S	S	---	---
Carbapenems	S	S	---	---
Quinolones	Resist	S	S	S
Aminogly	S	S	---	---
Tetracycline	S	S	Resist	S
TMP/SMX	Resist	S	---	---
Penicillin	---	---	S	S
Vancomycin	---	---	S	S

[Q2.2] What to treat with?

Multiple choice, **two parts**



Select one:

- Unasyn
- Ceftriaxone + Flagyl
- Zosyn
- Cefepime + Flagyl
- Carbapenem

Add one or more:

- Linezolid
- Daptomycin
- Antifungals
- N/A

For agents like Unasyn & ceftriaxone, assume PO transition is an option

[Q2.2][A] What to treat with?



1 Unasyn



4 Ceftriaxone + Flagyl

0 Zosyn

0 Cefepime + Flagyl

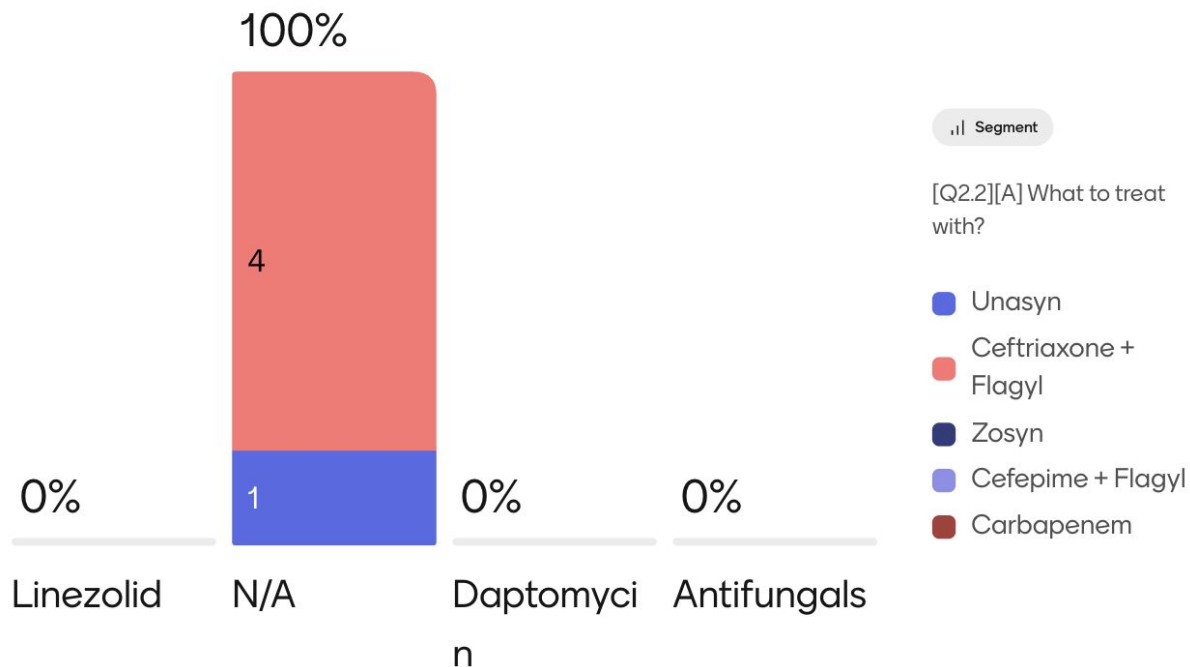
0 Carbapenem

IR drain	3+ E coli
Ampicillin	Resist
Amox/clav	S
Pip/tazo	S
Cefazolin	Resist
Ceftriaxone	S
Ceftaz	S
Cefepime	S
Carbapenems	S
Quinolones	Resist
Aminogly	S
Tetracycline	S
TMP/SMX	Resist
Penicillin	---
Vancomycin	---

3+ **Strep mitis** (S-PCN)

3+ **Strep anginosus** (S-PCN)

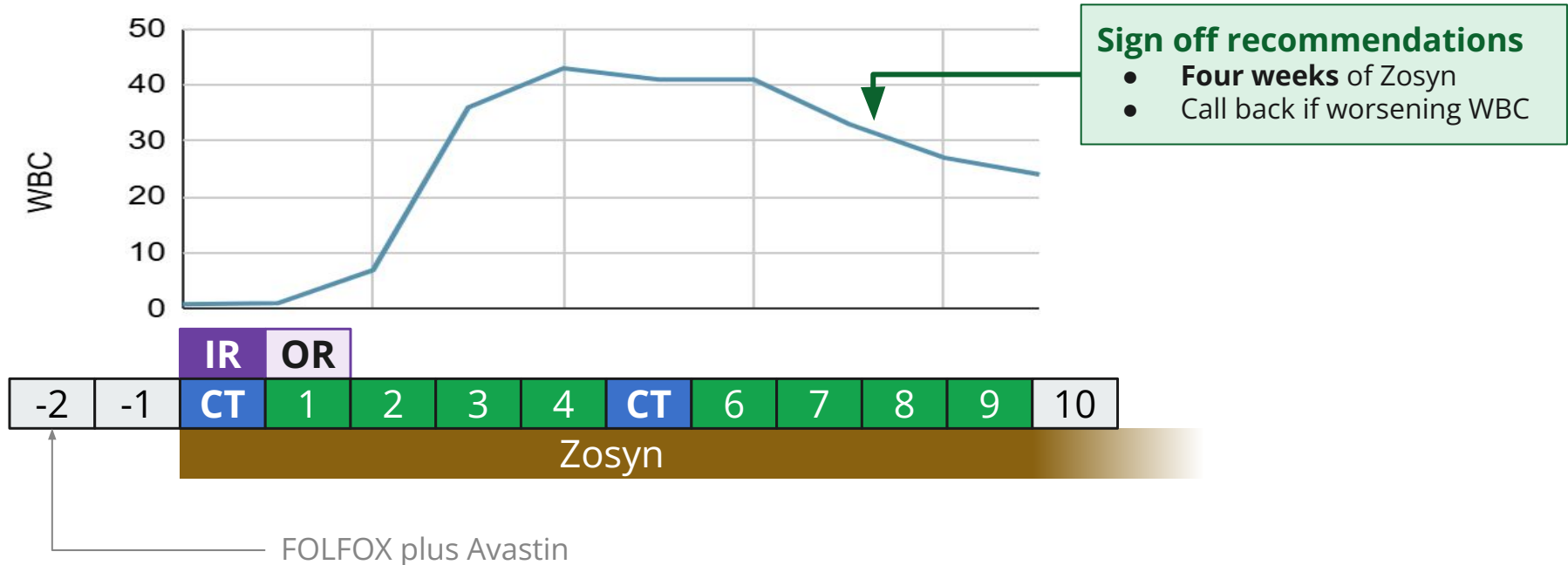
[Q2.2][B] Anything to add?



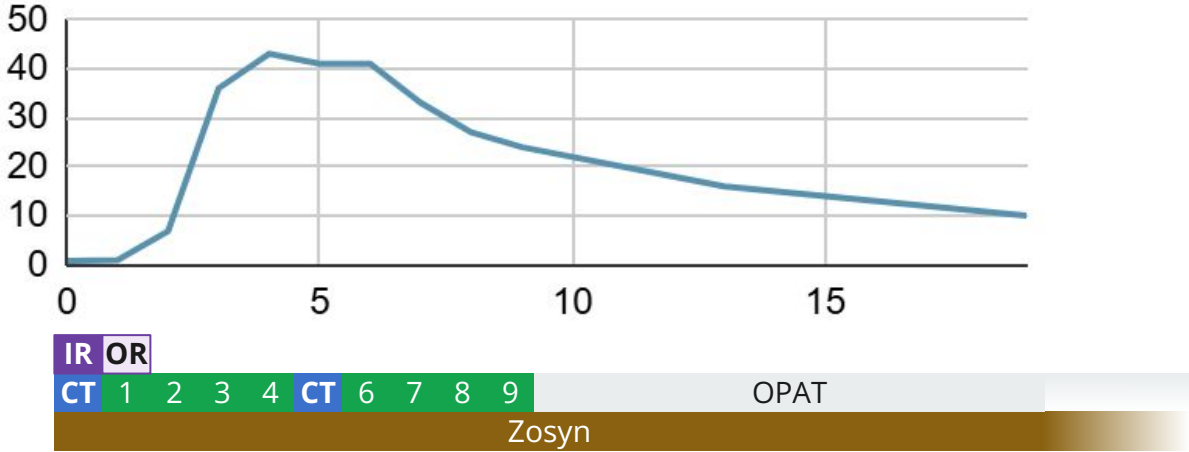
IR drain	3+ E coli
Ampicillin	Resist
Amox/clav	S
Pip/tazo	S
Cefazolin	Resist
Ceftriaxone	S
Ceftaz	S
Cefepime	S
Carbapenems	S
Quinolones	Resist
Aminogly	S
Tetracycline	S
TMP/SMX	Resist
Penicillin	---
Vancomycin	---
3+ Strep mitis (S-PCN)	
3+ Strep anginosus (S-PCN)	

Case 2: Hospital course

A 52 y/o F with PMH including metastatic rectal cancer on chemo p/w sepsis from **rectal perf**



Case 2: OPAT



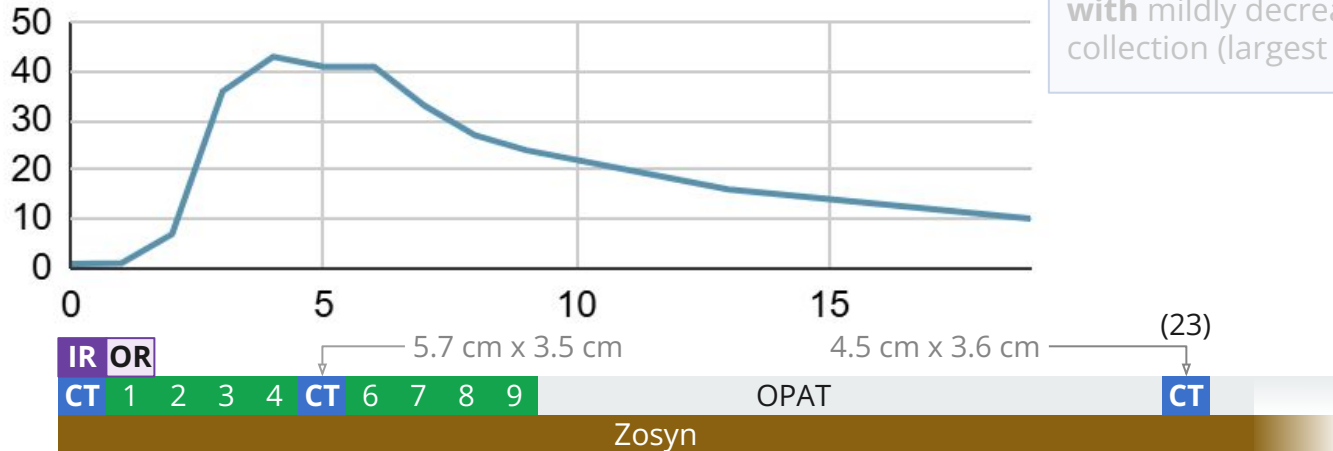
Case 2: OPAT

CT A/P (Day 23)

Residual presacral fluid collection containing air **measuring up to 4.5 cm**; Otherwise, the extensive perirectal collections with air are **significantly decreased in size**

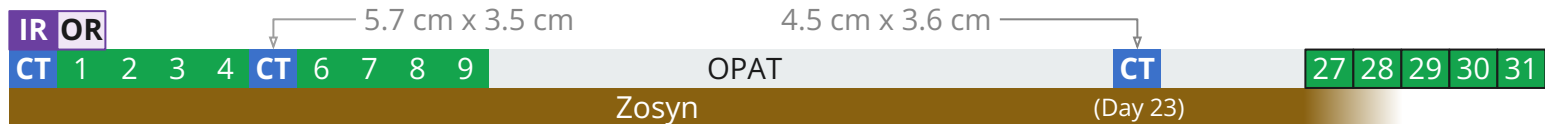
CT A/P (Day 5)

Interval placement of drain into the complex **perirectal and presacral abscess** with mildly decreased size of the complex collection (largest measures **5.7 x 3.5 cm**)



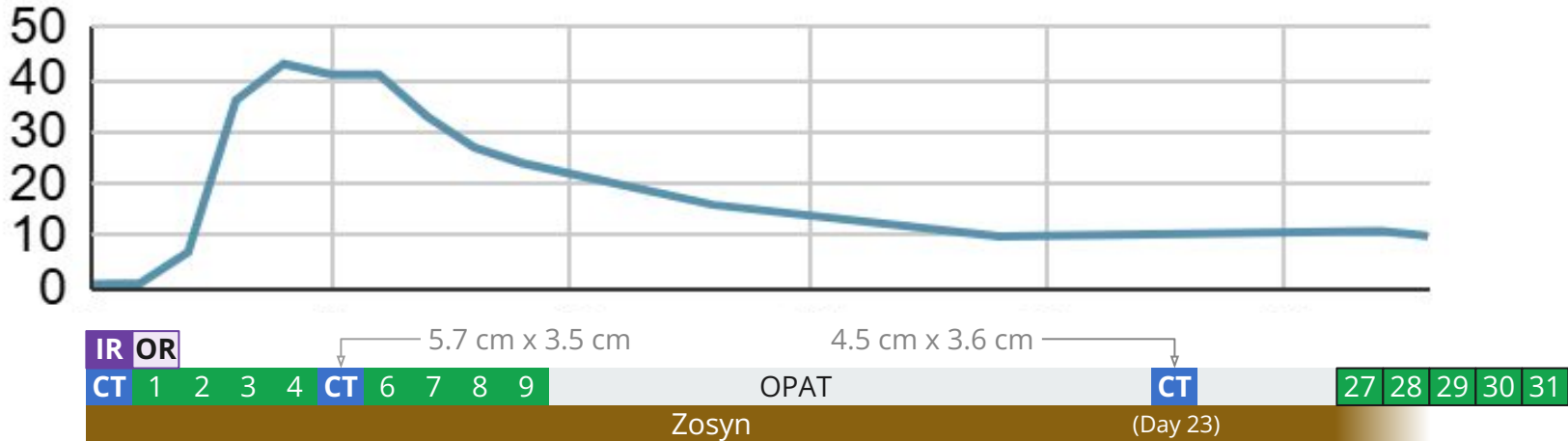
Case 2: Readmission

- Represents for “pinkish drainage” from ostomy



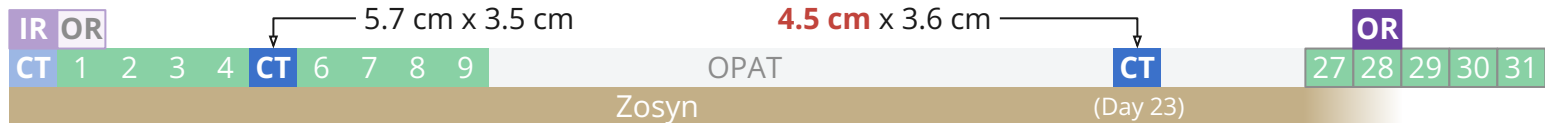
Case 2: Readmission

- Represents for “pinkish drainage” from ostomy
 - No infectious concerns from patient



Case 2: Readmission

- Represents for “pinkish drainage” from ostomy
 - No infectious concerns from patient
- Surg onc reviews recent imaging → **not happy** with the **ongoing collection** still being there
- They decide to do **laparoscopic drainage of pre-sacral abscess**
 - Did not reach out to ID beforehand (i.e. it was **their own initiative**)
 - They **sent cultures**
 - Gold star for **Dr Murken!**

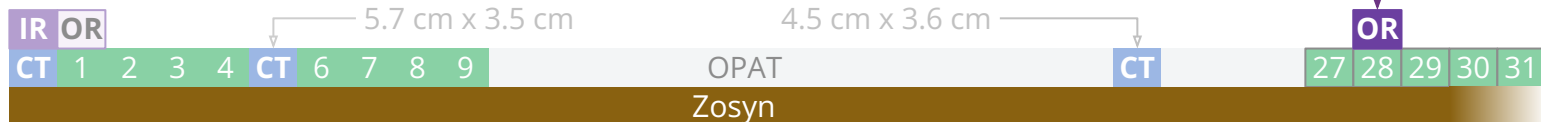


Case 2: Second cultures

Only grew **E coli** & anaerobes

- E coli not susceptible to **Zosyn**

	2+ E coli
Ampicillin	Resist
Amox/clav	Inter
Pip/tazo	Resist
Cefazolin	Resist
Ceftriaxone	S
Ceftaz	S
Cefepime	S
Carbapenems	S
Quinolones	Resist
Aminogly	S
Tetracycline	S
TMP/SMX	Resist

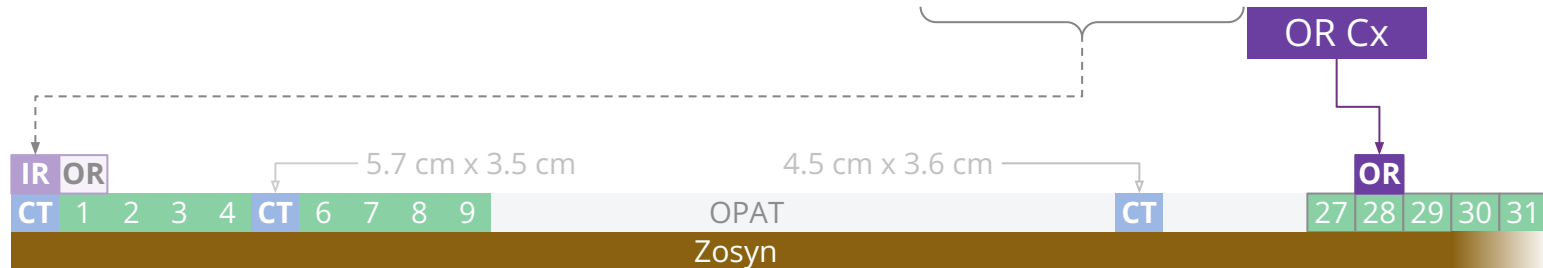

Case 2: Second cultures

Only grew *E coli* & anaerobes

- *E coli* not susceptible to **Zosyn**
- Otherwise, quite similar pattern to before

	3+ <i>E coli</i>	3+ <i>E coli</i>	2+ <i>E coli</i>
Ampicillin	Resist	S	Resist
Amox/clav	S	S	Inter
Pip/tazo	S	S	Resist
Cefazolin	Resist	---	Resist
Ceftriaxone	S	S	S
Ceftaz	S	S	S
Cefepime	S	S	S
Carbapenems	S	S	S
Quinolones	Resist	S	Resist
Aminogly	S	S	S
Tetracycline	S	S	S
TMP/SMX	Resist	S	Resist



[Q2.3] What antibiotic(s) do you want now?

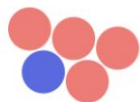Multiple choice



Select one: (stratified by old answers)

- Nothing more, she's done
- Ceftriaxone + Flagyl
- Zosyn
- Cefepime + Flagyl
- Carbapenem

[Q2.3] What to do with this E coli?



Segment

[Q2.2][A] What to treat with?

- Unasyn
- Ceftriaxone + Flagyl
- Zosyn
- Cefepime + Flagyl
- Carbapenem

0 Nothing more needed

5 Ceftriaxone + Flagyl

0 Zosyn

0 Cefepime + Flagyl

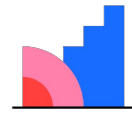
0 Carbapenem

OR Cx	E coli
Ampicillin	Resist
Amox/clav	Inter
Pip/tazo	Resist
Cefazolin	Resist
Ceftriaxone	S
Ceftaz	S
Cefepime	S
Carbapenems	S
Quinolones	Resist
Aminogly	S
Tetracycline	S
TMP/SMX	Resist

Today is **day 28** of Zosyn

[Q2.4] Duration?

Multiple choice

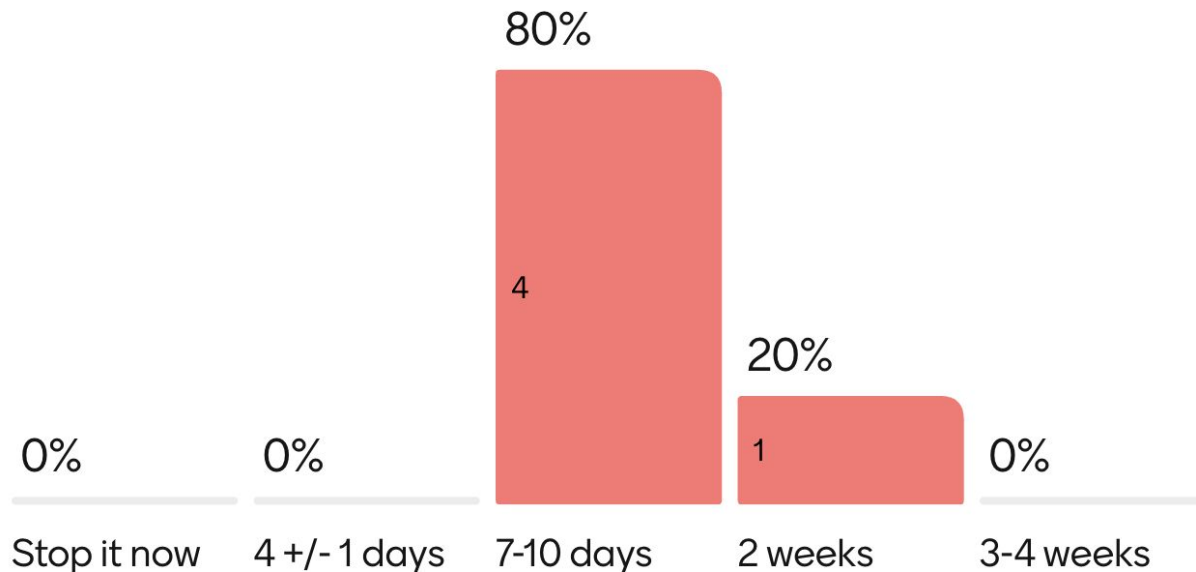


Mentimeter

- Stop it now
- 4 +/- 1 days
- 7-10 days
- 2 weeks
- 3-4 weeks

For agents like Unasyn & ceftriaxone, assume PO transition is an option

[Q2.4] Anticipated duration?



Segment

[Q2.3] What to do with this E coli?

- Nothing more needed
- Ceftriaxone + Flagyl
- Zosyn
- Cefepime + Flagyl
- Carbapenem

Case 2: Second hospital course

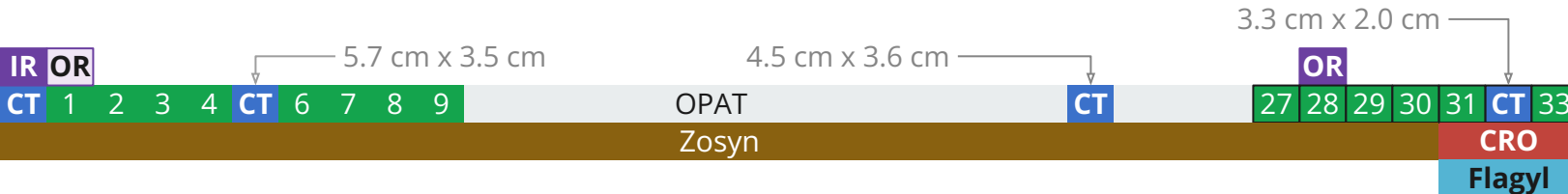
Switched to **ceftriaxone** & **flagyl**

- Planned for 10 day course

Had **repeat CT** (post op day 4) for interval evaluation

CT A/P (Day 32)

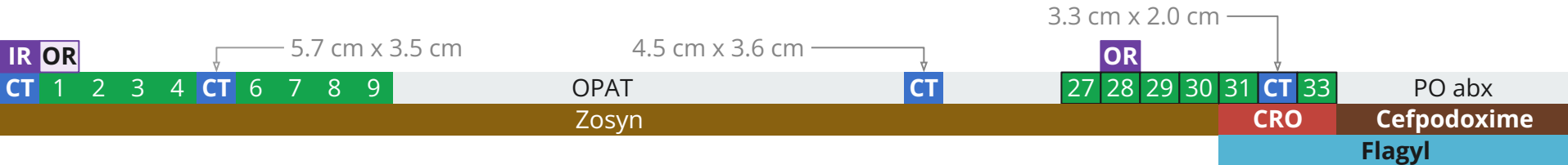
Interval changes lap drainage with drain tip now terminating within this presacral collection. **Abscess has decreased in size**, now **measuring 3.3 cm**



Case 2: Second hospital course

Switched to **ceftriaxone** & **flagyl**

- Completed 10 day course
- Changed to **cefpodoxime** & **flagyl**



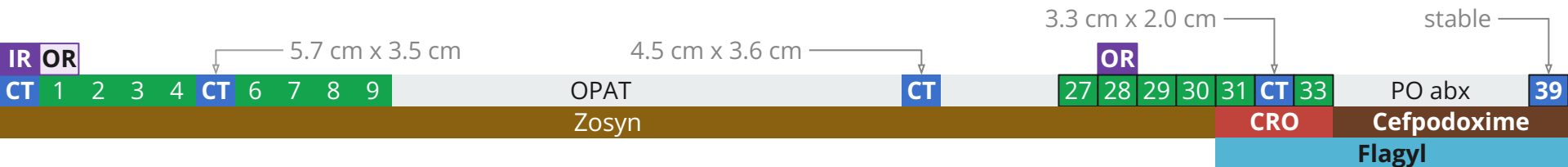
Case 2: Resolution

Switched to **ceftriaxone & flagyl**

- Completed 10 day course
- Changed to **cefpodoxime & flagyl**

Had **repeat CT** (POD #11) i.e. at end of antibiotics

- Stable, but ongoing collections
- Did okay off of antibiotics



Case #3

(also cancer)



Case 3: HPI

A **43 y/o F** with PMH including **metastatic cervical cancer** p/w **possible intra-abdominal infection**

- Metastatic cervical cancer on palliative chemo & XRT
 - **Extensive radiation history** (so surgery will be off the table)
- Tumor burden & bulky lymphadenopathy has caused obstructive uropathy
 - s/p neph tubes & stents
- **Progression of disease** on PET/CT from a month ago

Case 3: Backstory

A **43 y/o F** with PMH including **metastatic cervical cancer** (palliative chemo & XRT) c/b obstructive uropathy p/w **possible intra-abdominal infection**

In the past 6 weeks, **multiple admissions** for **blood loss anemia** 2/2 **vaginal bleeding**

Case 3: Backstory

A **43 y/o F** with PMH including **metastatic cervical cancer** (palliative chemo & XRT) c/b obstructive uropathy p/w **possible intra-abdominal infection**

In the past 6 weeks, **multiple admissions** for **blood loss anemia** 2/2 **vaginal bleeding**

- Most recent admission (**1 month ago**), massive transfusion protocol in MICU
- CTA A/P (-31 days): Venous hemorrhage into uterus

CTA A/P (31 days ago)
Heterogeneous density is within the endometrial cavity, which may represent clotted blood/hematoma

Case 3: Backstory

A **43 y/o F** with PMH including **metastatic cervical cancer** (palliative chemo & XRT) c/b obstructive uropathy p/w **possible intra-abdominal infection**

In the past 6 weeks, **multiple admissions** for **blood loss anemia** 2/2 **vaginal bleeding**

- Most recent admission (**1 month ago**), massive transfusion protocol in MICU
- CTA A/P (-31 days): Venous hemorrhage into uterus

Got IR **embolization of bilateral uterine arteries** 30 days ago

CTA A/P (31 days ago)
Heterogeneous density is within the endometrial cavity, which may represent clotted blood/hematoma

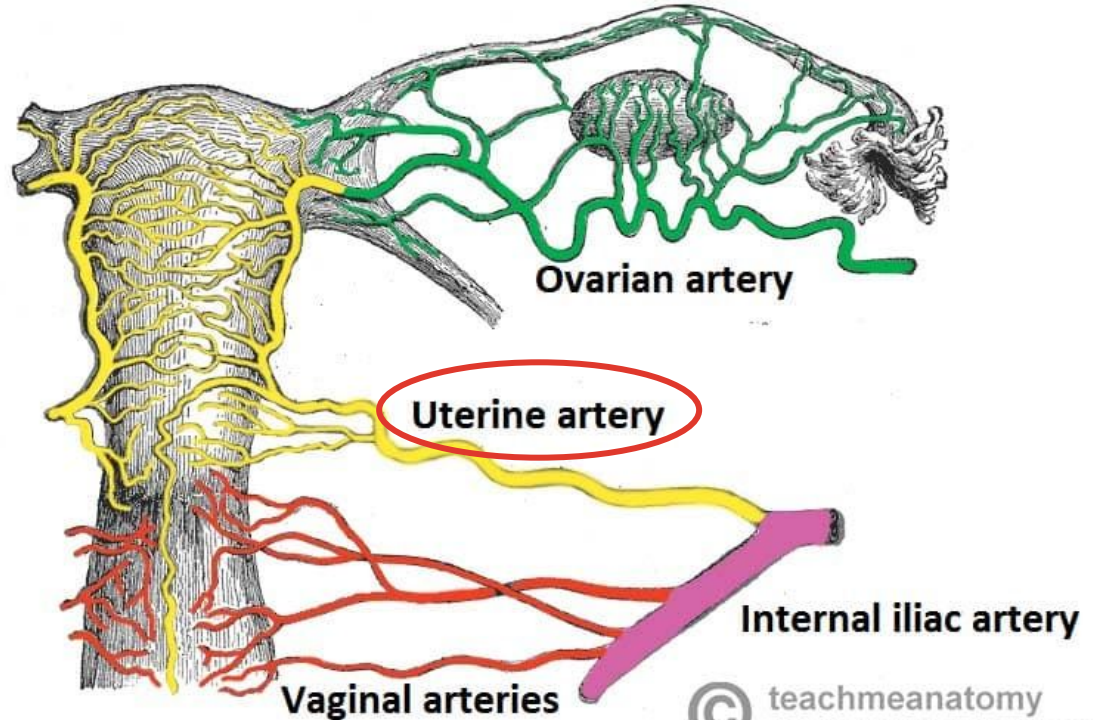
Case 3: Backstory

A 43 y/o F with PMH including **me**
obstructive uropathy p/w **possibl**

In the past 6 weeks, **multiple adn**

- Most recent admission (1 m
- CTA A/P (-31 days): Venous l

Got IR **embolization of bilateral**



Case 3: HPI

A 43 y/o F with PMH including **metastatic cervical cancer** (palliative chemo & XRT) with recent **bilateral uterine artery embolization** c/b obstructive uropathy p/w **possible intra-abdominal infection**

Presents for **constipation and nausea**

- WBC 25
- CRP 251

Case 3: HPI

A 43 y/o F with PMH including **metastatic cervical cancer** (palliative chemo & XRT), **bilateral uterine artery embolization** c/b obstructive uropathy p/w **possible intestinal infection**

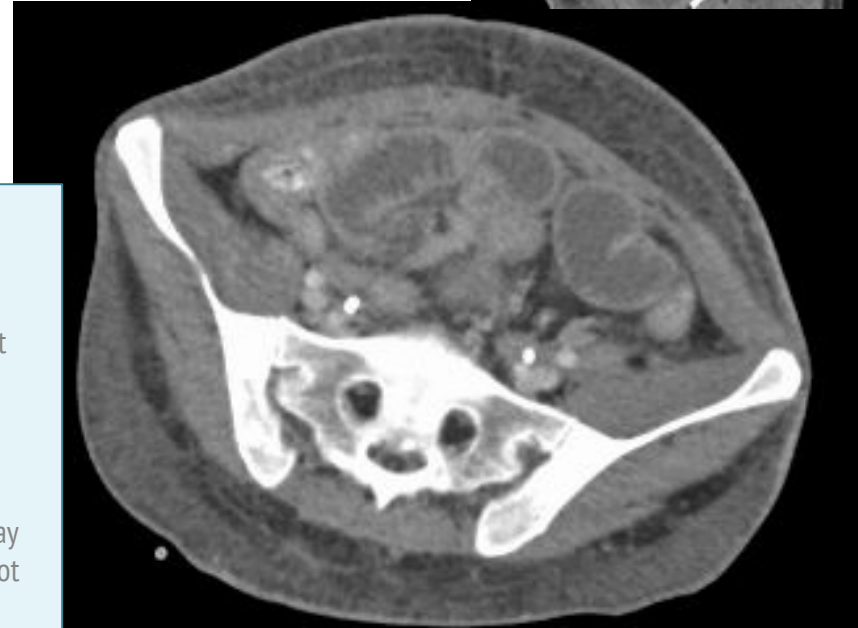
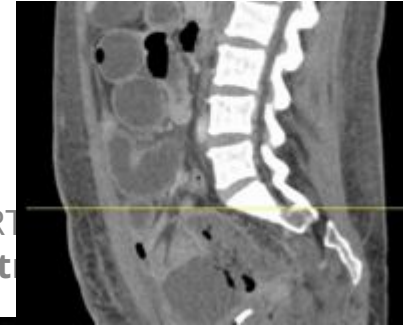Presents for **constipation and nausea**

- WBC 25
- CRP 251

CT A/P (Admission)

Peripherally enhancing air-containing fluid collection within pelvis, may reflect intraluminal bowel contents, abscess, or additional fluid collection, **uncertain etiology** on this study. Repeat examination after enteric contrast may be of benefit

There are abnormally distended small bowel loops noted throughout the abdomen, possibly related to developing obstruction. There are decompressed small bowel loops noted within the pelvis which may be due to transient narrowing or underlying stricture, metastatic disease is not excluded



Case 3: HPI

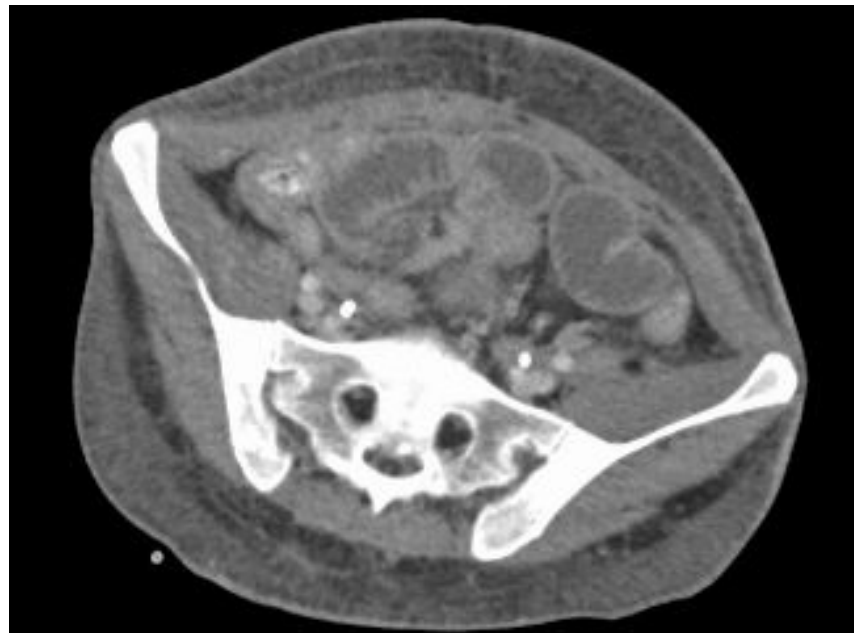
A 43 y/o F with PMH including **metastatic cervical cancer** (palliative chemo & XRT) with recent **bilateral uterine artery embolization** c/b obstructive uropathy p/w **possible intra-abdominal infection**

Colorectal surgery attestation

CT reviewed - **expect pelvic abscess is necrotic tumor or uterus s/p embolization**. Small bowel likely tethered to this area, though difficult to discern. Vitals normal, not peritonitic. No particular concern for bowel perforation at this point

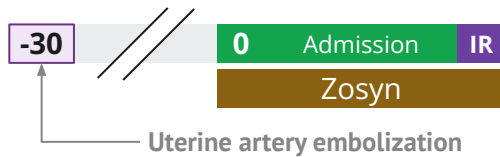
CT A/P (Admission)

Peripherally enhancing air-containing fluid collection within pelvis, may reflect intraluminal bowel contents, abscess, or additional fluid collection, **uncertain etiology** on this study. Repeat examination after enteric contrast may be of benefit



Case 3: Hospital course

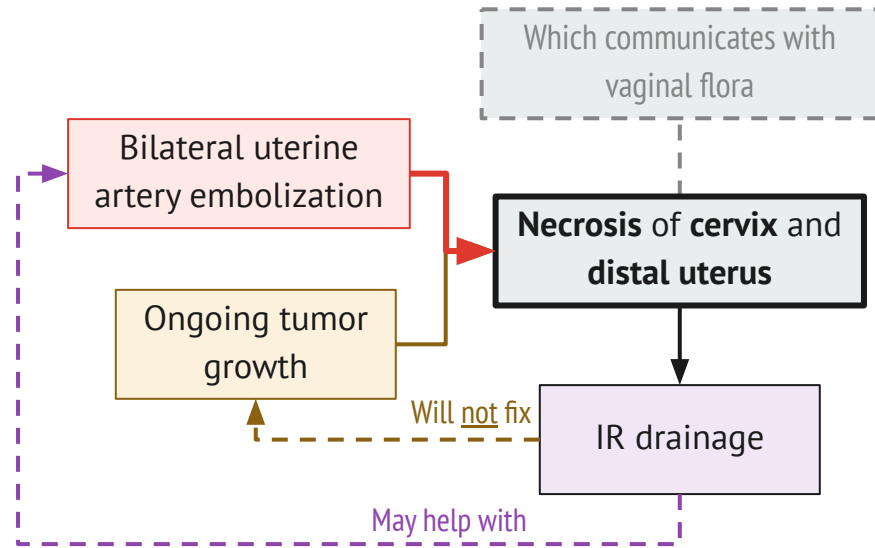
- Treated with **Zosyn**
- **IR puts a drain** in on day 5



Can we even *obtain* source control?

How should I conceptualize this?

- Like a fistula to the outside environment?
- Ischemic mesenteric tissue?
- Walled off necrosis?
- Regular, necrotic tumor?

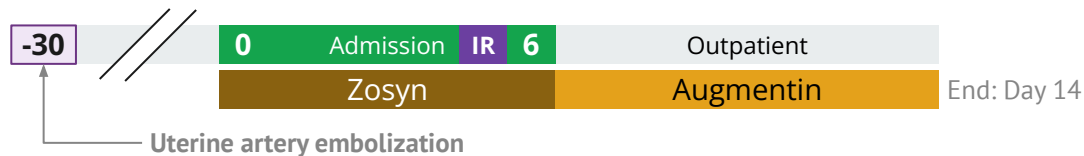


Case 3: Discharge

- Treated with **Zosyn**
- **IR puts a drain** in on day 5
- Completes **14 days** of treatment with Augmentin


Sign off recommendations

- **Two weeks** of antibiotics
- Augmentin is reasonable PO option for discharge



Case 3: Clinic follow up

Seen in gyn-onc clinic on day 20

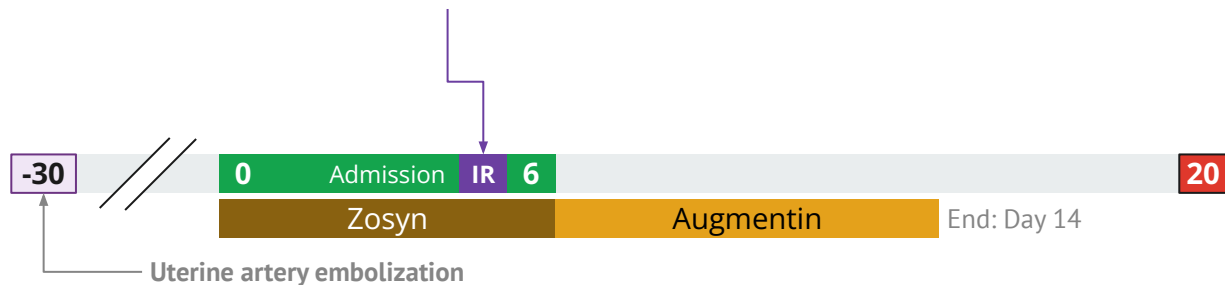


Case 3: Clinic follow up

Seen in gyn-onc clinic on day 20

- They review **cultures from IR drain**

	4+ E faecium
Ampicillin	Resist
Daptomycin	SDD
Linezolid	S
Vancomycin	S



Case 3: Clinic follow up


Seen in gyn-onc clinic on day 20

- They review **cultures from IR drain**
- Obtain same **day CT scan**

	4+ E faecium
Ampicillin	Resist
Daptomycin	SDD
Linezolid	S
Vancomycin	S

CT A/P (Day 20)

Persistent but decreased size of the complex collection in the pelvis. The residual collection **measures 6.8 x 3.7 cm** (prior measurement was **9.1 x 5.6 cm**) with the indwelling pigtail **percutaneous drain remaining in place within the collection**



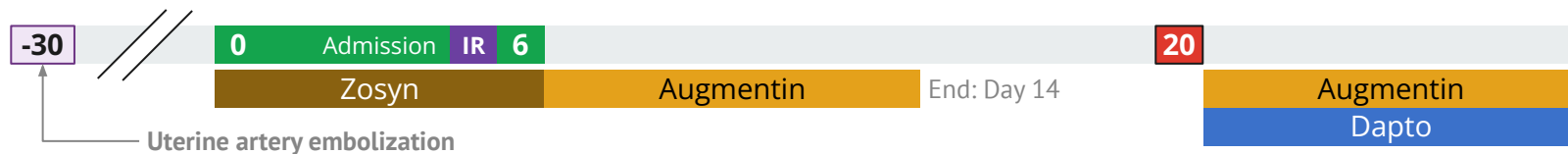
Case 3: Clinic follow up

Seen in gyn-onc clinic on day 20

- They review **cultures from IR drain**
- Obtain same **day CT scan**

They discuss with ID → **14 days of dapto** + **Augmentin**

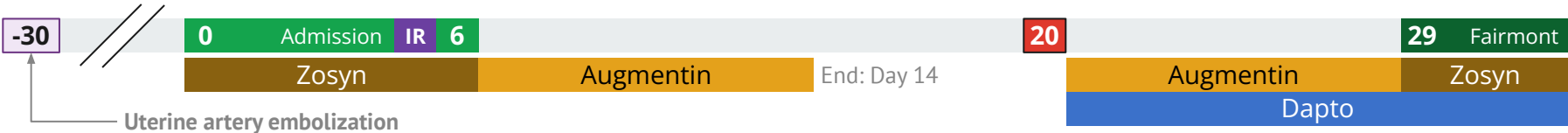
- Has a port so was started on OPAT promptly



Case 3: Readmission

Admitted to **Fairmont** for **pain refractory** to PO meds + fentanyl patch

- No new infectious concerns

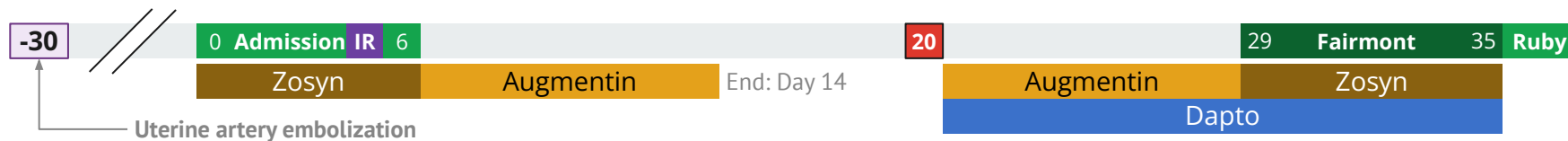


Case 3: Readmission

Admitted to **Fairmont** for **pain refractory** to PO meds + fentanyl patch

- No new infectious concerns

Transferred to Ruby on day 26 → **afternoon ID consult**



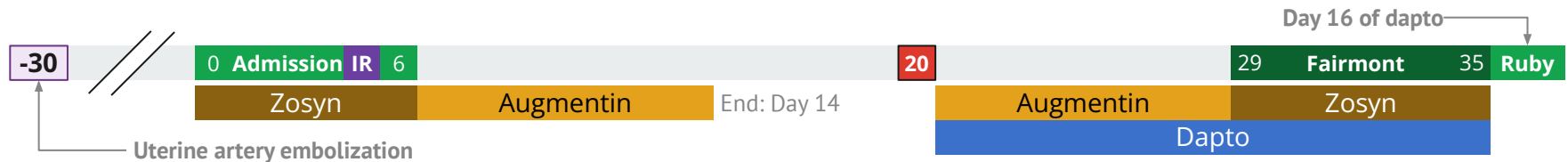
Case 3: Readmission

Admitted to **Fairmont** for **pain refractory** to PO meds + fentanyl patch

- No new infectious concerns


Transferred to Ruby on day 26 → **afternoon ID consult**

- Today is **day 16** of this **round of antibiotics** (Dapto + Augmentin/Zosyn)
- Is in **too much pain for a CT**
- **Labs** since leaving the first admission (day 6)
 - **WBC** has remained **normal** (peak was 11 on day 0)
 - **Stable CRP elevation (30-50s)**, from peak of 250s on day 0
- Still having drain output



What do we do now???

In addition to goals of care



Case 3: Readmission

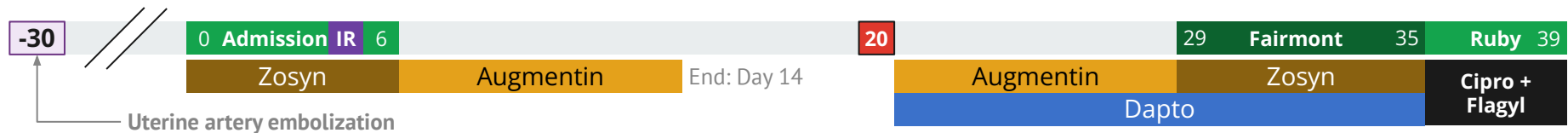
Admitted to **Fairmont** for **pain refractory** to PO meds + fentanyl patch

- No new infectious concerns
- Transferred to Ruby on day 26

She looks like *she is ready to pass*, but still remains *treatment oriented*

- We say that **cipro and flagyl** are reasonable, though **mainly prophylaxing** at this point
- Duration TBD, **2 weeks** (?) or until sees us in clinic

Further goals of care → **CMO**



Discussion



Links to articles discussed
here



Complicated intra-abdominal infections



STOP-IT



Design: Multicenter, randomized, non-blinded controlled trial

Population: 518 adults with **complicated intra-abdominal infections** who had **adequate source control**

Intervention:

- **Short course**: Fixed 4 ± 1 days of antibiotics after source control
- **Control**: Antibiotics until 2 days after resolution of fever, leukocytosis, and ileus (usual duration ~8 days), maximum duration of 10 days

Primary Outcome: Composite of surgical site infection, recurrent intra-abdominal infection, or death within 30 days

- Design: Superiority study

STOP-IT



Design: Multicenter, randomized, non-blinded controlled trial

Population: 518 adults with **complicated intra-abdominal infections** who had **adequate source control**

Intervention:

- **Short course**: Fixed 4 ± 1 days of antibiotics after source control
- **Control**: Antibiotics until 2 days after resolution of fever, leukocytosis, and ileus (usual duration ~8 days), maximum duration of 10 days

Primary Outcome: Composite of surgical site infection, recurrent intra-abdominal infection, or death within 30 days

- Design: **Superiority study**

STOP-IT vs PARACHUTE

Refresher on my journal club from March

- Randomized, blinded; assessed **mortality** when jumping from aircraft with a **parachute** vs **empty backpack**



Parachute use to prevent death and major trauma when jumping from aircraft: randomized controlled trial (BMJ, 2018)

STOP-IT vs PARACHUTE

Refresher on my journal club from March

- Randomized, blinded; assessed **mortality** when jumping from aircraft with a **parachute vs empty backpack**
- **No difference in outcomes** between two groups at 30 days
 - However, only **able to enroll** subjects who jumped from **stationary planes** (i.e. low risk group)





Endpoint	Parachute	Control	P value
On impact			
Death or major traumatic injury	0 (0)	0 (0)	>0.9
Mean (SD) Injury Severity Score	0 (0)	0 (0)	>0.9
30 days after impact			
Death or major traumatic injury	0 (0)	0 (0)	>0.9
Mean (SD) Injury Severity Score	0 (0)	0 (0)	>0.9



Parachute use to prevent death and major trauma when jumping from aircraft: randomized controlled trial (BMJ, 2018)

STOP-IT vs PARACHUTE

“According to the original sample-size calculation...we calculated that **a sample of 505 patients per group** would be required to [achieve enough power] to **detect a 10% difference** in complication rates”

Control (~8 days)	Short Duration (4 ± 1 days)
 260 randomized	 257 randomized
 71 violated protocol (27%)	 46 violated protocol (18%)









Parachute use to prevent death and major trauma when jumping from aircraft: randomized controlled trial (BMJ, 2018)

STOP-IT vs PARACHUTE

“According to the original sample-size calculation...we calculated that **a sample of 505 patients per group** would be required to [achieve enough power] to **detect a 10% difference** in complication rates”

“After the first **interim analysis showed** nearly **identical outcomes** in the two cohorts, a...request for continued [funding] to reach the targeted enrollment levels **was [denied due]** to a concern for **futility.**”

Control (~8 days)	Short Duration (4 ± 1 days)
 260 randomized	 257 randomized
 71 violated protocol (27%)	 46 violated protocol (18%)
 58 had outcome (22.3%)	 56 had outcome (21.8%)







Absolute difference **-0.5%**; 95% CI, -7.0 to 8.0; **P = 0.92**



Parachute use to prevent death and major trauma when jumping from aircraft: randomized controlled trial (BMJ, 2018)

STOP-IT vs PARACHUTE

When we apply STOP-IT, **are we jumping out of a plane without a parachute?**

Control (~8 days)	Short Duration (4 ± 1 days)
 260 randomized	 257 randomized
 71 violated protocol (27%)	 46 violated protocol (18%)
 58 had outcome (22.3%)	 56 had outcome (21.8%)

Absolute difference **-0.5%**; 95% CI, -7.0 to 8.0; **P = 0.92**









Parachute use to prevent death and major trauma when jumping from aircraft: randomized controlled trial (BMJ, 2018)

STOP-IT vs PARACHUTE

When we apply STOP-IT, are we jumping out of a plane without a parachute?

- Statistically speaking, perhaps
- **No significant difference \neq not worse than**
- That said, the STOP-IT is not the *only evidence* we have supporting a shorter duration

Control (~8 days)	Short Duration (4 ± 1 days)
 260 randomized	 257 randomized
 71 violated protocol (27%)	 46 violated protocol (18%)
 58 had outcome (22.3%)	 56 had outcome (21.8%)

Absolute difference **-0.5%**; 95% CI, -7.0 to 8.0; **P = 0.92**



Parachute use to prevent death and major trauma when jumping from aircraft: randomized controlled trial (BMJ, 2018)

DURAPOP trial

Intensive Care Medicine (2018)



Short-course antibiotic therapy for critically ill patients treated for postoperative intra-abdominal infection: the DURAPOP randomised clinical trial

DURAPOP trial



Purpose: Investigate duration for **post-op cIAI** in **critically ill patients**

Patient population: Adults admitted to the ICU for post-op infections

- Must **have “source control”** assessed at time of enrollment
- **No immunocompromise** (HIV, cancer, chemo)

Outcomes: Antibiotic free days (primary)

- Recurrent infection
- Need for more surgery / source control
- 45 day mortality
- Emergence of MDRs

DURAPOP trial

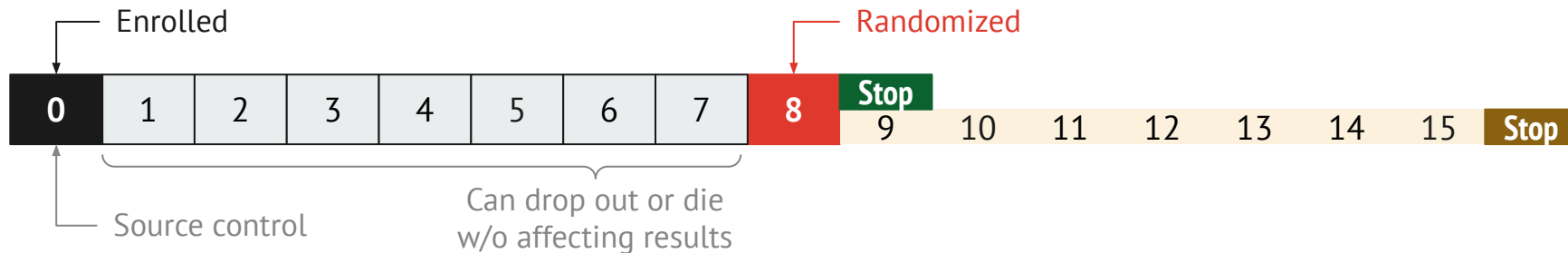
Purpose: Investigate duration for **post-op cIAI** in **critically ill patients**

Patient population: Adults admitted to the ICU for post-op infections

- Must **have “source control”** assessed at time of enrollment
- **No immunocompromise** (HIV, cancer, chemo)

Methods: Randomized, un-blinded

- Enrolled at day zero (source control) but not **randomized** until day 8
 - Avoids over-emphasis on patients where duration of antibiotics would make no difference
- **Short duration**: Stop at day 8
- **Long duration**: Continue 7 more days



DURAPOP trial

- Similar rates of adherence to STOP-IT

Control (15 days) n=116



95 followed protocol (82%)



11 over 15 days (9.5%)



10 under 15 days (8.6%)

Shorter (stop at 8) n=120



92 followed protocol (79%)



21 prolonged abx (17.5%)



4 under 8 days (3.3%)

DURAPOP trial



Similar rates of

Hospital length of stay

30.0 vs 30.5 (OR 0.80) $p=0.42$

Clinical failure after day 8

14% vs 24% (OR 1.18) $p=0.52$

Mortality

15% vs 11% (OR 0.71) $p=0.43$

New antibiotic therapy

39% vs 42% (OR 1.17) $p=0.59$

Control (15 days)

Shorter (stop at 8)

DURAPOP trial

Similar rates of

Hospital length of stay

30.0 vs 30.5 (OR 0.80) p=0.42

Clinical failure after day 8

14% vs 24% (OR 1.18) p=0.52

Mortality

15% vs 11% (OR 0.71) p=0.43

New antibiotic therapy

39% vs 42% (OR 1.17) p=0.59

Control (15 days)

Shorter (stop at 8)

Higher rates of...

Additional source control

28% vs 40% (OR 1.61) p=0.10

Mainly via **percutaneous drains**

9% vs 19% (OR 2.26) **p=0.04**

Bacteremia

4% vs 11% (OR 2.69) **p=0.06**

DURAPOP trial

Similar rates of

Hospital length of stay

30.0 vs 30.5 (OR 0.80) p=0.42

Clinical failure after day 8

14% vs 24% (OR 1.18) p=0.52

Mortality

15% vs 11% (OR 0.71) p=0.43

New antibiotic therapy

39% vs 42% (OR 1.17) p=0.59

Control (15 days)

Higher rates of...

Recurrent infection (**very high**)

93% vs 74% (OR 0.22) p=0.21

Emergence of MRDO bacteria

50% vs 43% (OR 0.74) p=0.28

Shorter (stop at 8)

Higher rates of...

Additional source control

28% vs 40% (OR 1.61) p=0.10

Mainly via **percutaneous drains**

9% vs 19% (OR 2.26) **p=0.04**

Bacteremia

4% vs 11% (OR 2.69) **p=0.06**

CABI trial

Journal of Gastrointestinal Surgery (2021)



The CABI Trial: an Unblinded Parallel Group Randomised Controlled Feasibility Trial of Long-Course Antibiotic Therapy (28 Days) Compared with Short Course (≤ 10 Days) in the Prevention of Relapse in Adults Treated for Complicated Intra-Abdominal Infection

CABI trial



Purpose: Pilot trial comparing ≤ 10 days to 28 days antibiotics for cIAI. Hypothesized that longer is better

Primary outcomes: willingness of participants to be randomised and feasibility of trial procedures

- To be counted as a relapse, had to have been off of antibiotics
- Assessed at 30 & 90 days


Patient population: Not as clearly defined


- **Included patients** who **did not get source control**
- Had to have fever + neutrophilia + clinical judgement to be cIAI
- 172 screened \rightarrow 84 eligible (49%) \rightarrow 31 enrolled (37%)


Methods: 1:1 randomization, not blinded

CABI trial


Long Duration (28 days)


 13 patients included


 four stopped early

 28 days duration

Short Duration (≤ 10 days)

 17 patients included

 one lost to follow up

 9 days duration


CABI trial


Only group that had **relapse** was the **short duration** group


Only **adverse events** were in the **long duration** group


- Side effect was LFTs (day 20 of Augmentin)
- One death was when antibiotics were stopped at day 4


Long Duration (28 days)


 13 patients included


 four stopped early

 28 days duration


 zero relapse


 1 side effect (7.7%)


 1 death (7.7%)


 zero C diff


Short Duration (≤ 10 days)


 17 patients included


 one lost to follow up

 9 days duration

 4 relapses (24%)

 no side effects

 no deaths

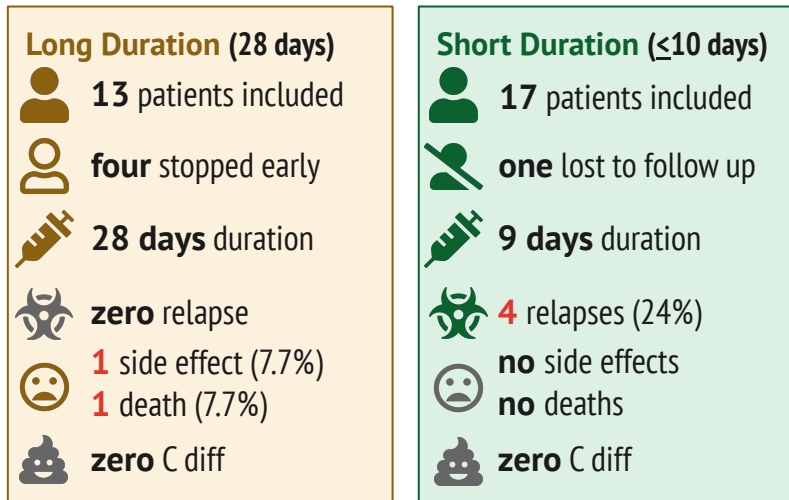
 zero C diff

CABI trial

Key strengths (and weaknesses) revolve around **source control**

Unique study in that they **included** those who **did not have source control**

- **Short Duration:** 6 had no source control (**35%**)
- **Long Duration:** 2 had no source control (**15%**)



30% of patients in England **do not** get source control

CABI trial

Key strengths (and weaknesses) revolve around **source control**








Unique study in that they **included** those who **did not have source control**

- **Short Duration:** 6 had no source control (**35%**)
- **Long Duration:** 2 had no source control (**15%**)


There were other imbalances in the **short duration** group

- **59%** were **post-op infections** (vs **31%**)
- **24%** had **anastomotic leak** (vs **8%**)
- **82%** had **fluid collections** (vs **62%**)

Long Duration (28 days)

-  **13** patients included
-  **four** stopped early
-  **28 days** duration
-  **zero** relapse
-  **1** side effect (7.7%)
-  **1** death (7.7%)
-  **zero** C diff

Short Duration (≤ 10 days)

-  **17** patients included
-  **one** lost to follow up
-  **9 days** duration
-  **4** relapses (24%)
-  **no** side effects
-  **no** deaths
-  **zero** C diff

30% of patients in England **do not** get source control

Learning points & take aways



Learning points & take aways

- Complicated intra-abdominal infections are complicated!
- Trial data is lacking, and where it does exist, interpretation can be challenging
- **STOP-IT**
 - Only had patients with source control
 - $P > 0.05 \neq$ not worse than
- **DURAPOP**
 - ICU patients with source control
 - $P > 0.05 \neq$ not worse than
- **CABI**
 - Included w/o source control
 - But arms of study imbalanced



Slides available on hunteratliff1.com/talk/; Citations available via QR code or via the “citations” button on the website