




The heart of the matter

CLINID conference
Hunter Ratliff
01/29/2025

*Ages, dates, and other identifying information may have been changed
I have no conflict of interest in relation to this presentation*



Shortcuts



Case 1: [Start](#) | [Summary slide](#)

Case 2: [Start](#) | [Summary slide](#)

Discussion: [Objectives](#)

[Takeaway slide](#)

- **TAVR vs SAVR** IE | clinical manifestations | microbio/epi | echos aren't great
- **Cardiac PET** | Can we do it | pt prep | what radiology looks for
- **PET Indications** | endocarditis | CIED | LVAD
- **Serial PET/CT** | VASGRA cases | outcomes
- Bonus content: PET vs SPECT

Case #1

Case 1: HPI

A **74 y/o F** with PMH including DM (A1c 7) c/b **R DFU**, CAD s/p CABG, Hx mechanical MVR (2015 & 2021) on warfarin, s/p TAVR (9 mo ago), CKD3 p/w **worsening R foot wound**

Case 1: HPI

A **74 y/o F** with PMH including DM (A1c 7) c/b **R DFU**, CAD s/p CABG, Hx mechanical MVR (2015 & 2021) on warfarin, s/p TAVR (9 mo ago), CKD3 p/w **worsening R foot wound**

- **Past few days, foot has been** red, warm, and swollen
- **Two days ago** might have had episode of **chills**, but none since

Case 1: HPI

A **74 y/o F** with PMH including DM (A1c 7) c/b **R DFU**, CAD s/p CABG, Hx mechanical MVR (2015 & 2021) on warfarin, s/p TAVR (9 mo ago), CKD3 p/w **worsening R foot wound**

- **Past few days, foot has been** red, warm, and swollen
- **Two days ago** might have had episode of **chills**, but none since
- **Mild cough** for **past 3 days**
- **Chronic diarrhea** for some time

Case 1: Social history, exposures, & risk factors



Geographic & Travel	<ul style="list-style-type: none">• Lives alone in PA• No travel
Substance & needles	<ul style="list-style-type: none">• No EtOH, tobacco, or drugs• On insulin
Animals	<ul style="list-style-type: none">• Two dogs at home, no bites or scratches; dogs are cuddly and sleep with her• No other animals
Exposures	<ul style="list-style-type: none">• Doesn't go outside much; wound hasn't gotten dirty or soiled

Case 1: Physical exam

BP	108/48	Pulse	53	SpO2	96 %
Temp	36.6 °C (97.9 °F)	RR	18	BMI	27 kg/m ²
General	Alert and oriented, NAD				
Resp	Normal respiratory effort, symmetric chest rise				
CV	systolic murmur heard throughout pericardium; extremities perfused				
GI	Non-distended; no TTP				
Extremities	erythematous RLE up to mid shin, plantar foot ulcer				
Neuro/MSK	Moves extremities				

Case 1: Labs

CBC	Result
WBC	17.7
Hgb	10.8
Platelets	261
Neut %	85%
Lymph %	4%
Eos %	0%
CRP	255

Chem7	Result
Na	134
K	4.6
HCO3	23
BUN	46
Cr	1.2

Case 1: Labs

CBC	Result
WBC	17.7
Hgb	10.8
Platelets	261
Neut %	85%
Lymph %	4%
Eos %	0%
CRP	255

Chem7	Result
Na	134
K	4.6
HCO3	23
BUN	46
Cr	1.2

LFTs	Result
AST	32
ALT	18
Alk Phos	81
Bili	0.5
Albumin	2.2

Coags	Result
INR	1.55

INR goal 2.5 - 3.5

Case 1: Micro




Date	Culture	Result
Today	Blood	

Case 1: Micro

Date	Culture	Result
Today	Blood	STREPTOCOCCUS DYSGALACTIAE

Case 1: Micro

Date	Culture	Result
Today	Blood	STREPTOCOCCUS DYS GALACTIAE
-7 wk	Blood	STREPTOCOCCUS DYS GALACTIAE
-10.56 wk	Blood	No growth
-11 wk	Blood	STREPTOCOCCUS DYS GALACTIAE



Went to Mon

Case 1: Backstory

Admit	Date	BCx results
#3 (Ruby)	Today	STREPTOCOCCUS DYSGALACTIAE
#2 (Mon)	-7 wk	STREPTOCOCCUS DYSGALACTIAE
#1 (Ruby)	-10.56 wk	No growth
	-11 wk	STREPTOCOCCUS DYSGALACTIAE

Admitted with MICU with n/v and rigors

- Admission BCx were positive
- Never any pressors

Case 1: Backstory

Admit	Date	BCx results
#3 (Ruby)	Today	STREPTOCOCCUS DYS GALACTIAE
#2 (Mon)	-7 wk	STREPTOCOCCUS DYS GALACTIAE
#1 (Ruby)	-10.56 wk	No growth
	-11 wk	STREPTOCOCCUS DYS GALACTIAE

Admitted with MICU with n/v and rigors

- Admission BCx were positive
- Never any pressors

Podiatry: “Right foot ulcer appears stable with no acute signs of infection. **Recommend look for other source of current bacteremia...no surgery planned**”

Case 1: Backstory

Medicine notes

Admit	Date	BCx results
#3 (Ruby)	Today	STREPTOCOCCUS DYSGALACTIAE
#2 (Mon)	-7 wk	STREPTOCOCCUS DYSGALACTIAE
#1 (Ruby)	-10.56 wk	No growth
	-11 wk	STREPTOCOCCUS DYSGALACTIAE

- # Right lower extremity cellulitis
- # Streptococcus dysgalactiae bacteremia
 - podiatry evaluated the patient recommended no surgery
 - repeat blood cultures negative
 - deescalate antibiotics to Rocephin based on sensitivities
 - Possible ID consult based on MRI results

Case 1: Backstory

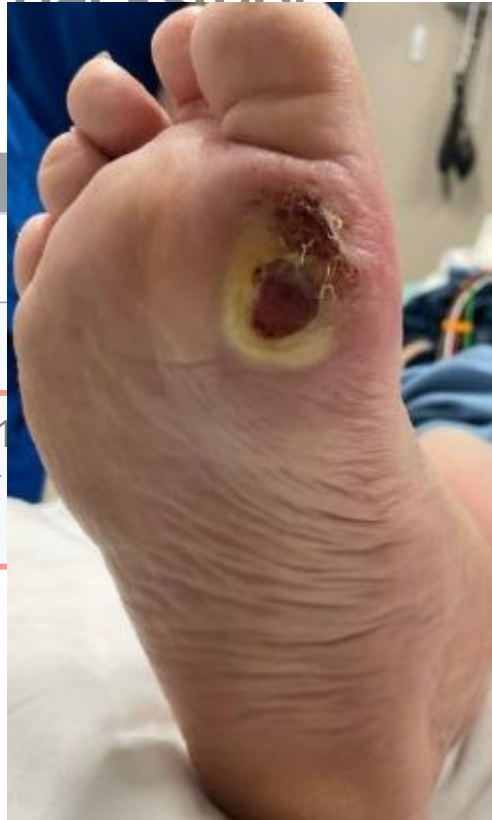Medicine notes

Admit	Date	BCx results
#3 (Ruby)	Today	STREPTOCOCCUS DYSGALACTIAE
#2 (Mon)	-7 wk	STREPTOCOCCUS DYSGALACTIAE
#1 (Ruby)	-10.56 wk	No growth
	-11 wk	STREPTOCOCCUS DYSGALACTIAE

- # Right lower extremity cellulitis
- # Streptococcus dysgalactiae bacteremia
 - podiatry evaluated the patient recommended no surgery
 - repeat blood cultures negative
 - deescalate antibiotics to Rocephin based on sensitivities
 - **MRI right foot** completed and demonstrates **no evidence of osteomyelitis**

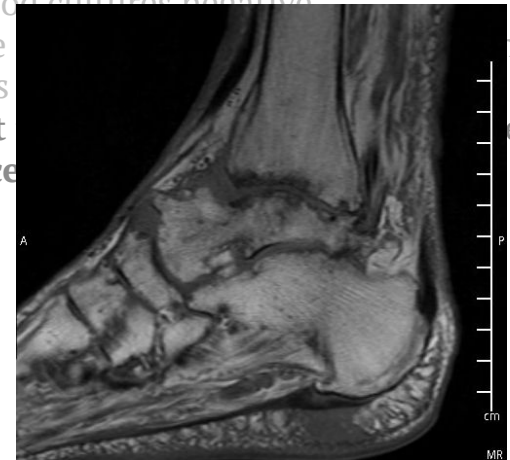
Case 1: Backstory

Admit	
#3 (Ruby)	S CUS AE
#2 (Mon)	CUS AE
#1 (Ruby)	-1 CUS AE



Medicine notes

- # Right lower extremity cellulitis
- # Streptococcus dysgalactiae bacteremia
 - podiatry evaluated the patient recommended no surgery
 - repeat blood cultures negative
 - deescalate
 - sensitivities
 - MRI right
 - no evidence



Case 1: Backstory

Medicine notes

Admit	Date	BCx results
#3 (Ruby)	Today	STREPTOCOCCUS DYSGALACTIAE
#2 (Mon)	-7 wk	STREPTOCOCCUS DYSGALACTIAE
#1 (Ruby)	-10.56 wk	No growth
	-11 wk	STREPTOCOCCUS DYSGALACTIAE

MRI *hindfoot* w/o osteomyelitis

- # Right lower extremity cellulitis
- # Streptococcus dysgalactiae bacteremia
 - podiatry evaluated the patient recommended no surgery
 - repeat blood cultures negative
 - deescalate antibiotics to Rocephin based on sensitivities
 - Given two prosthetic valves, **ordered TEE**
 - ~~Possible ID consult based on MRI results~~
 - infectious disease consult pending TEE results

Case 1: Backstory

Medicine notes

Admit	Date	BCx results
#3 (Ruby)	Today	STREPTOCOCCUS DYSGALACTIAE
#2 (Mon)	-7 wk	STREPTOCOCCUS DYSGALACTIAE
#1 (Ruby)	-10.56 wk	No growth
	-11 wk	STREPTOCOCCUS DYSGALACTIAE

- # Right lower extremity cellulitis
- # Streptococcus dysgalactiae bacteremia
 - podiatry evaluated the patient recommended no surgery
 - repeat blood cultures negative
 - deescalate antibiotics to Rocephin based on sensitivities
 - Given two prosthetic valves, **ordered TEE**
 - ~~Possible ID consult based on MRI results~~
 - infectious disease consult pending TEE results

MRI *hindfoot* w/o osteomyelitis

**TEE continues to be delayed
due to elevated INR**

Case 1: Backstory (admission #1)

Transthoracic echo

- In the presences of prosthetic valves, TEE is the diagnostic modality of choice to evaluate SBE
- Left ventricular systolic function is normal
- Normal right ventricular systolic function

Transesophageal echo

- No stigmata of endocarditis
- Normal functioning bioprosthetic mitral and Sapien aortic valves
- Mild thickening noted in the aortic cusps in the left coronary position

Case 1: Admission #1

Admit	Date	BCx results
#3 (Ruby)	Today	STREPTOCOCCUS DYS GALACTIAE
#2 (Mon)	-7 wk	STREPTOCOCCUS DYS GALACTIAE
#1 (Ruby)	-10.56 wk	No growth
	-11 wk	STREPTOCOCCUS DYS GALACTIAE

- Got foot MRI, but of the wrong area
- Received 1 week of zyvox → ceftriaxone
- No ID consult → **Discharged**

Case 1: Between admissions

Admit	Date	BCx results
#3 (Ruby)	Today	STREPTOCOCCUS DYSGALACTIAE
#2 (Mon)	-7 wk	STREPTOCOCCUS DYSGALACTIAE
#1 (Ruby)	-10.56 wk	No growth
	-11 wk	STREPTOCOCCUS DYSGALACTIAE

Had routine follow up with structural heart team. They *noted her recent bacteremia* and **reviewed TEE with no concerns**

Case 1: Admission #2

Admit	Date	BCx results
#3 (Ruby)	Today	STREPTOCOCCUS DYSGALACTIAE
#2 (Mon)	-7 wk	STREPTOCOCCUS DYSGALACTIAE
#1 (Ruby)	-10.56 wk	No growth
	-11 wk	STREPTOCOCCUS DYSGALACTIAE

Went to Ruby ED because she had the same tremor as her prior admission (i.e. **rigors**)

Case 1: Admission #2

Admit	Date	BCx results
#3 (Ruby)	Today	STREPTOCOCCUS DYS GALACTIAE
#2 (Mon)	-7 wk	STREPTOCOCCUS DYS GALACTIAE
#1 (Ruby)	-10.56 wk	No growth
	-11 wk	ST D

Went to Ruby ED because she had the same tremor as her prior admission

WBC

23.4 

 Patient Communication

 Add MyChart Message 

 Seen

[Back to Top](#) 

Hello there,
It appears you are currently waiting in the ER waiting room. I have reviewed some of your tests that have resulted so far and would like to encourage you to continue to wait for a bed as there is at least one abnormality identified at this time. If you have any new, changing, or worsening symptoms while waiting please notify a nurse or registration personnel.

Case 1: Admission #2

Admit	Date	BCx results
#3 (Ruby)	Today	STREPTOCOCCUS DYS GALACTIAE
#2 (Mon)	-7 wk	STREPTOCOCCUS DYS GALACTIAE
#1 (Ruby)	-10.56 wk	No growth
	-11 wk	STREPTOCOCCUS DYS GALACTIAE

Went to Ruby ED because she had the same tremor as her prior admission

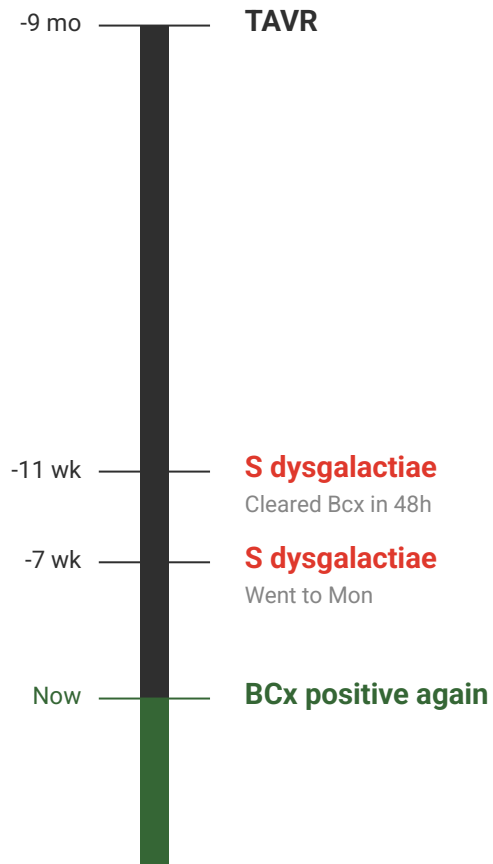
- Left without being seen (d/t wait time)
- **Went to Mon** and admitted

Had **sesamoidectomy** at Mon (a week later)

- Bone Cx had **MRSA**
- Discharged on **ceftaroline**
 - Unclear if 4 or 6 wk of Tx

Case 1: Summary

A **74 y/o F** with PMH including DM (A1c 7) c/b R DFU, CAD s/p CABG, Hx mechanical MVR (2015 & 2021) on warfarin, s/p TAVR (9 mo ago), CKD3 p/w **worsening R foot wound** and found to be **bacteremic with strep dysgalactiae** for the third time in the past 3 months



[Q1.1] You can buy
one test...



MRI of foot

TTE

TEE

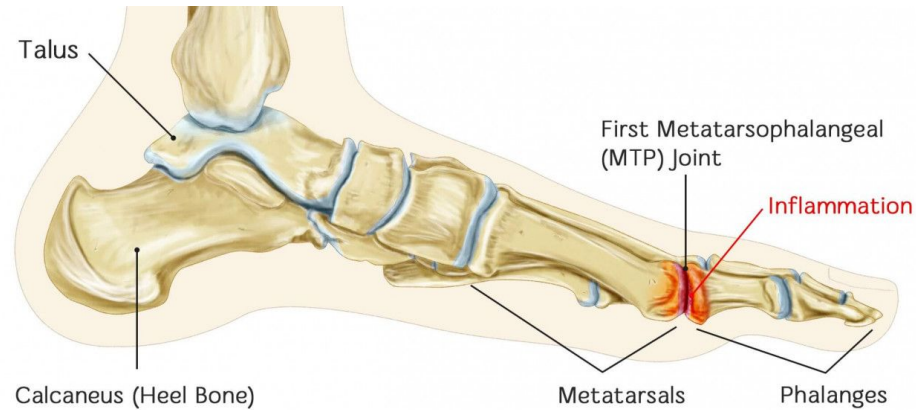
PET scan

Case 1: Hospital course

The foot

The heart

MRI forefoot: Septic arthritis / osteomyelitis
involving the great toe metatarsophalangeal joint



Case 1: Hospital course



The foot

MRI forefoot: **Septic arthritis / osteomyelitis**
involving the great toe metatarsophalangeal joint

The heart

Transthoracic echo: **adequate quality**. Normal
functioning bioprosthetic mitral and Sapien aortic
valves

Case 1: Hospital course



The foot

MRI forefoot: **Septic arthritis / osteomyelitis** involving the great toe metatarsophalangeal joint

OR: **Amputation** of right great toe

- OR Cx: **MRSA** & **E cloacae**

The heart

Transthoracic echo: **adequate quality**. Normal functioning bioprosthetic mitral and Sapien aortic valves

Case 1: Hospital course

The foot

MRI forefoot: **Septic arthritis / osteomyelitis** involving the great toe metatarsophalangeal joint

OR: **Amputation** of right great toe

- OR Cx: **MRSA** & **E cloacae**

The heart

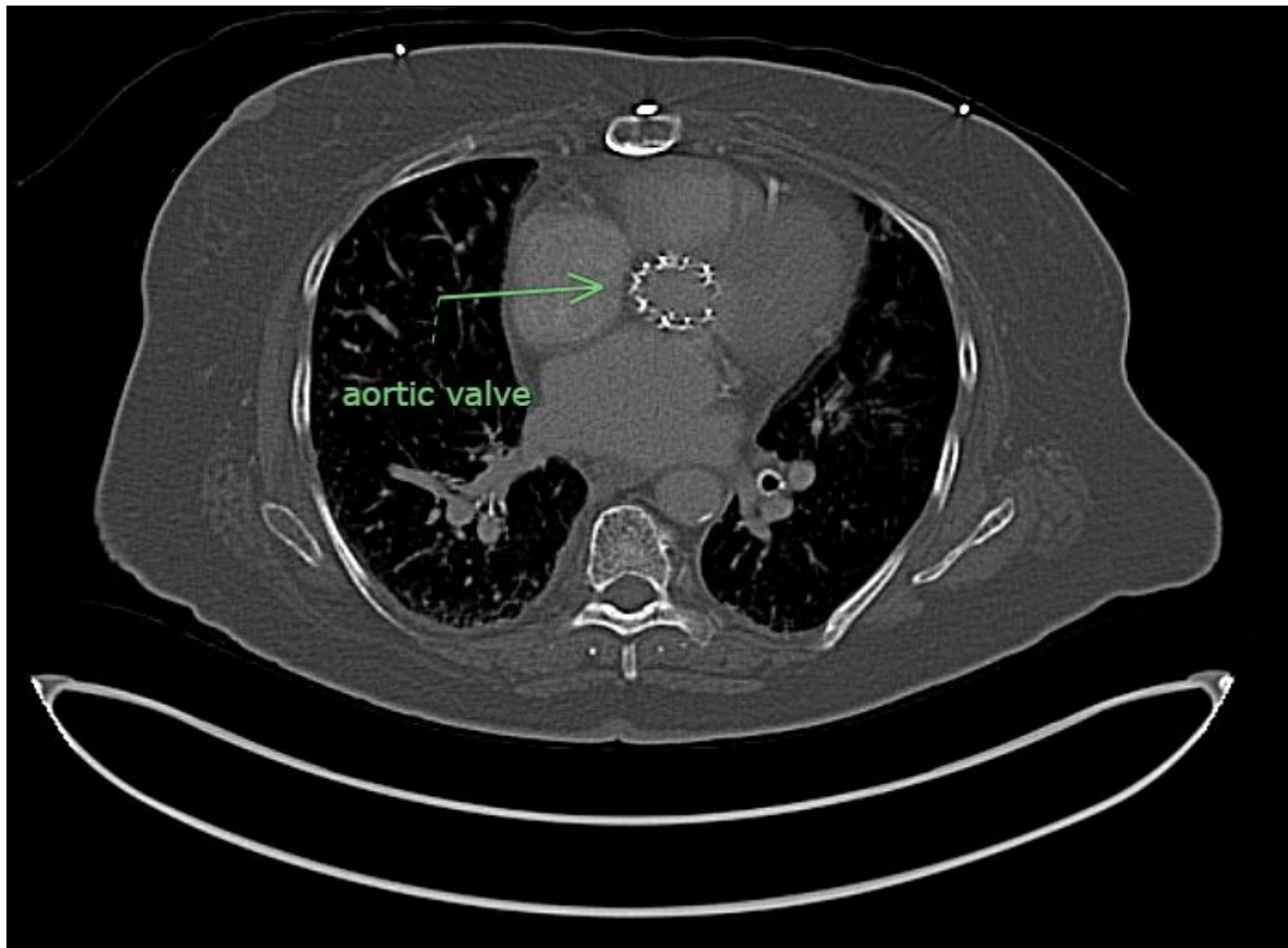
Transthoracic echo: **adequate quality**. Normal functioning bioprosthetic mitral and Sapien aortic valves

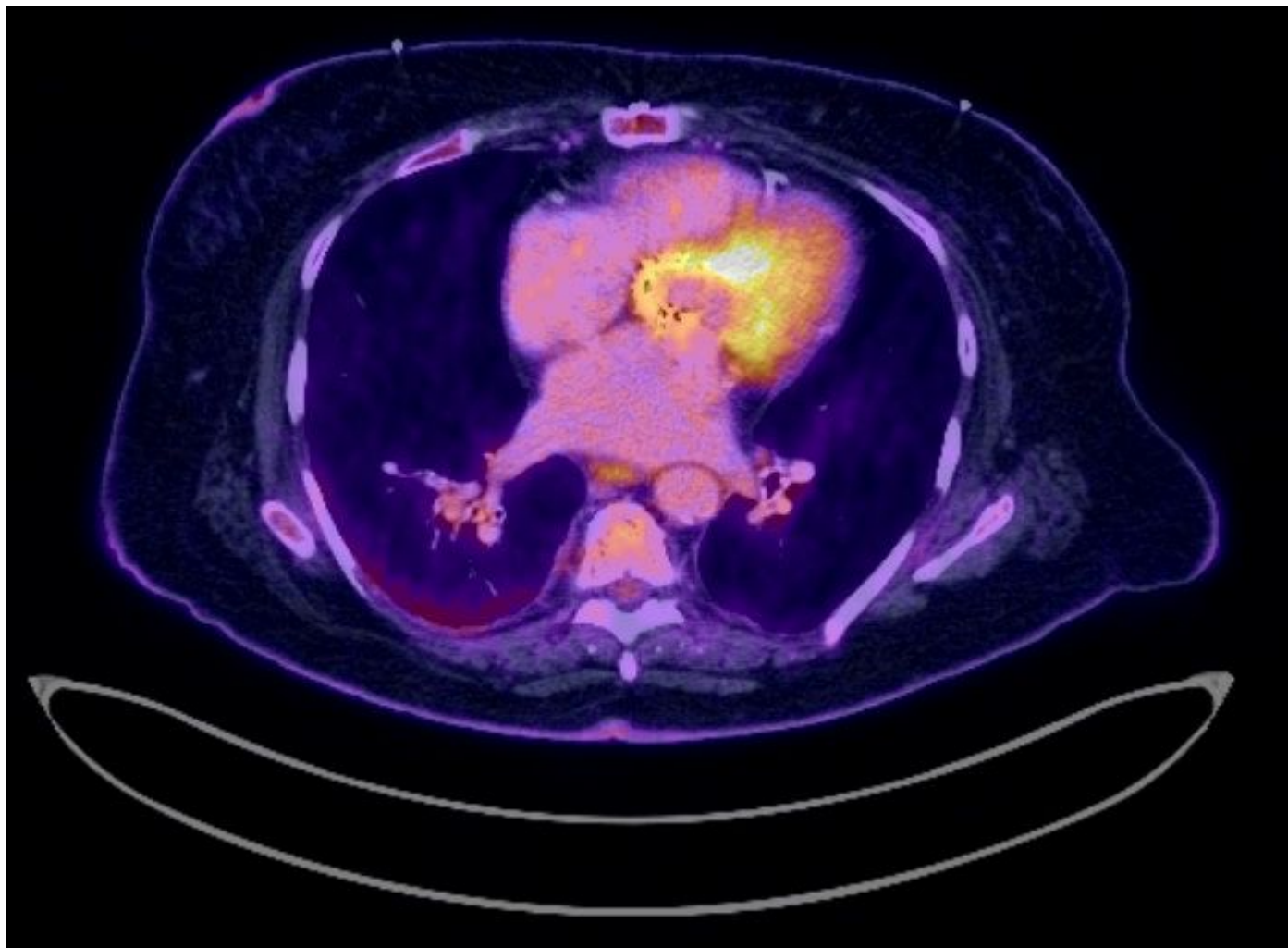
Transesophageal echo: Overall **no evidence of infective endocarditis**

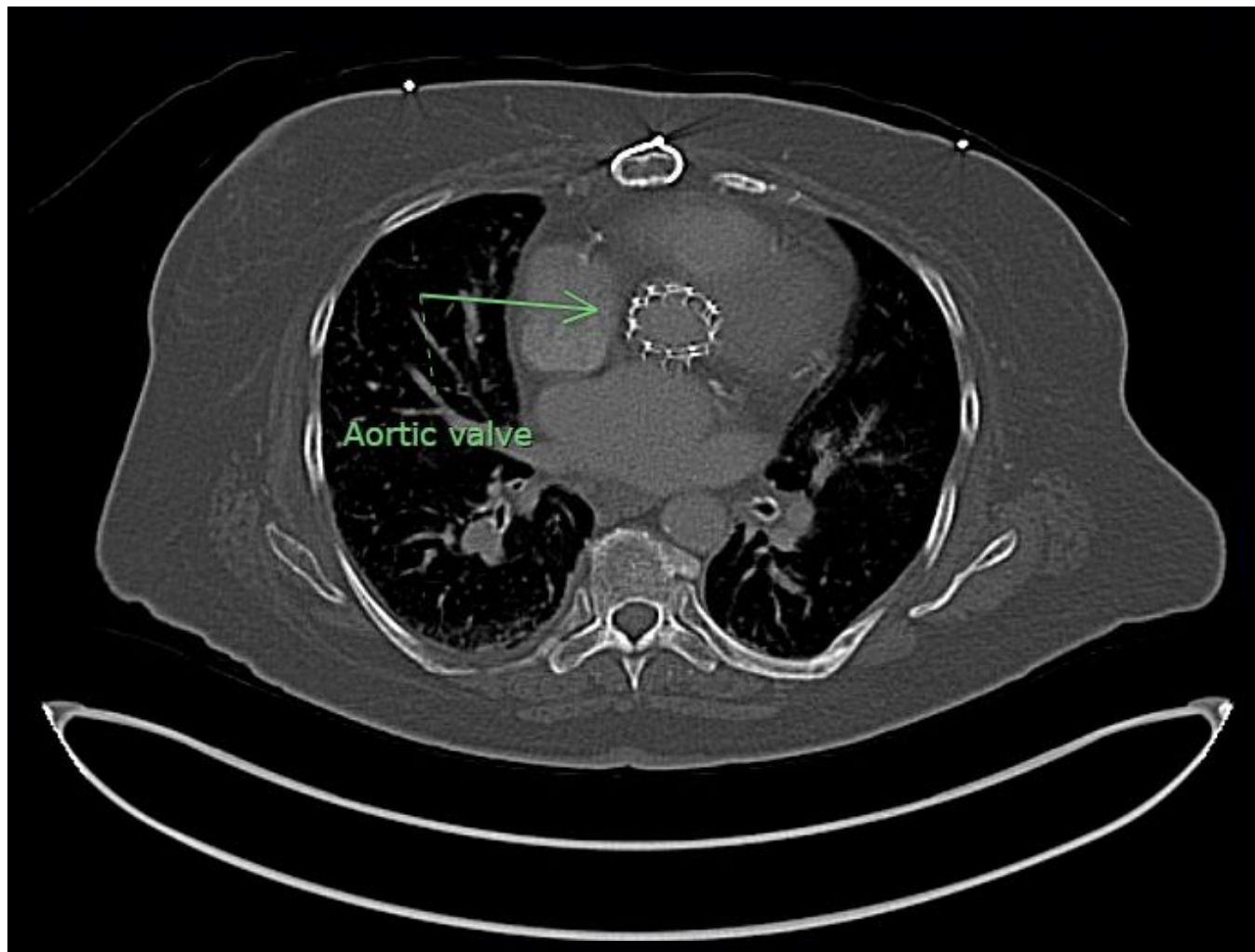
- Aortic prosthesis: Normal-appearing with no paravalvular leak or evidence of vegetation
- Mitral: **Mild leaflet thickening and leaflet restriction**. However, normal gradients and only mild mitral regurgitation. No paravalvular leak or vegetation

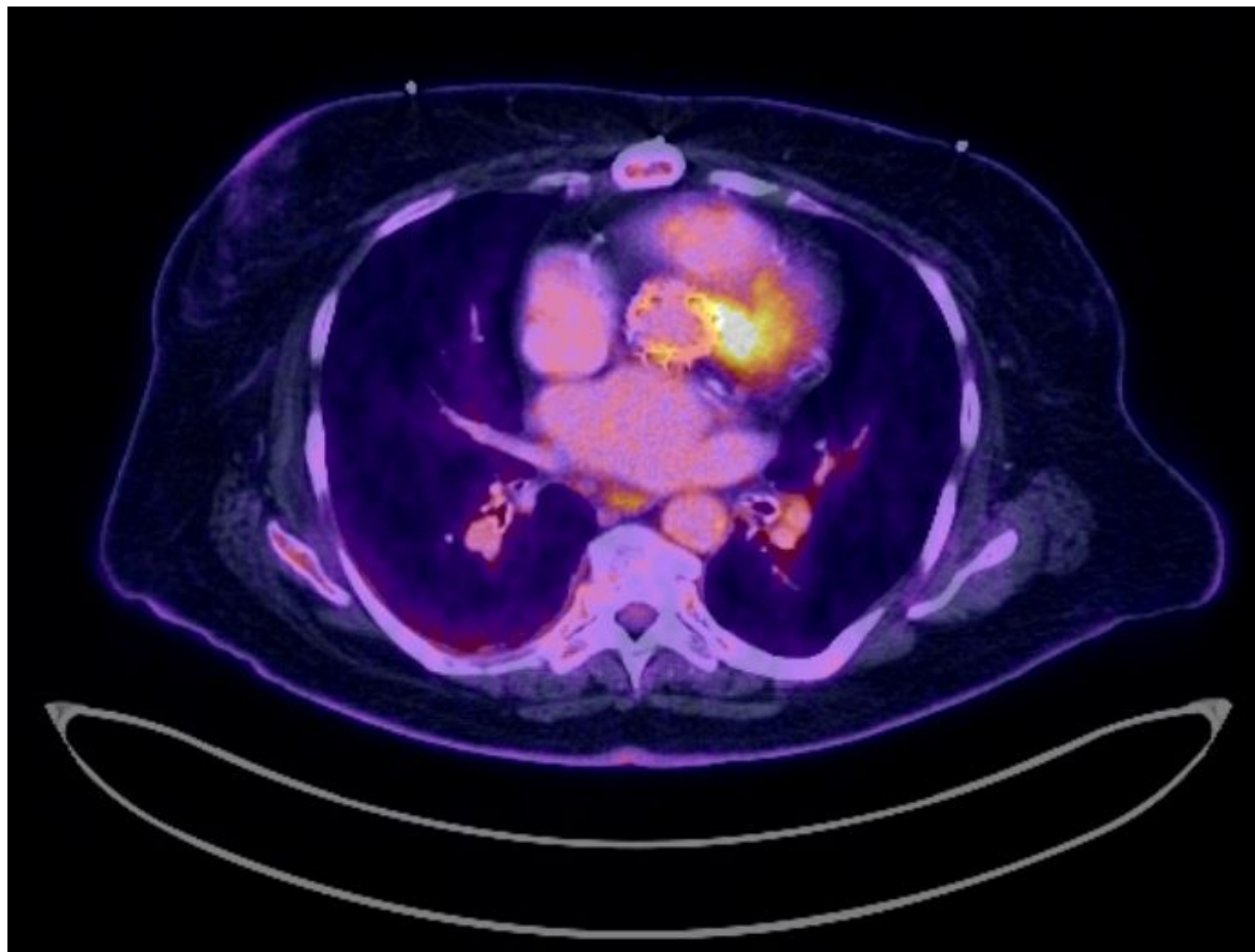
**[Q1.2] What caused
the bacteremia?**

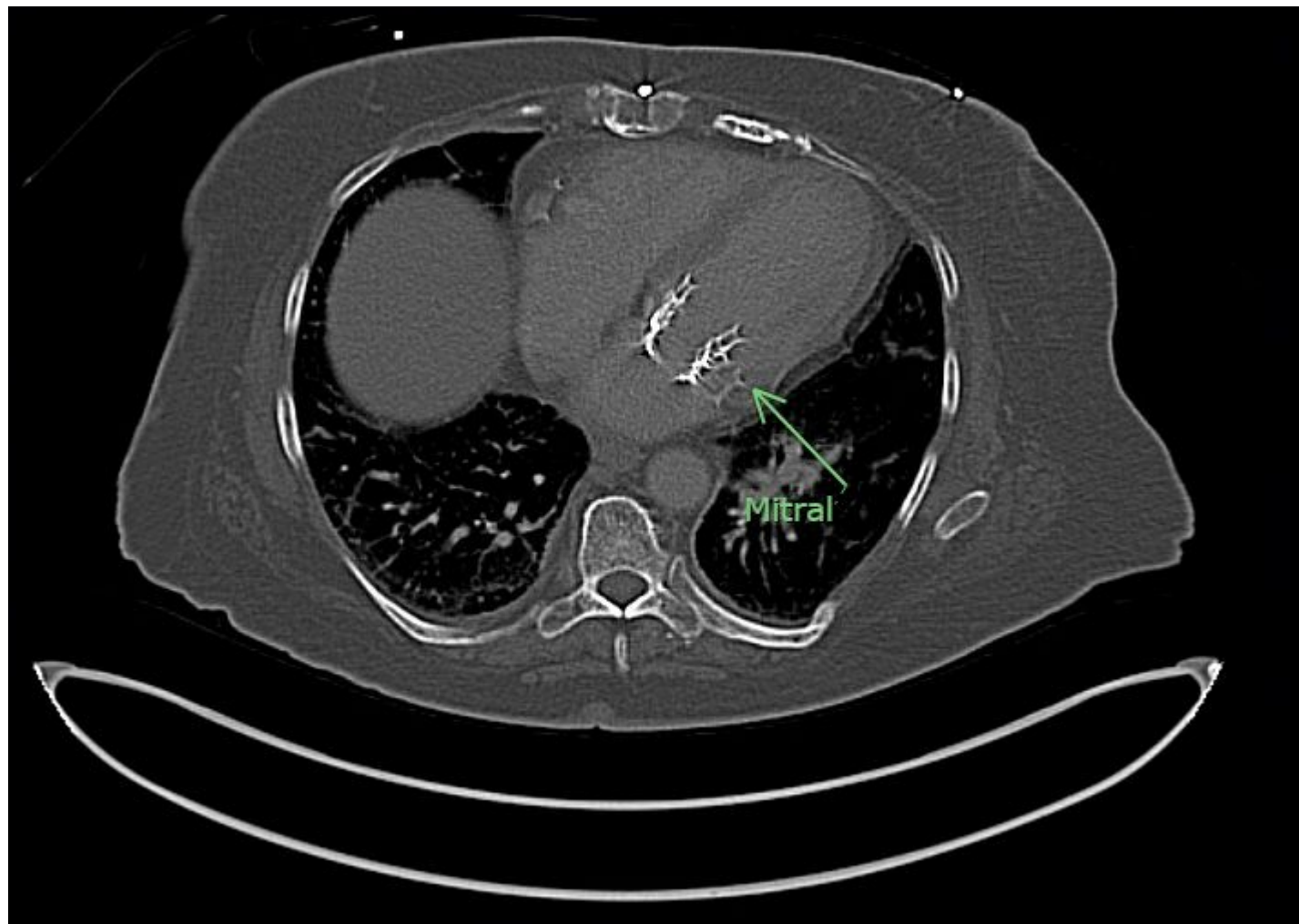


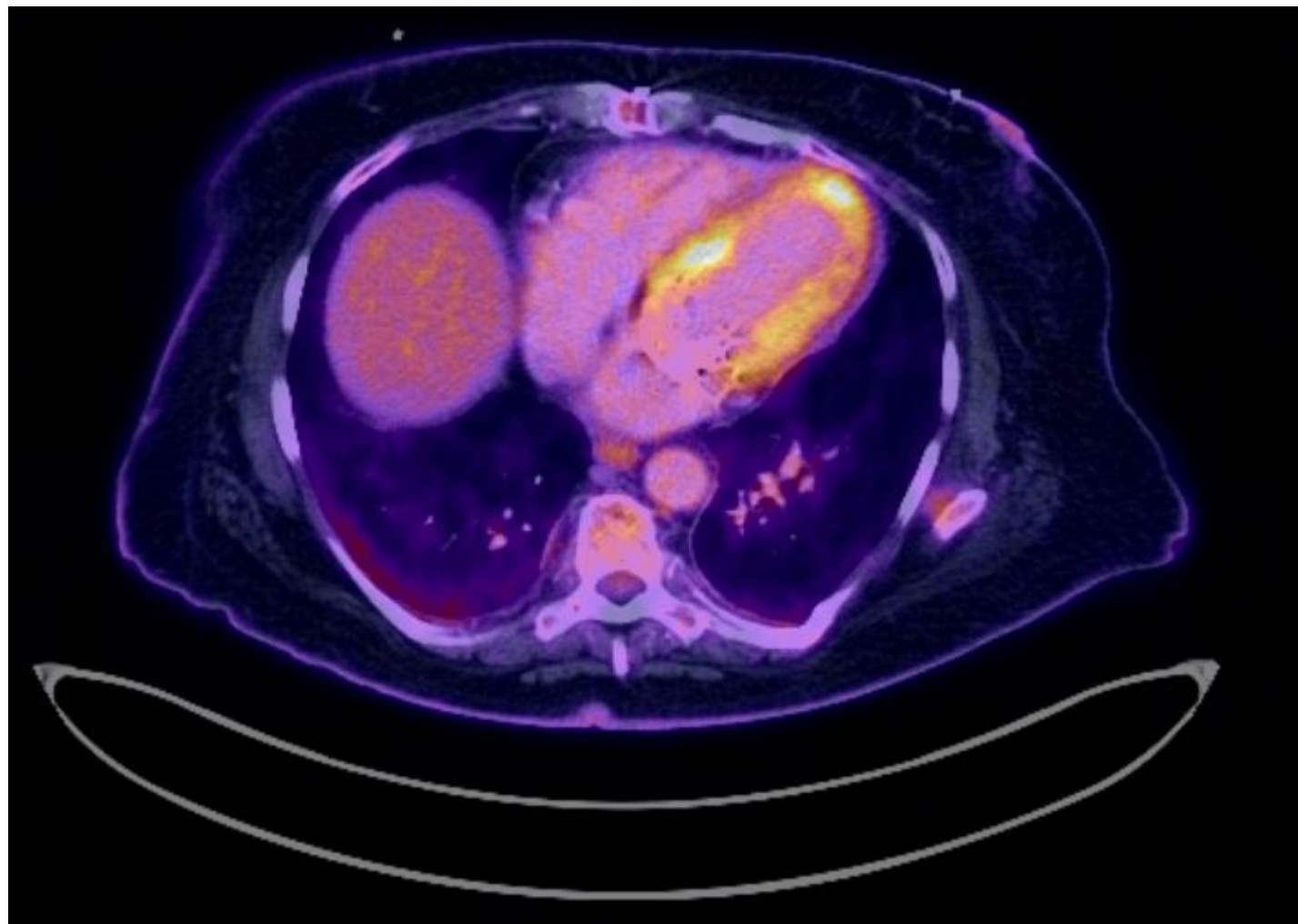












Case 1: Cardiac PET/CT

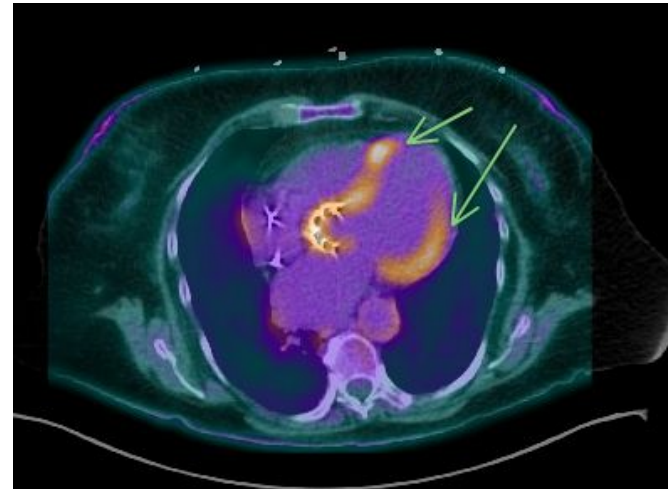
Postoperative change from mitral valve and aortic valve replacement with heterogeneous radiotracer activity, measuring SUV max up to 4.4, concerning for infection/inflammation. Mild FDG activity fusing to left ventricular wall, specifically apex area, measuring SUV max 3.5, nonspecific

IMPRESSION:

Postoperative change from mitral valve and aortic valve replacement with heterogeneous radiotracer activity, measuring SUV max up to 4.4, concerning for infection/inflammation.

Treatment:

- 6 weeks dapto + cefepime + flagyl
- Followed by suppressive amox



Non-specific LV wall uptake (arrows)

Case #2

Case 2

A **79 y/o F** with PMH including many cardiac issues (s/p TAVR, s/p PPM, VSD) p/w **incidentally discovered aortic root abscess..?**

Case 2: HPI


A **79 y/o F** with PMH including many cardiac issues (s/p TAVR, s/p PPM, VSD) p/w **incidentally discovered aortic root abscess..?**

- “Hey, so this patient had a **TAVR** five months ago
- Still had dyspnea on exertion, despite the TAVR, so outpatient structural heart team decided to do a **VSD closure**, which they did today
- Normally they go home after VSD closure, but during the procedure, it looked like she had an **aortic root abscess on the TEE**, so we got blood cultures and admitted her

No infectious symptoms, so this is kinda weird. Could y'all take a look?”



Case 2: Going back in time...





Case 2: Timeline of events

“Present day” is day 146
21 weeks / 5 months

A **79 y/o F** with PMH including many cardiac issues (s/p TAVR, s/p PPM, VSD) p/w **incidentally discovered aortic root abscess..?**

Has severe aortic stenosis, so gets **elective TAVR** (“day 0”), discharged the following day

TAVR
↓
0



Case 2: Timeline of events

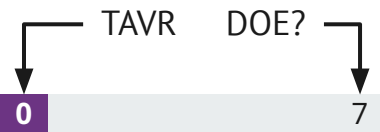
“Present day” is day 146
21 weeks / 5 months

A **79 y/o F** with PMH including many cardiac issues (s/p TAVR, s/p PPM, VSD) p/w **incidentally discovered aortic root abscess..?**

Has severe aortic stenosis, so gets **elective TAVR** (“day 0”), discharged the following day

Seemingly uncomplicated post-op course...

- PCP notes say she has some **dyspnea** with walking, but no worse than pre-TAVR





Case 2: Timeline of events

“Present day” is day 146
21 weeks / 5 months

A **79 y/o F** with PMH including many cardiac issues (s/p TAVR, s/p PPM, VSD) p/w **incidentally discovered aortic root abscess..?**

Has severe aortic stenosis, so gets **elective TAVR** (“day 0”), discharged the following day

Seemingly uncomplicated post-op course...

- PCP notes say she has some **dyspnea** with walking, but no worse than pre-TAVR
- Isolated dysuria → ED visit for **UTI** (day 18), prescribed **7 days of Keflex**





Case 2: Timeline of events

“Present day” is day 146
21 weeks / 5 months

A **79 y/o F** with PMH including many cardiac issues (s/p TAVR, s/p PPM, VSD) p/w **incidentally discovered aortic root abscess..?**

Has severe aortic stenosis, so gets **elective TAVR** (“day 0”), discharged the following day

Seemingly uncomplicated post-op course...

- PCP notes say she has some **dyspnea** with walking, but no worse than pre-TAVR
- Isolated dysuria → ED visit for **UTI** (day 18), prescribed **7 days of Keflex**

Sudden onset dizziness → ED





Case 2: Timeline of events

“Present day” is day 146
21 weeks / 5 months

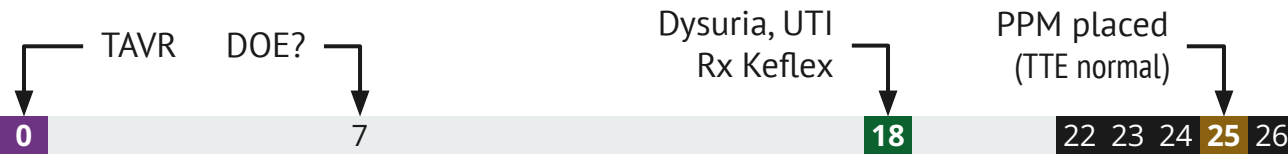
A **79 y/o F** with PMH including many cardiac issues (s/p TAVR, s/p PPM, VSD) p/w **incidentally discovered aortic root abscess..?**

Has severe aortic stenosis, so gets **elective TAVR** (“day 0”), discharged the following day

Seemingly uncomplicated post-op course...

- PCP notes say she has some **dyspnea** with walking, but no worse than pre-TAVR
- Isolated dysuria → ED visit for **UTI** (day 18), prescribed **7 days of Keflex**

Sudden onset dizziness → ED → **3rd degree heart block** (pulse 30s) → gets a **dual pacemaker**





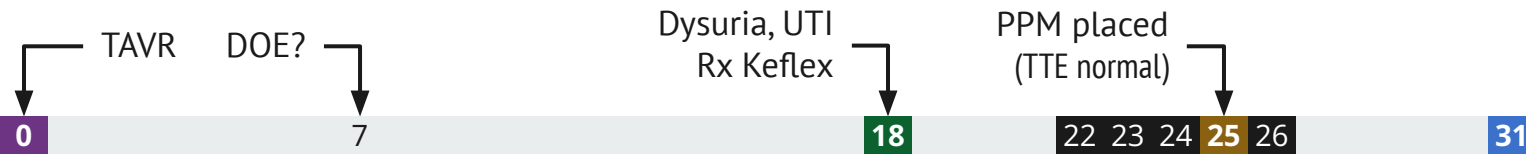
Case 2: Timeline of events

“Present day” is day 146
21 weeks / 5 months

A **79 y/o F** with PMH including many cardiac issues (s/p TAVR, s/p PPM, VSD) p/w **incidentally discovered aortic root abscess..?**

- Has severe aortic stenosis, so gets **elective TAVR** (“day 0”), discharged the following day
- Dizziness → **complete heart block** → **dual pacemaker**

Develops **isolated fevers** (to 101.5) and chills





Case 2: Timeline of events

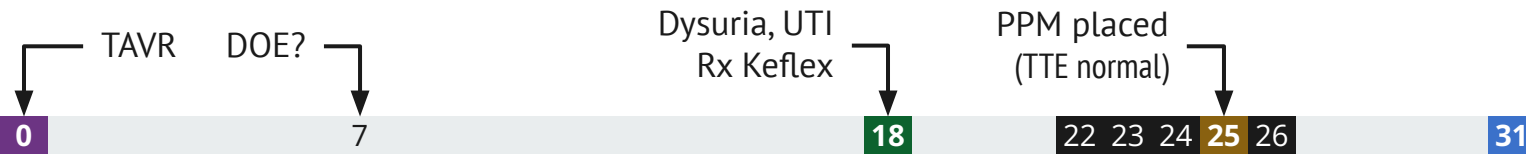
“Present day” is day 146
21 weeks / 5 months

A **79 y/o F** with PMH including many cardiac issues (s/p TAVR, s/p PPM, VSD) p/w **incidentally discovered aortic root abscess..?**

- Has severe aortic stenosis, so gets **elective TAVR** (“day 0”), discharged the following day
- Dizziness → **complete heart block** → **dual pacemaker**

Develops **isolated fevers** (to 101.5) and chills

- No other symptoms besides *sinus pressure*, PPM site looks good
- No WBC, labs pretty normal
- **No antibiotics** given, discharged home





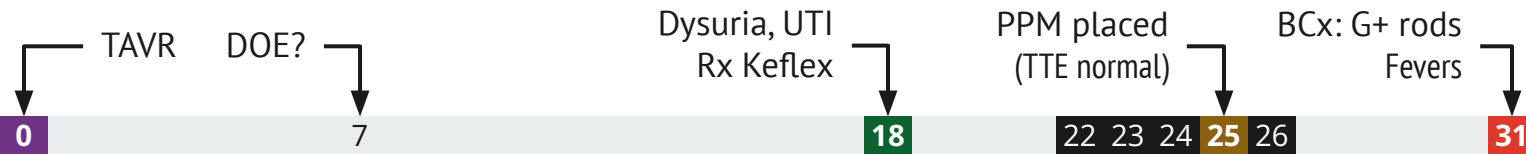
Case 2: Timeline of events

“Present day” is day 146
21 weeks / 5 months

A **79 y/o F** with PMH including many cardiac issues (s/p TAVR, s/p PPM, VSD) p/w **incidentally discovered aortic root abscess..?**

- Has severe aortic stenosis, so gets **elective TAVR** (“day 0”), discharged the following day
- Dizziness → **complete heart block** → **dual pacemaker**

Develops **fevers** to 101.5, sent home. **Blood Cx show gram positive rods** so called back to ED





Case 2: Timeline of events

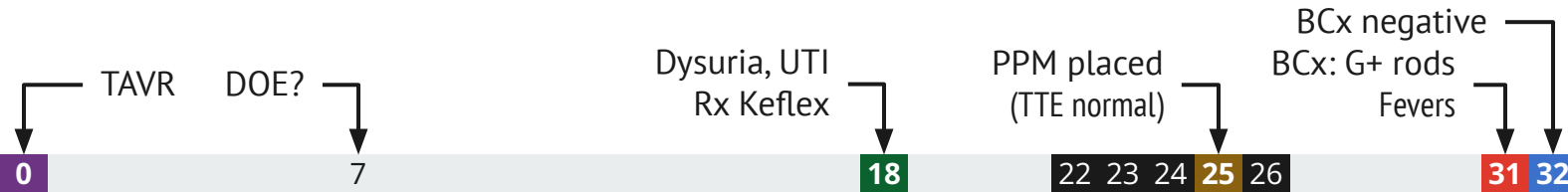
“Present day” is day 146
21 weeks / 5 months

A **79 y/o F** with PMH including many cardiac issues (s/p TAVR, s/p PPM, VSD) p/w **incidentally discovered aortic root abscess..?**

- Has severe aortic stenosis, so gets **elective TAVR** (“day 0”), discharged the following day
- Dizziness → **complete heart block** → **dual pacemaker**

Develops **fevers** to 101.5, sent home. **Blood Cx show gram positive rods** so called back to ED

- Repeat BCx (before abx) will be no growth
 - Started on a few days of vanco & Unasyn





Case 2: Timeline of events

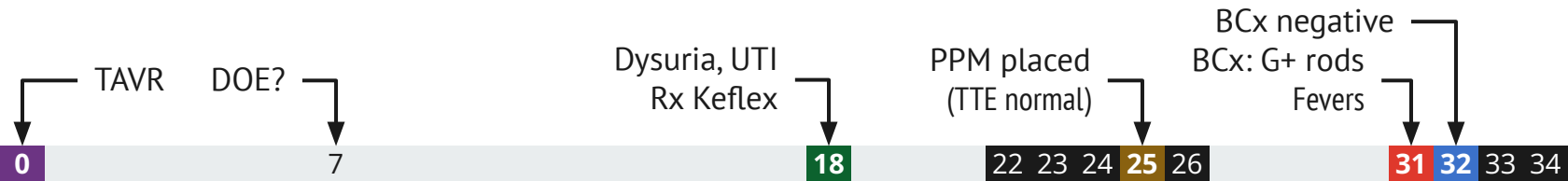
“Present day” is day 146
21 weeks / 5 months

A **79 y/o F** with PMH including many cardiac issues (s/p TAVR, s/p PPM, VSD) p/w **incidentally discovered aortic root abscess..?**

- Has severe aortic stenosis, so gets **elective TAVR** (“day 0”), discharged the following day
- Dizziness → **complete heart block** → **dual pacemaker**

Develops **fevers** to 101.5, sent home. **Blood Cx show gram positive rods** so called back to ED

- Repeat BCx (before abx) will be no growth
 - Started on a few days of vanco & Unasyn
- Still no WBC | afebrile





Case 2: Timeline of events

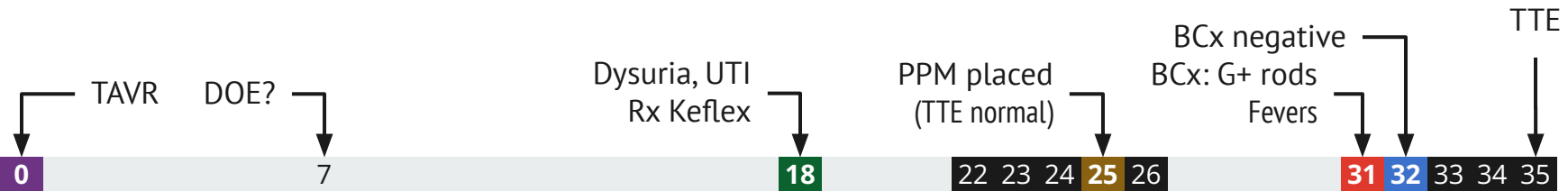
“Present day” is day 146
21 weeks / 5 months

A **79 y/o F** with PMH including many cardiac issues (s/p TAVR, s/p PPM, VSD) p/w **incidentally discovered aortic root abscess..?**

- Has severe aortic stenosis, so gets **elective TAVR** (“day 0”), discharged the following day
- Dizziness → **complete heart block** → **dual pacemaker**

Develops **fevers** to 101.5, sent home. **Blood Cx show gram positive rods** so called back to ED

- Repeat BCx (before abx) will be no growth
 - Started on a few days of vanco & Unasyn
- Still no WBC | afebrile | TTE no gross evidence of infective endocarditis (VSD, pulm HTN)
- Tele-ID consult: Likely contaminant (if TTE normal)





Case 2: Timeline of events

“Present day” is day 146
21 weeks / 5 months

A 79 y/o F with PMH i
discovered aortic ro

Corynebacterium amycolatum

Units = ug/mL

MIC

- Has severe aort
- Dizziness → coi

Penicillin

0.5 Intermed

l, VSD) p/w indentially

ed the following day

- Develops fevers to 10

Meropenem

0.12 Suscept

Ceftriaxone

1 Suscept

Develops fevers to 10

Linezolid

0.25 Suscept

; so called back to ED

- Repeat BCx (bet
 - Started on

Vancomycin

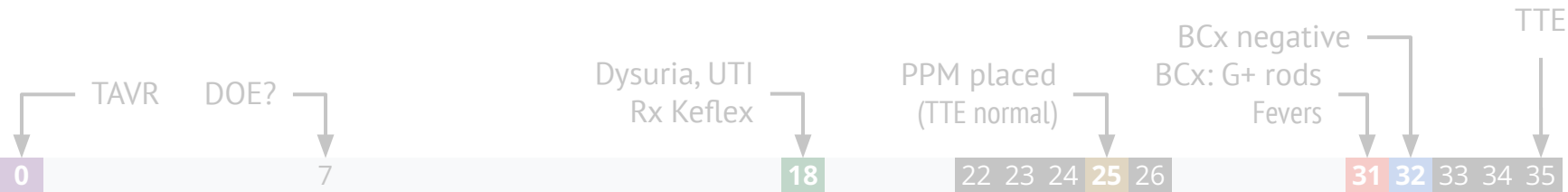
0.5 Suscept

- Still no WBC |
- Tele-ID consult:

Gentamicin

<=2 Suscept

Performed By: ARUP Laboratories





Case 2: Timeline of events


“Present day” is day 146
21 weeks / 5 months

A **79 y/o F** with PMH including many cardiac issues (s/p TAVR, s/p PPM, VSD) p/w **incidentally discovered aortic root abscess..?**

- Has severe aortic stenosis, so gets **elective TAVR** (“day 0”), discharged the following day
- Dizziness → **complete heart block** → **dual pacemaker**
- **Fevers** (with **?Corynebacterium**) but no growth after repeating before abx

Does fine **without developing any new symptoms** (dyspnea is ongoing but stable)

Zooming timeline out now





Case 2: Timeline of events

“Present day” is day 146
21 weeks / 5 months

A **79 y/o F** with PMH including many cardiac issues (s/p TAVR, s/p PPM, VSD) p/w **incidentally discovered aortic root abscess..?**

- Has severe aortic stenosis, so gets **elective TAVR** (“day 0”), discharged the following day
- Dizziness → **complete heart block** → **dual pacemaker**
- **Fevers** (with **?Corynebacterium**) but no growth after repeating before abx

Does fine **without developing any new symptoms** (dyspnea is ongoing but stable)

Two more rounds of **Keflex** (for urinary symptoms), but otherwise no antibiotics

0

18

25

31

88

131

147

TAVR

Keflex PPM BCx

Keflex (UTI)

Keflex (UTI)



Case 2: Timeline of events

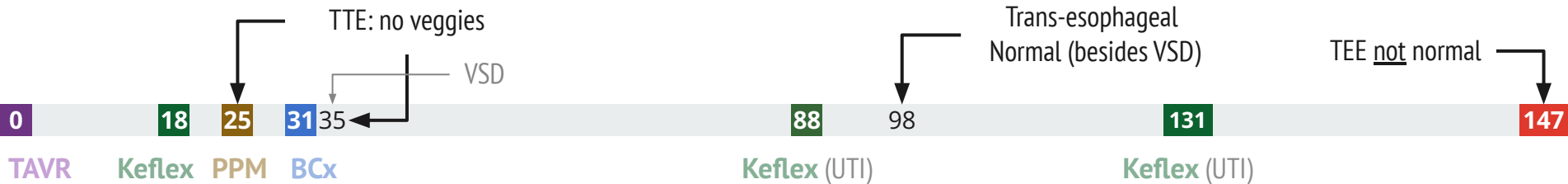
“Present day” is day 146
21 weeks / 5 months

A **79 y/o F** with PMH including many cardiac issues (s/p TAVR, s/p PPM, VSD) p/w **incidentally discovered aortic root abscess..?**

- Has severe aortic stenosis, so gets **elective TAVR** (“day 0”), discharged the following day
- Dizziness → **complete heart block** → **dual pacemaker**
- **Fevers** (with **?Corynebacterium**) but no growth after repeating before abx

Does fine **without developing any new symptoms** (dyspnea is ongoing but stable)

Two more rounds of **Keflex** (for urinary symptoms), but otherwise no antibiotics. Elective admission for VSD repair



Case 2: Back to the consult



Case 2: Social history, exposures, & risk factors



Geographic & Travel	<ul style="list-style-type: none">• Lives with her husband in WV• No travel since TAVR
Occupational	(resident took the HPI, so this was not documented)
Substance & needles	<ul style="list-style-type: none">• No alcohol or tobacco• No drugs
Animals	<ul style="list-style-type: none">• Has a dog, no bites or scratches• No other animals
Exposures	No known tick/mosquito exposures, freshwater exposure, soil/landscaping/dust exposure, or well water exposures

Case 2: Physical exam

BP	131/52	Pulse	61	SpO2	93 %
Temp	36.8 °C (98.2 °F)	RR	18	BMI	41 kg/m ²
General	Alert and oriented, NAD, vitals reviewed				
HEENT	NCAT; trachea appears midline, no gross LAD; EOMI				
Resp	Normal respiratory effort, symmetric chest rise				
CV	2/6 murmur heard best at RSB				
GI	Non-distended; no TTP				
Extremities	No clubbing, cyanosis, or edema				
Neuro/MSK	Moves extremities				
Skin	No rash				

Case 2: Labs

CBC	Result
WBC	7.0
Hgb	14.2
Platelets	208
Neut %	69
Lymph %	23
Eos %	0%

Chem7	Result
Na	140
K	4.0
HCO3	25
BUN	10
Cr	.64

Other	Result
CRP	5.3

Case 2: Labs

CBC	Result
WBC	7.0
Hgb	14.2
Platelets	208
Neut %	69
Lymph %	23
Eos %	0%

Chem7	Result
Na	140
K	4.0
HCO3	25
BUN	10
Cr	.64

Other	Result
CRP	5.3

Micro Hx	Result
Urine Cx	The past couple have grown friendly isolates of E coli
Prior BCx	Corynebacterium
Current BCx	In process

Case 2: Intra-"op" TEE

- **Right atrium:** Echo density in right atrium suggestive of pacer lead
- **Aortic valve:** Normal aortic valve gradient. There is a transcatheter valve in the aortic position. 29 Navitor valve. There is no evidence of paravalvular aortic regurgitation.
- **Aorta:** TAVR architecture seen in proximal ascending aorta. There is **fluid collection seen nearly circumferential**. This is concerning for potential abscess.

Conclusions

1. There is a color jet consistent with a membranous defect favored to be a Gerbode defect. There is left to right flow seen above the level of the tricuspid valve. There does not appear to be interventricular communication. The defect was measured 7.4 to 7.8mm in diameter. This defect was closed with an amplatzer device. Following placement there was no apparent residual flow. The closure device does not appear to interfere with TV functioning.
2. There is **periaortic fluid** that is **concerning for possible abscess**.
3. LVEF estimated 45-55%. RV function is normal.

Case 2: Summary

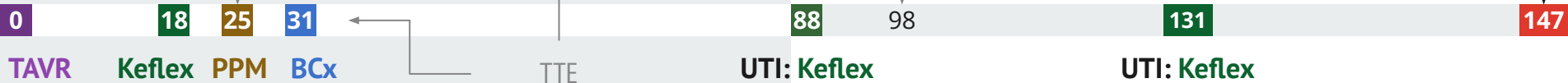A **79 y/o F** with many medical problems s/p **TAVR** (-21 wk), heart block s/p **PPM** (-18 wk) who had a **self resolving febrile episode** six days after PPM placement (31 days after TAVR) where BCx grew GPR (cleared w/o abx)

Now admitted for *elective* VSD closure, but was (incidentally?) found to have **periaortic fluid** near the graft

Labs	Result
WBC	7.0
CRP	5.3

Never has had an elevated WBC

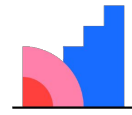
Trans-esophageal echo (intra-op):
Circumferential periaortic fluid collection concerning for possible abscess



Case 2: Micro data

- Blood cultures finalized at 5 days **without any growth**
- Labs are good on daptomycin (but they were never abnormal)

[Q2.1] Infectious or
not?

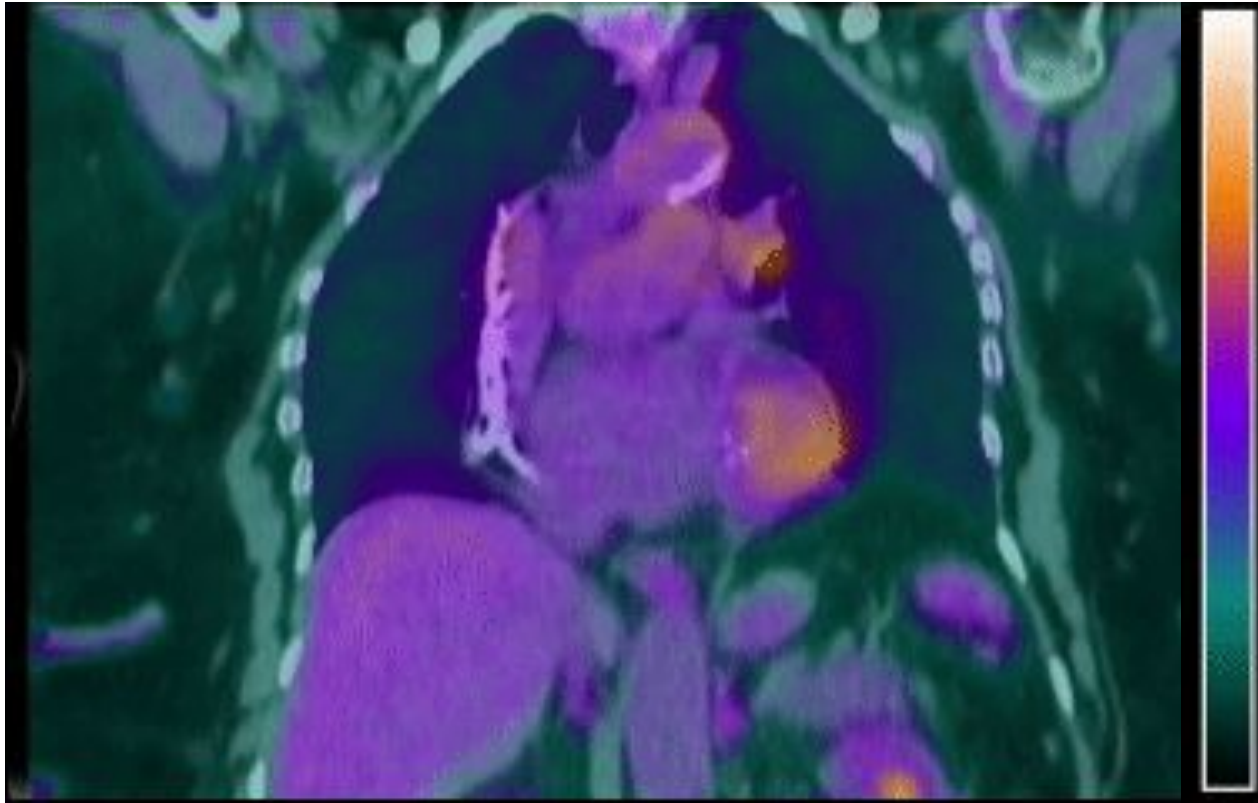


Mentimeter

Next steps?

KARIUS

Case 2: Cardiac PET/CT

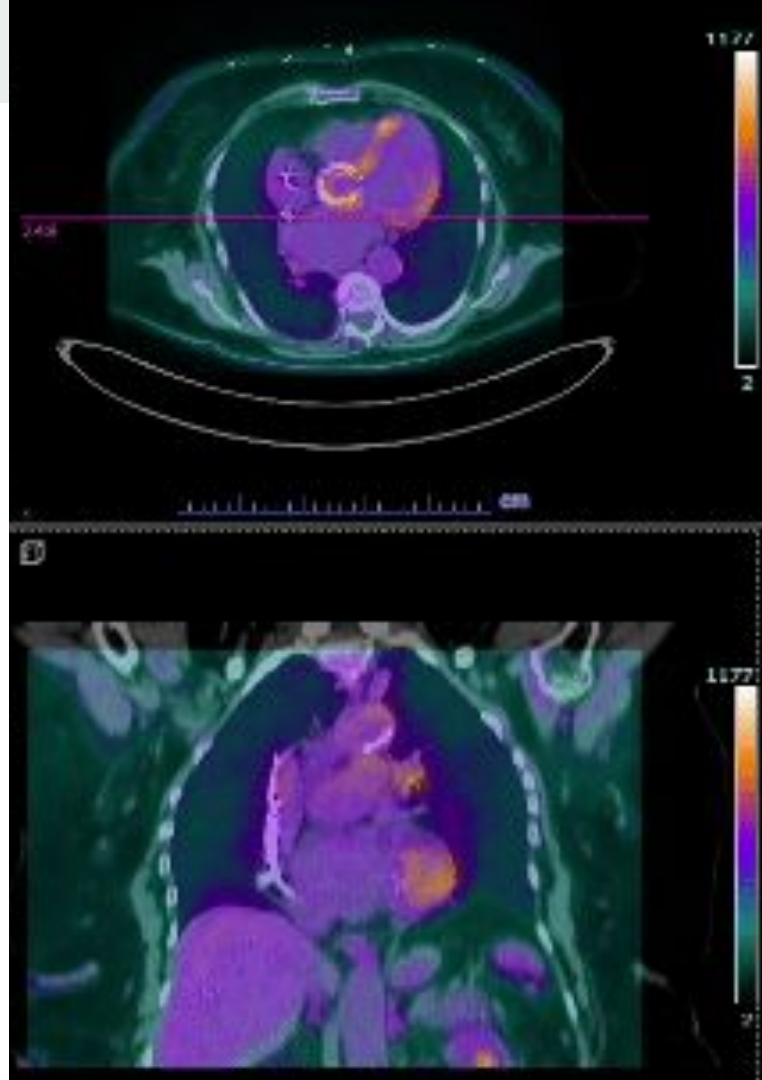


Case 2: Cardiac PET/CT

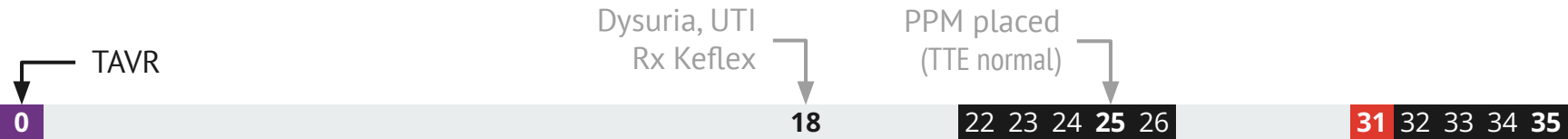
Left chest pacemaker and leads in place. Diffuse myocardial heterogeneous FDG uptake is noted, probably related to suboptimal patient preparation. Focal uptake along the aortic root (SUV 5.6) with subsequent increased FDG uptake on delayed images (SUV 8.8). These findings appear persistent in the nonattenuation corrected images and extends to the proximal aspect of the TAVR hardware. The rest of the hardware demonstrates mild heterogeneous diffuse FDG uptake, probably inflammatory and appears less prominent on the delayed images

IMPRESSION

Focal radiotracer **uptake at the aortic root** with progressive **increase in metabolic activity on delayed images, suspicious for an infectious process**

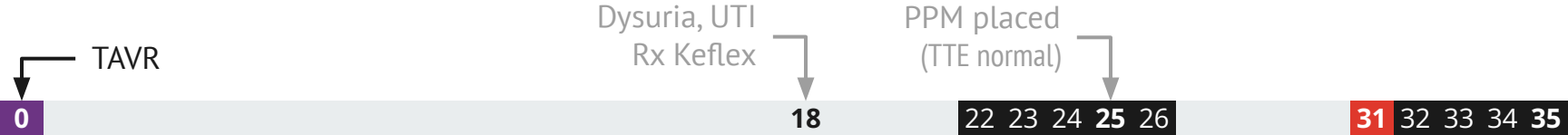


Case 2: When did she develop endocarditis?



Case 2: When did she develop endocarditis?

Already had possible endocarditis
Minor (x3)




Case 2: When did she develop endocarditis?

Already had possible endocarditis
Minor (x3)



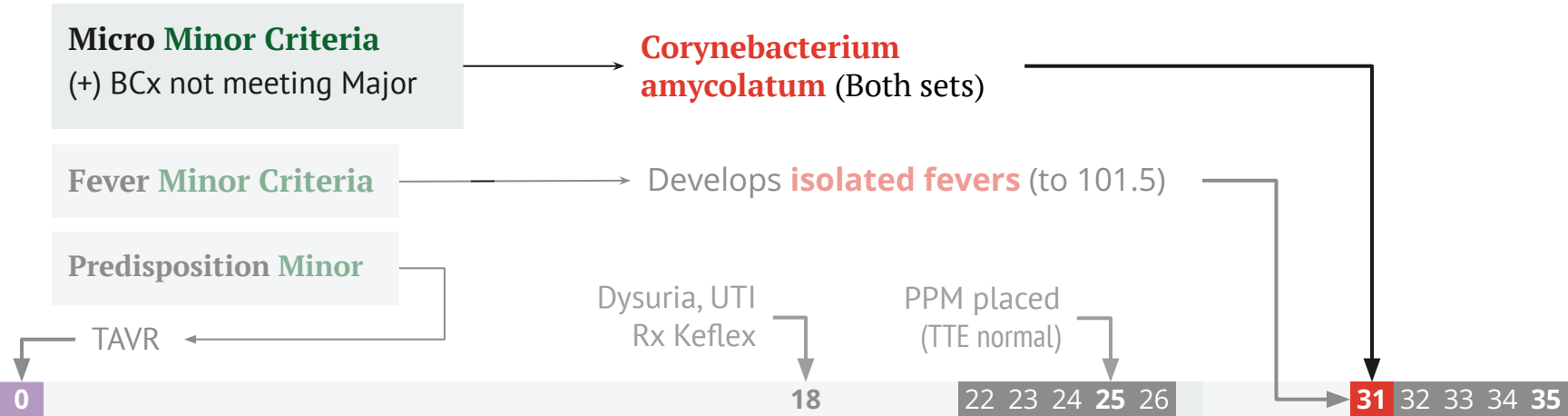
Case 2: When did she develop endocarditis?

Already had possible endocarditis
Minor (x3)



Case 2: When did she develop endocarditis?

Already had possible endocarditis
Minor (x3)



Case 2: When did she develop endocarditis?

Imaging Major Criteria

(1) Echocardiography showing vegetation, valvular/leaflet perforation... or intracardiac fistula [Communication between 2 neighboring cardiac chambers through a perforation]

Transthoracic echo

- There is no gross evidence of infective endocarditis
- Ejection Fraction is 65.8 %. Left ventricular systolic function is normal...There appears to be a **turbulent flow across the interventricular septum**, suggestive of a **ventricular septal defect**
- Normal right ventricular size

Micro Minor Criteria

(+) BCx not meeting Major

Corynebacterium amycolatum (Both sets)

Fever Minor Criteria

Develops **isolated fevers** (to 101.5)

Predisposition Minor

TAVR

Dysuria, UTI
Rx Keflex

PPM placed
(TTE normal)

0

18

22 23 24 25 26

31 32 33 34 35

Case 2: Not so (PEN)fast...

Oh I almost forgot...

Allergies (17)



Allergies (17)

Cefdinir	Anaphylaxis	
Citrus And Derivatives	Anaphylaxis	
Iodine And Iodide Containing Products	Hives/ Urticaria	
Lemon	Anaphylaxis	
Levofloxacin	Swelling	Assessed on [REDACTED] per HPI. Patient reported swelling of face and throat itching
Mango	Anaphylaxis	
Nut - Unspecified	Anaphylaxis	
Omeprazole	Rash	Swelling in lips , rash
Sodium Citrate	Anaphylaxis	
Benadryl [diphenhydramine Hcl]		Hx nut allergy but takes generic OTC at home Reports she can take IV benadryl
Citric Acid	Other Adverse Reaction (Add comment)	Tingling in lips, and throat
Macrochantin [nitrofurantoin Macrocrystal]		sick to her stomach and a "weird feeling all over"
Penicillins		Assessed on [REDACTED] per HPI. Swelling in arm of administration at age of 16, penicillin given IM.
Sulfa (sulfonamides)		Assessed on [REDACTED] per HPI. Patient reported severe nausea and "weird feeling".
Tetracycline		Throat, tongue, mouth went numb, lost feeling.
Vancomycin		Assessed on [REDACTED] per HPI. Patient reported flushing and itching.
Adhesive	Itching	

Case 2: Allergy Hx

Doxycycline

- **Numbness & tingling** of lips, mouth, throat, tongue
 - Occurs **within minutes**
- Similar to many of her other drug allergies

Case 2: Allergy Hx

Doxycycline

- **Numbness & tingling** of lips, mouth, throat, tongue
 - Occurs **within minutes**
- Similar to many of her other drug allergies

Cefdinir - Cannot recall details

- Chart say **anaphylaxis**
- Never issues with **cephalexin** (different R1 and R2 from cefdinir)

Penicillin - Swelling in her arm after IM injection at age 16

Case 2: Allergy Hx

Doxycycline

- **Numbness & tingling** of lips, mouth, throat, tongue
 - Occurs **within minutes**
- Similar to many of her other drug allergies

Cefdinir - Cannot recall details

- Chart say **anaphylaxis**
- Never issues with **cephalexin** (different R1 and R2 from cefdinir)

Penicillin - **Swelling in her arm** after IM injection at age 16

- **Levofloxacin** - **Throat itching** & swelling of face
- **Nitrofurantoin** - **Sick to her stomach** and “felt weird all over”
- **Sulfa** - **Severe nausea** and “weird feeling”
- **Vanco** - **Flushing** and itching

Case 2: Allergy challenge

Doxycycline - Numbness & tingling of lips, mouth, throat, tongue. Occurs within minutes. Similar to many of her other allergies

Seen by allergy

Has been on **8+ weeks of daptomycin** while waiting on allergy appointment

Other allergies/reactions

- **Cefdinir** - Chart say **anaphylaxis**, but patient doesn't recall details. No issues with cephalexin; had arm swelling with IM penicillin
- **Levofloxacin** - **throat itching** & swelling of face
- **Nitrofurantoin** - Sick to her stomach and "felt weird all over"
- **Sulfa** - Severe nausea and "weird feeling"
- **Vanco** - Flushing and itching

Case 2: Allergy challenge

Doxycycline - Numbness & tingling of lips, mouth, throat, tongue. Occurs within minutes. Similar to many of her other allergies

Seen by allergy

- **Passes PO doxy challenge** in office

Other allergies/reactions

- **Cefdinir** - Chart say **anaphylaxis**, but patient doesn't recall details. No issues with cephalexin; had arm swelling with IM penicillin
- **Levofloxacin** - **throat itching** & swelling of face
- **Nitrofurantoin** - Sick to her stomach and "felt weird all over"
- **Sulfa** - Severe nausea and "weird feeling"
- **Vanco** - Flushing and itching

Case 2: Allergy challenge

Doxycycline - Numbness & tingling of lips, mouth, throat, tongue. Occurs within minutes. Similar to many of her other allergies

Seen by allergy

- **Passes PO doxy challenge** in office
- Calls the next day saying “numbness/tingling of her lips, tongue and roof of mouth” after challenge

Other allergies/reactions

- **Cefdinir** - Chart say **anaphylaxis**, but patient doesn't recall details. No issues with cephalexin; had arm swelling with IM penicillin
- **Levofloxacin** - **throat itching** & swelling of face
- **Nitrofurantoin** - Sick to her stomach and “felt weird all over”
- **Sulfa** - Severe nausea and “weird feeling”
- **Vanco** - Flushing and itching

Case 2: Allergy challenge

Doxycycline - Numbness & tingling of lips, mouth, throat, tongue. Occurs within minutes. Similar to many of her other allergies

Seen by allergy

- **Passes PO doxy challenge** in office
- Calls the next day saying “numbness/tingling of her lips, tongue and roof of mouth” after challenge

Switch **doxy** → **linezolid**

Other allergies/reactions

- **Cefdinir** - Chart say **anaphylaxis**, but patient doesn't recall details. No issues with cephalexin; had arm swelling with IM penicillin
- **Levofloxacin** - **throat itching** & swelling of face
- **Nitrofurantoin** - Sick to her stomach and “felt weird all over”
- **Sulfa** - Severe nausea and “weird feeling”
- **Vanco** - Flushing and itching

Case 2: Allergy challenge

Doxycycline - Numbness & tingling of lips, mouth, throat, tongue. Occurs within minutes. Similar to many of her other allergies

Seen by allergy

- **Passes PO doxy challenge** in office
- Calls the next day saying “numbness/tingling of her lips, tongue and roof of mouth” after challenge

Switch **doxy** → **linezolid**

- Calls the next day saying “same thing happening” with **Zyvox**

Other allergies/reactions

- **Cefdinir** - Chart say **anaphylaxis**, but patient doesn't recall details. No issues with cephalexin; had arm swelling with IM penicillin
- **Levofloxacin** - **throat itching** & swelling of face
- **Nitrofurantoin** - Sick to her stomach and “felt weird all over”
- **Sulfa** - Severe nausea and “weird feeling”
- **Vanco** - Flushing and itching

Case 2: Allergy challenge

Doxycycline - Numbness & tingling of lips, mouth, throat, tongue. Occurs within minutes. Similar to many of her other allergies

Seen by allergy

- **Passes PO doxy challenge** in office
- Calls the next day saying “numbness/tingling of her lips, tongue and roof of mouth” after challenge

Switch **doxy** → **linezolid**

- Calls the next day saying “same thing happening” with **Zyvox**
- Resumed **dapto OPAT**

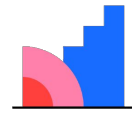
Other allergies/reactions

- **Cefdinir** - Chart say **anaphylaxis**, but patient doesn't recall details. No issues with cephalexin; had arm swelling with IM penicillin
- **Levofloxacin** - **throat itching** & swelling of face
- **Nitrofurantoin** - Sick to her stomach and “felt weird all over”
- **Sulfa** - Severe nausea and “weird feeling”
- **Vanco** - Flushing and itching

Has been on **8+ weeks of daptomycin** while waiting on allergy appointment

**[Q2.2] Would you
ever stop
antibiotics?**

For endovascular infection



Mentimeter

Discussion



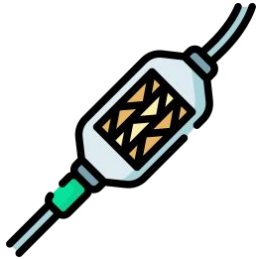Links to articles discussed
here



Objectives

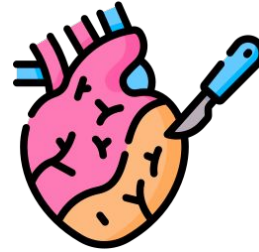
- Differentiate the presentation of **endocarditis in TAVR** (Transcatheter Aortic Valve Replacement) **compared to SAVR** (Surgical Aortic Valve Replacement), including
 - **Clinical manifestations**
 - **Microbiology**
 - **Echo findings** (and why it may be a **good idea to get a PET/CT**)
- Review the use of **PET/CT for endocarditis**, including
 - **Practical considerations** including **patient prep** and what **radiology is looking at**
 - **Indications for PET/CT** with a focus on **endocarditis** as well as other indications listed in the 2024 guidelines (**CIED & LVAD**)
- Appraise the very limited data on **serial PET/CTs in the long term monitoring** of endovascular infections

TAVR vs SAVR



Transcatheter **Aortic Valve Replacement**
(TAVI is implantation)

First TAVR was done in [2002](#)



Surgical **Aortic Valve Replacement**

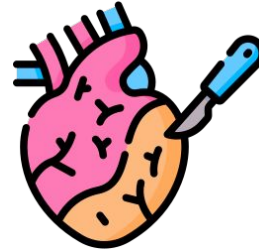
First SAVR was 1952

TAVR vs SAVR



Transcatheter **Aortic Valve Replacement**
(TAVI is implantation)

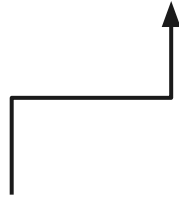
First TAVR was done in 2002



Surgical **Aortic Valve Replacement**

First SAVR was 1952

Modified Duke's criteria was 2000



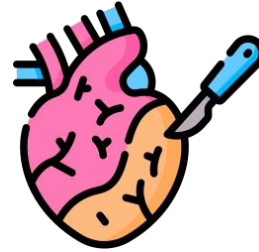
TAVR vs SAVR



Transcatheter Aortic Valve Replacement
(TAVI is implantation)

First TAVR was done in 2002

- Originally for high risk surgical candidates
- Becoming **more popular** for low/intermediate risk

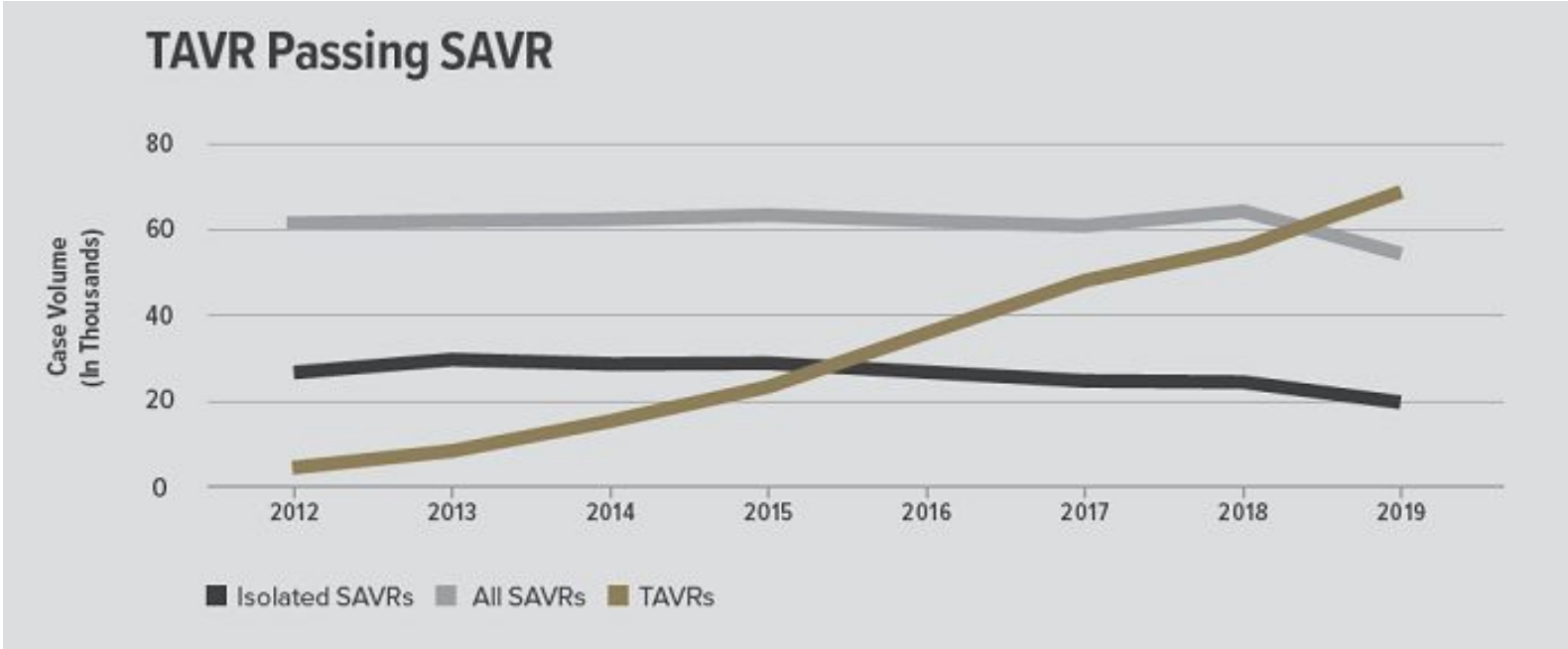


Surgical Aortic Valve Replacement

First SAVR was 1952

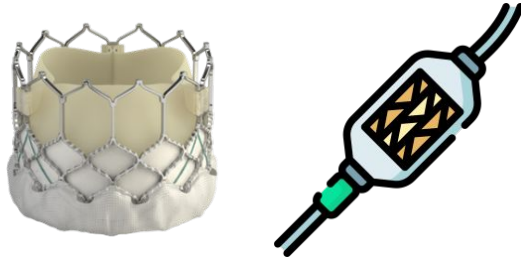
- Preferred in younger patients (not as good data on how long TAVR lasts)
- Longer recovery time since it's an open surgery

TAVR vs SAVR




TAVR vs SAVR

TAVR



- Accessed through **the groin**
- **More metal** around the valve (because of the stent frame)
- May be **balloon-expandable** or **self-expanding**

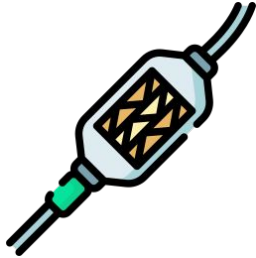SAVR



- Open surgery
- Mechanical or bioprosthetic (all TAVRs are bioprosthetic)
- Honestly, no idea how they do them

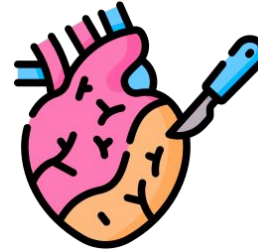
TAVR vs SAVR

TAVR



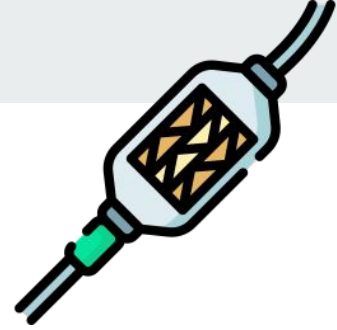Most of the **new aortic valves** in the present era are TAVRs

SAVR



Most of the **data & experience** has been from SAVR [2]

TAVR endocarditis



Compared to SAVR endocarditis...

Lower rates of

↓ fever [2][4]

↓ embolic phenomenon (stroke, emboli) [4]

↓ Aortic regurg [4]

TAVR endocarditis



Compared to SAVR endocarditis...

Lower rates of

↓ **fever** [2][4]

↓ **embolic phenomenon** (stroke, emboli) [4]

↓ Aortic regurg [4]

Modified Duke (2000)

Major:

- BCx w/ typical pathogen
- Echo showing valvular vegetation

Minor:

- Predisposition
- IVDU
- **Fever**
- **Embolic phenomena**
- Immunologic phenomena
- BCx not meeting major criteria

TAVR endocarditis



Compared to SAVR endocarditis...

Lower rates of

↓ fever [2][4]

↓ embolic phenomenon (stroke, emboli) [4]

↓ **Aortic regurg** [4]

ISCVID-Duke (2023)

Major imaging:

- Echo showing valvular vegetation
- **Significant valvular regurg** that is new
- ...

Minor imaging:

- ...
- **More than mild regurg** of any etiology
- New regurg on auscultation (if no echo available)

TAVR endocarditis



Compared to SAVR endocarditis...

Lower rates of

- ↓ fever [2][4]
- ↓ embolic phenomenon (stroke, emboli) [4]
- ↓ Aortic regurg [4]

Higher rates of

- ↑ perivalvular involvement [2]
- ↑ abscesses [2]

TAVR endocarditis



Compared to SAVR endocarditis...

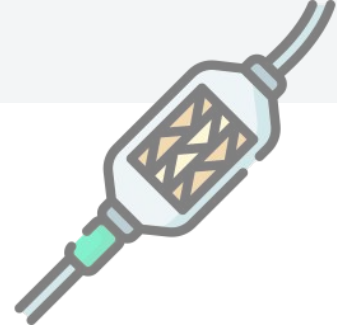Lower rates of

- ↓ fever [2][4]
- ↓ embolic phenomenon (stroke, emboli) [4]
- ↓ Aortic regurg [4]

Higher rates of

- ↑ perivalvular involvement [2]
- ↑ abscesses [2]
- ↑↑ **mortality** - In retrospective matched cohorts, **surgery did not improve** outcomes [2]

TAVR endocarditis



Compared to SAVR endocarditis...

Lower rates of

- ↓ fever [2][4]
- ↓ embolic phenomenon (stroke, emboli) [4]
- ↓ Aortic regurg [4]

Higher rates of

- ↑ perivalvular involvement [2]
- ↑ abscesses [2]

Come to journal club!
Will be discussing article #4

TAVR-IE: microbiology & timing



- Higher rates of **enterococcus** [2][4]
 - Recall, **groin access** is used...
 - Some places are investigating using **Augmentin as PPx** [2]
- Over half are healthcare associated [2], double the rate of SAVR



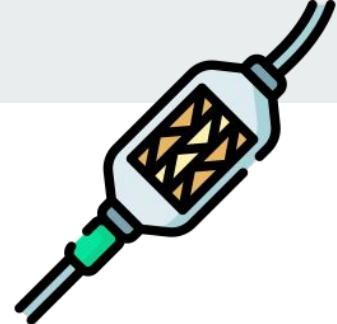TAVR-IE: microbiology & timing

- Higher rates of **enterococcus** [2][4]
 - Recall, **groin access** is used...
 - Some places are investigating using **Augmentin as PPx** [2]
- Over half are healthcare associated [2], double the rate of SAVR

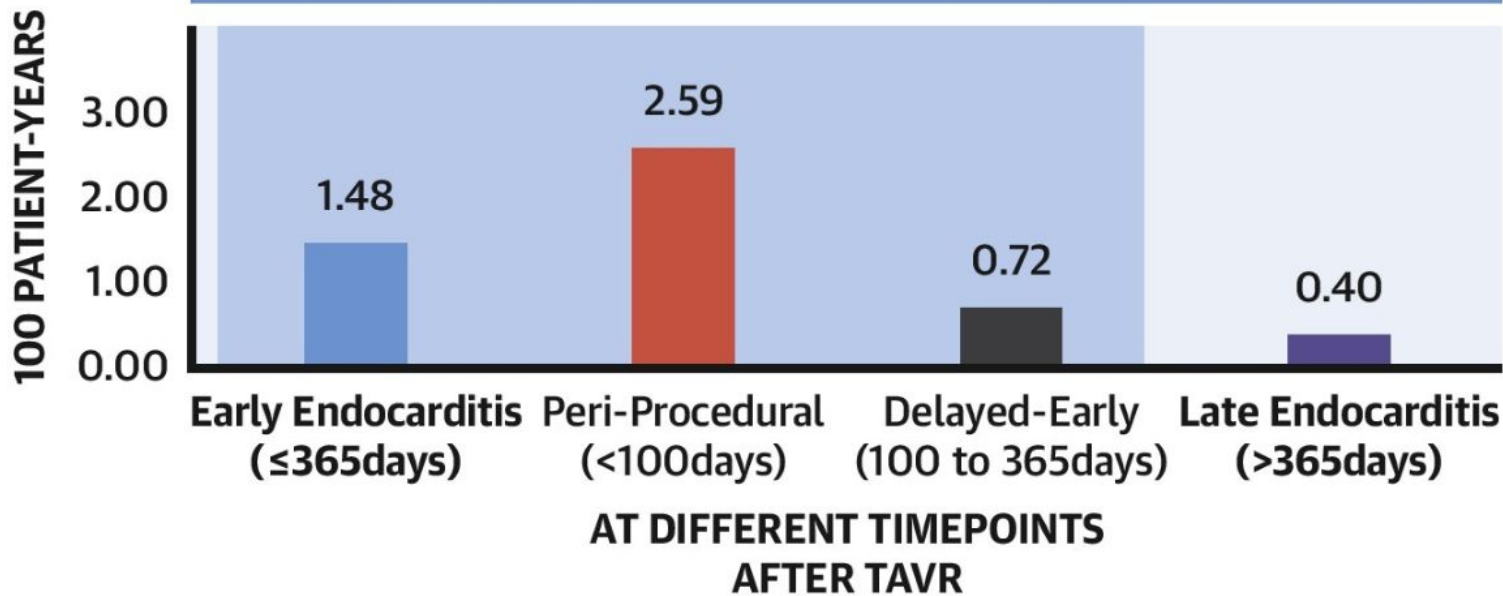
Highest risk of developing endocarditis **shortly after TAVR**

- Six-fold increase risk in the **first 100 days** [2][swiss study]

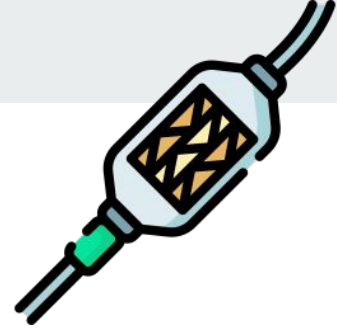TAVR-IE: microbiology & timing



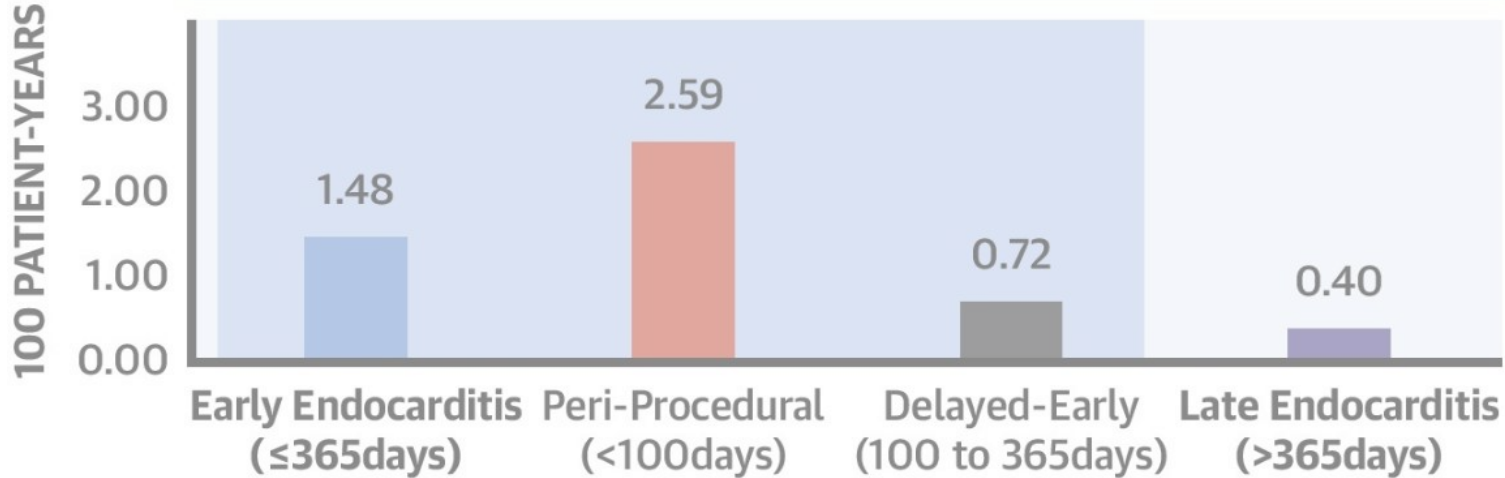
INCIDENCE RATES



TAVR-IE: microbiology & timing



INCIDENCE RATES



0

18

25

31

88

131

147

TAVR

Keflex

PPM

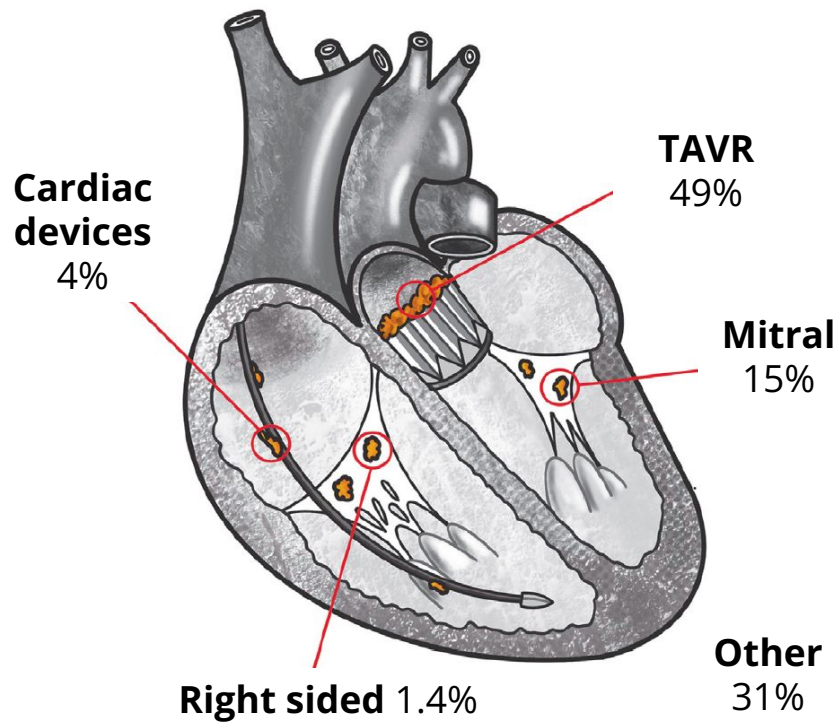
BCx

Keflex (UTI)

Keflex (UTI)

TAVR-IE: Locations [2]

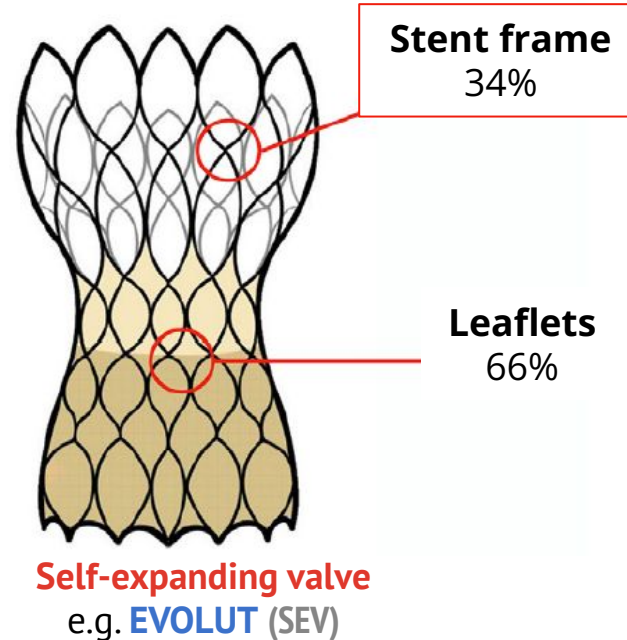
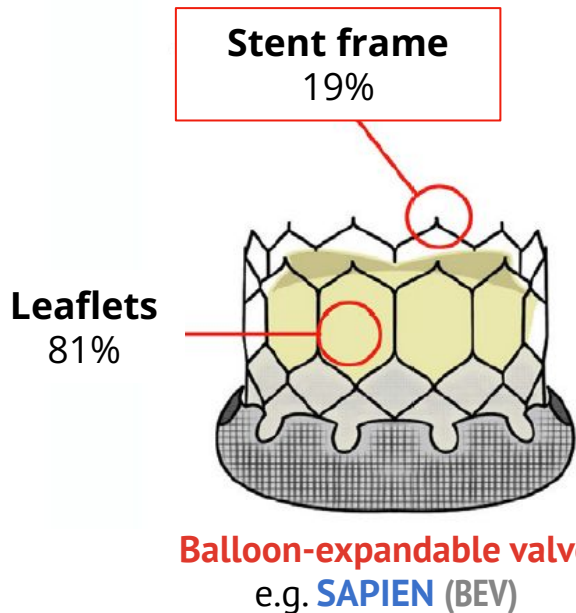
- One in three cases have **more than one** location involved

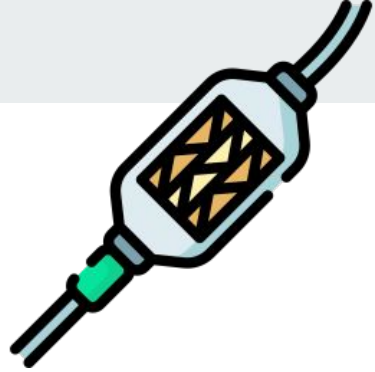

TAVR-IE: Locations [2]



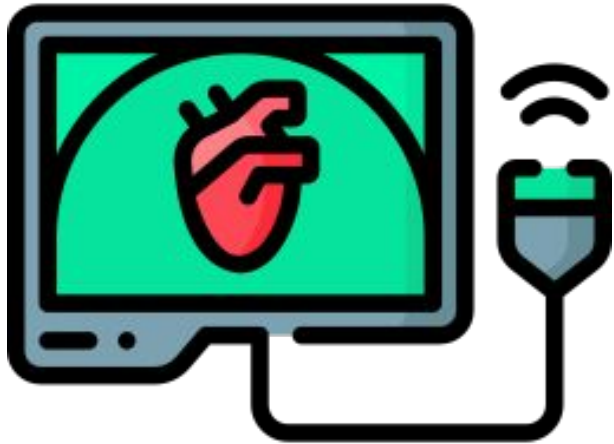
- **One in three cases** have **more than one location** involved
- Location can differ by device used

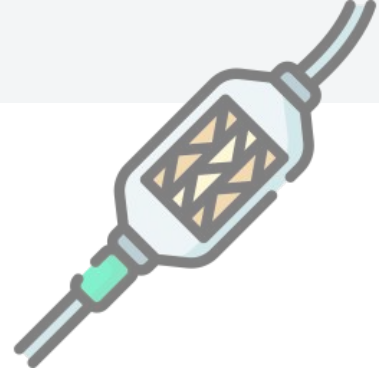



TAVR-IE: Imaging considerations [2]

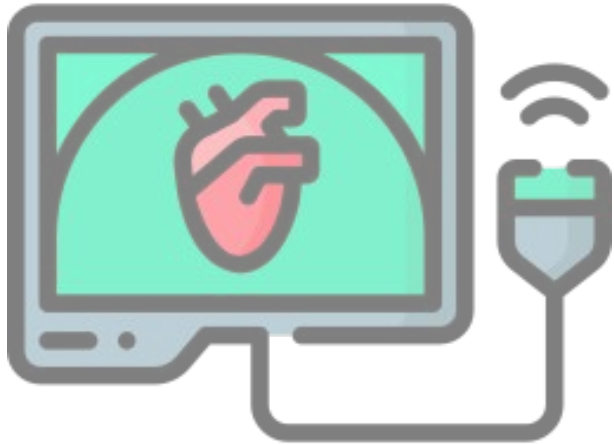
- Modified Duke is **less accurate** in PVE/TAVR
 - In large part due to **issues with echos**
- TAVR-IE frequently has “**atypical lesions**”
 - **Valve thickening** (28-70% of cases) [2][3]
 - **Obstructive patterns** [2]
 - **Increased gradients** [3]





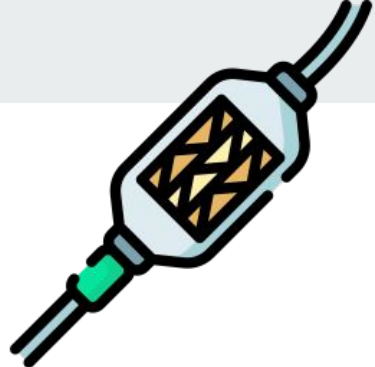TAVR-IE: Imaging considerations [2]

- Modified Duke is **less accurate** in PVE/TAVR
 - In large part due to **issues with echos**
- TAVR-IE frequently has “**atypical lesions**”
 - **Valve thickening** (28-70% of cases) [2][3]
 - **Obstructive patterns** [2]
 - **Increased gradients** [3]

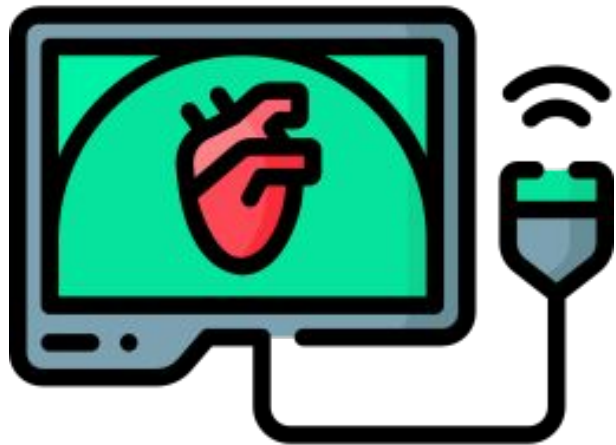


Transesophageal echo #1 (Case #1)

- No stigmata of endocarditis
- Normal functioning bioprosthetic mitral and Sapien aortic valves
- **Mild thickening** noted in the aortic cusps in the left coronary position



TAVR-IE: Imaging considerations [2]



- Modified Duke is **less accurate** in PVE/TAVR
 - In large part due to **issues with echos**
- TAVR-IE frequently has “**atypical lesions**”
 - **Valve thickening** (28-70% of cases) [2][3]
 - **Obstructive patterns** [2]
 - **Increased gradients** [3]

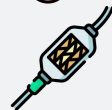Sensitivity of TTE + TEE



Native: **90%**



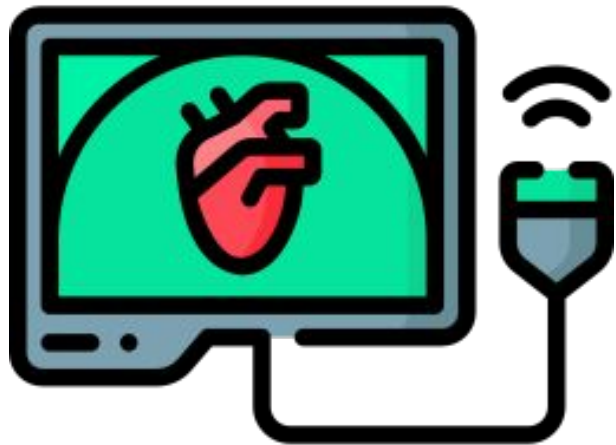
SAVR: **73%**



TAVR: **67%**



TAVR-IE: Imaging considerations [2]



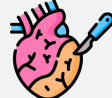Negative predictive value (TAVR)

If your **pre-test probability** of IE is $\geq 75\%$, the NPV of TTE + TEE is **47%**

Sensitivity of TTE + TEE



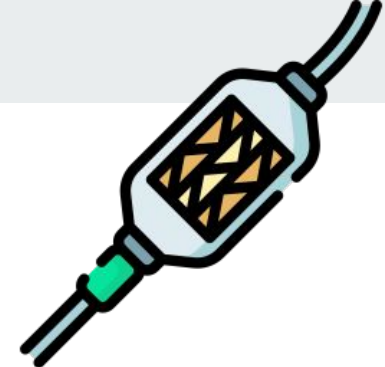Native: **90%**



SAVR: **73%**



TAVR: **67%**

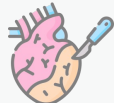

TAVR-IE: Imaging considerations [2]

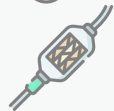Sensitivity of TTE + TEE



Native: **90%**



SAVR: **73%**



TAVR: **67%**

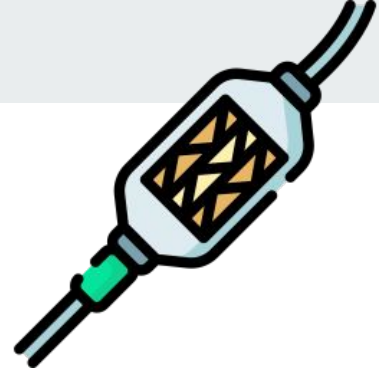Negative predictive value (TAVR)

If your **pre-test probability** of IE is $\geq 75\%$, the NPV of TTE + TEE is **47%**


		Pre-test probability			
		25%	50%	67%	75%
NPV	Native	96%	90%	81%	75%
	TAVR	89%	73%	57%	47%

Over half of negative TTE + TEE are **false negatives**





TAVR-IE: Imaging considerations




18F-FDG PET/CT may be of benefit in **PVE**, especially TAVR-IE

- **PET/CT reclassified 33%** of suspected TAVR-IE cases [2]



TAVR-IE: Imaging considerations



18F-FDG PET/CT may be of benefit in **PVE**, especially TAVR-IE

- **PET/CT reclassified 33%** of suspected TAVR-IE cases [2]

In another study, using the 2023-ISCVID criteria (compared to modified Duke) [3]

- Significantly **increased sensitivity** 65% → 76%
- Without significantly decreasing specificity
- Largely by **adding a positive major criteria for PET/CT**



Cardiac PET/CT: Practical considerations



- Differentiate the presentation of **endocarditis in TAVR compared to SAVR**, including
 - Clinical manifestations
 - Microbiology
 - Echo findings (and why it may be a **good idea to get a PET/CT**)
- Review the use of **PET/CT for endocarditis**, including
 - **Practical considerations** including **patient prep** and what **radiology is looking at**
 - **Indications for PET/CT** with a focus on **endocarditis** as well as other indications listed in the 2024 guidelines (**CIED & LVAD**)
- Appraise the very limited data on **serial PET/CTs** in the **long term monitoring** of endovascular infections



I thought we couldn't do PET scans?

PET has **been around for awhile**, but hasn't been used much for infectious processes (until recently)

There was an **old CMS rule** (national coverage decision) that made 18F-FDG PET scans **ineligible** to be used for **inflammation / inflammatory processes** [1]



I thought we couldn't do PET scans?

PET has **been around for awhile**, but hasn't been used much for infectious processes (until recently)

There was an **old CMS rule** (national coverage decision) that made 18F-FDG PET scans **ineligible** to be used for **inflammation / inflammatory processes** [1]

Explained to me by AI... [citation needed]

- Couldn't bill CMS (or patients) for PET, so this was an expensive test for the hospital foot the bill for
 - SPECT wasn't covered under this rule
- CMS **retired the noncoverage rule in 2021** [5] (thank you cardiology & sarcoidosis)
 - Now it is treated more like SPECT



I thought we couldn't do PET scans?

PET has **been around for awhile**, but hasn't been used much for infectious processes (until recently)

There was an **old CMS rule** (national coverage decision) that made 18F-FDG PET scans **ineligible** to be used for **inflammation / inflammatory processes** [1]

Explained to me by AI... [citation needed]

- Couldn't bill CMS (or patients) for PET, so this was an expensive test for the hospital foot the bill for
 - SPECT wasn't covered under this rule
- CMS **retired the noncoverage rule in 2021** [5] (thank you cardiology & sarcoidosis)
 - Now it is treated more like SPECT

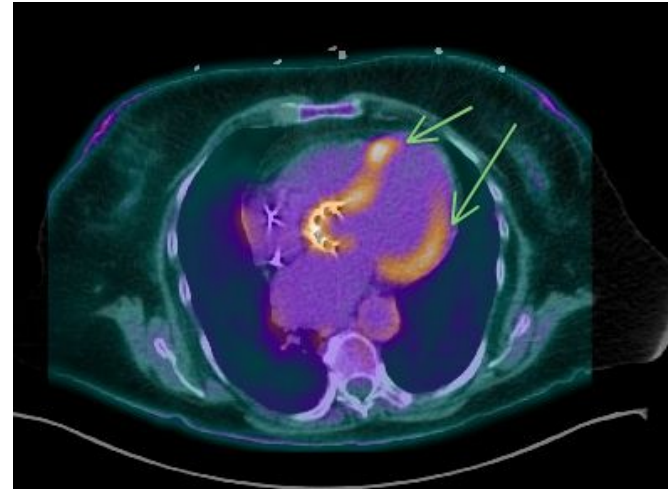
Still needs to meet **appropriate use criteria** (selected by local Medicare administrative contractors [1])



Cardiac PET/CT (for PVE)

Patient prep: [1][3]

- **Ketogenic diet** (low carbs, high fat) for 24h before the scan → **fasting** 12h before
- Reduces **physiologic myocardial glucose uptake**



Non-specific LV wall uptake (arrows)



Cardiac PET/CT (for PVE)

Patient prep: [1][3]

- **Ketogenic diet** (low carbs, high fat) for 24h before the scan → **fasting** 12h before
- Reduces **physiologic myocardial glucose uptake**

False positives:

- Some **surgical bioadhesives** cause FDG uptake [1]
- Earlier data suggested **sterile inflammation** can occur during **first 3 months**, but others report this is **less of an issue for TAVRs** [2]



Cardiac PET/CT (for PVE)

Patient prep: [1][3]

- **Ketogenic diet** (low carbs, high fat) for 24h before the scan → **fasting** 12h before
- Reduces **physiologic myocardial glucose uptake**

False positives:

- Some **surgical bioadhesives** cause FDG uptake [1]
- Earlier data suggested **sterile inflammation** can occur during **first 3 months**, but others report this is **less of an issue for TAVRs** [2]

False negatives:

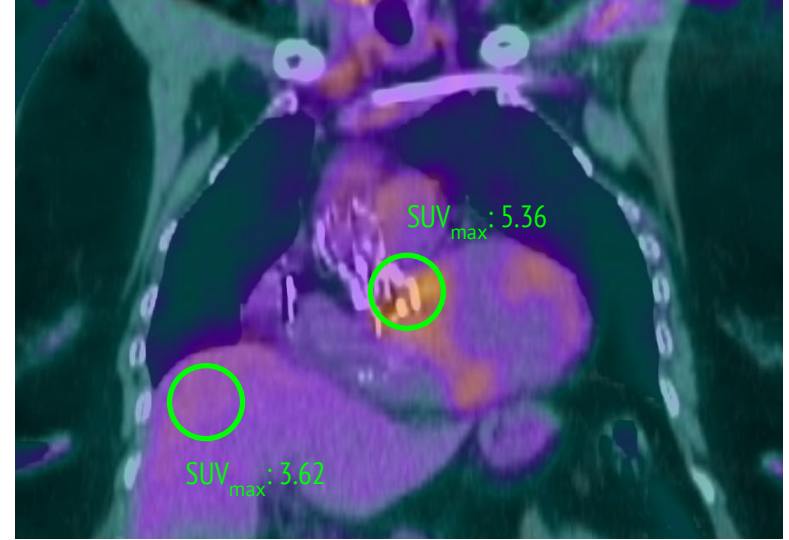
- PET/CT is less likely to be positive if patient has **been on antibiotics** for longer
- Generally better to get the test earlier



What do the look at?

Pattern of uptake: **Focal / heterogeneous** (e.g. not involving the whole valve) more suggestive of IE than **diffuse / homogenous** uptake

Relative intensity: Comparing uptake to a **reference point** (like the liver)





What do the look at?

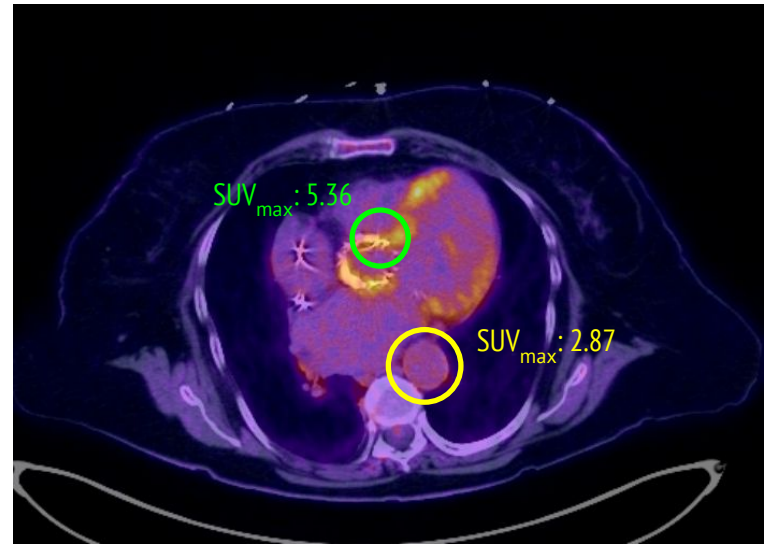
Pattern of uptake: **Focal / heterogeneous** (e.g. not involving the whole valve) more suggestive of IE than **diffuse / homogenous** uptake

Relative intensity: Comparing uptake to a **reference point** (like the liver)

Formulas:

- **SUVmax ratio**: $\text{SUV max} / \text{SUV aorta}$
- **Value uptake index**: It's complicated

Delayed images, non-attenuation images, etc





What do the look at?

Pattern of uptake: **Focal / heterogeneous** (e.g. not involving the whole valve) more suggestive of IE than **diffuse / homogenous** uptake

Relative intensity: Comparing uptake to a **reference point** (like the liver)

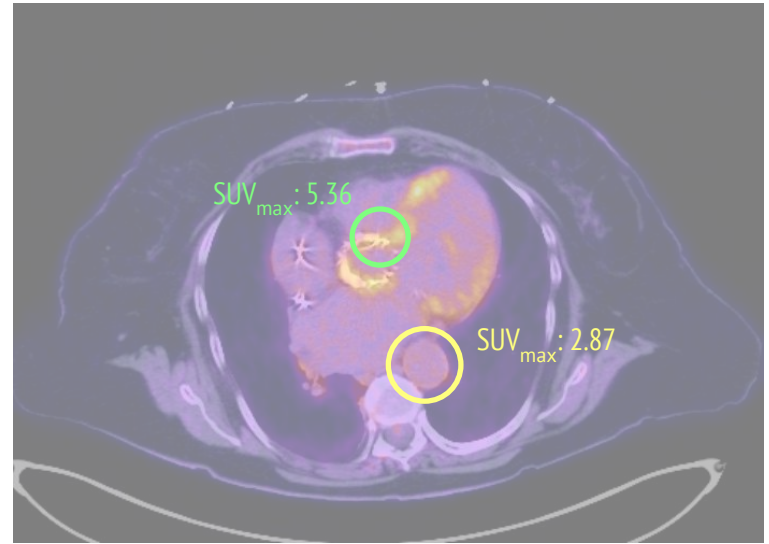
Formulas:

- **SUVmax ratio:** SUV_{max} / SUV_{aorta}
- **Value uptake index:** It's complicated

Delayed images, non-attenuation images, etc

Key takeaway

It's much **more complicated** than "lights up on PET"





Cardiac PET/CT: When to use



- Differentiate the presentation of **endocarditis** in **TAVR** compared to **SAVR** , including
 - **Clinical manifestations**
 - **Microbiology**
 - **Echo findings** (and why it may be a **good idea to get a PET/CT**)
- Review the use of **PET/CT for endocarditis**, including
 - **Practical considerations** including **patient prep** and what **radiology is looking at**
 - **Indications for PET/CT** with a focus on **endocarditis** as well as other indications listed in the 2024 guidelines (**CIED & LVAD**)
- Appraise the very limited data on **serial PET/CTs** in the **long term monitoring** of endovascular infections

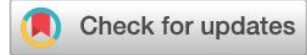HeartRhythm

The Official Journal of the Heart Rhythm Society, The Cardiac Electrophysiology Society,
and The Pediatric & Congenital Electrophysiology Society



Heart
Rhythm
SocietySM

News From the Heart Rhythm Society



^{18}F -FDG PET/CT and radiolabeled leukocyte SPECT/CT imaging for the evaluation of cardiovascular infection in the multimodality context

ASNC Imaging Indications (ASNC I²) Series Expert Consensus Recommendations from ASNC, AATS, ACC, AHA, ASE, EANM, HRS, **IDSA**, SCCT, SNMMI, and STS

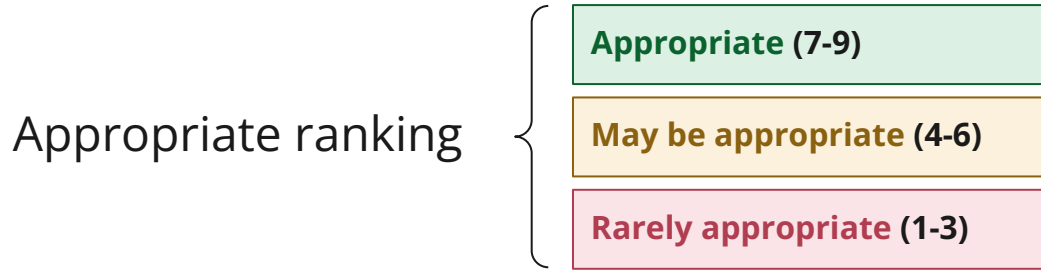
PET/CT-IE: Diagnostic parameters [1]

Prosthetic valve	Studies (n patients)	Sensitivity	Specificity
Wang 2020	15 (n = 967)	86%	84%
Mahmood 2019	8 (n = 227)	80%	73%
Swart 2018	1 (n = 237)	74%	91%
Gomes 2017	8	73 - 100%	71 - 100%

PET/CT-IE: Diagnostic parameters [1]

Prosthetic valve	Studies (n patients)	Sensitivity	Specificity	Native valve	Studies (n patients)	Sensitivity	Specificity
Wang 2020	15 (n = 967)	86%	84%	Wang 2020	4 (n = 385)	31%	98%
Mahmood 2019	8 (n = 227)	80%	73%	Albano 2021	12 (n = 600)	31%	82%
Swart 2018	1 (n = 237)	74%	91%	Kamani 2020	7 (n = 351)	36%	99%
Gomes 2017	8	73 - 100%	71 - 100%	Gomes 2017	7	14%	---

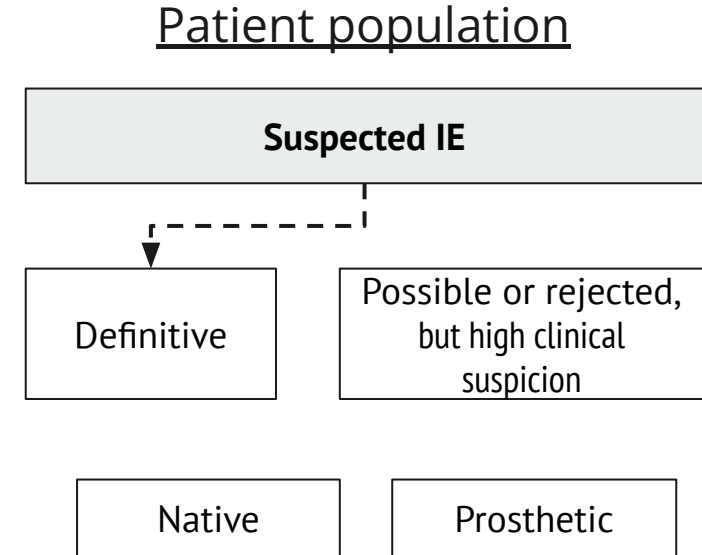
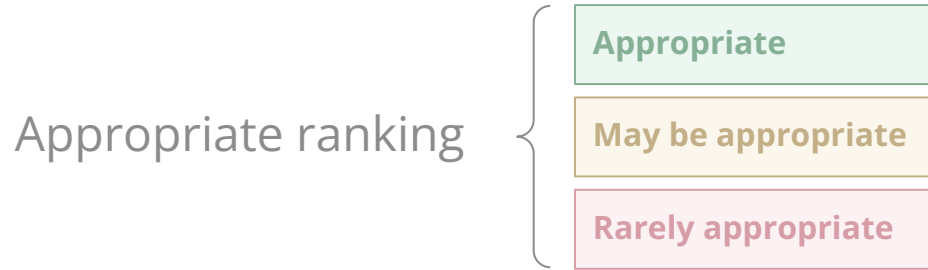PET/CT-IE: Appropriate utilization [1]



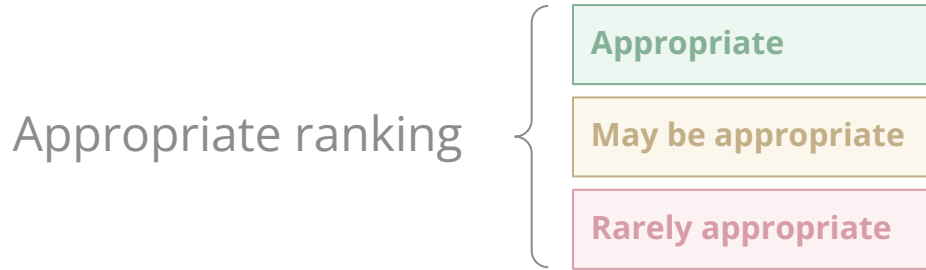
Ranking:

- Linear scale from 1-9 by multidisciplinary team
- Does **not** explicitly **consider cost**
- Assumes **whole body PET/CT** (vertex to thigh)

PET/CT-IE: Appropriate utilization [1]

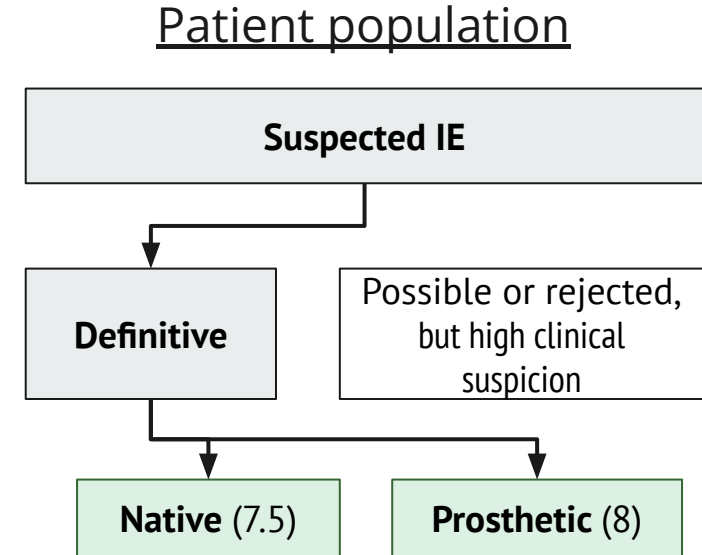


PET/CT-IE: Appropriate utilization [1]

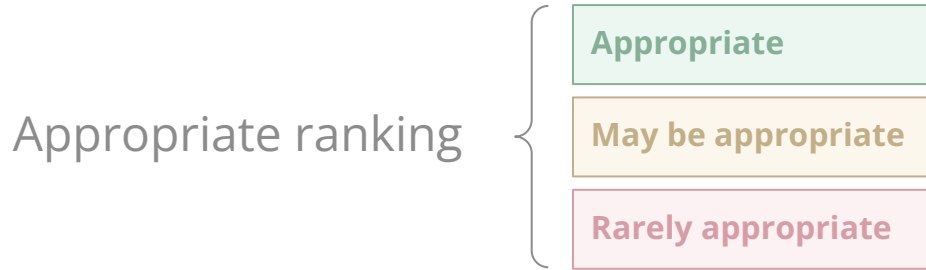


Definitive IE:

- Both: **Detection of infectious source** / focus in presence of hardware or persistent bacteremia

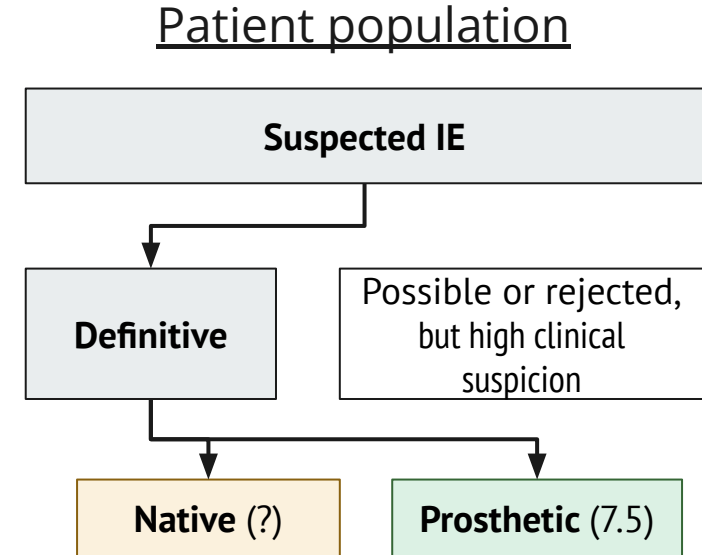


PET/CT-IE: Appropriate utilization [1]



Definitive IE:

- Both: **Detection of infectious source** / focus in presence of hardware or persistent bacteremia
- PVE: **Left sided embolic** event

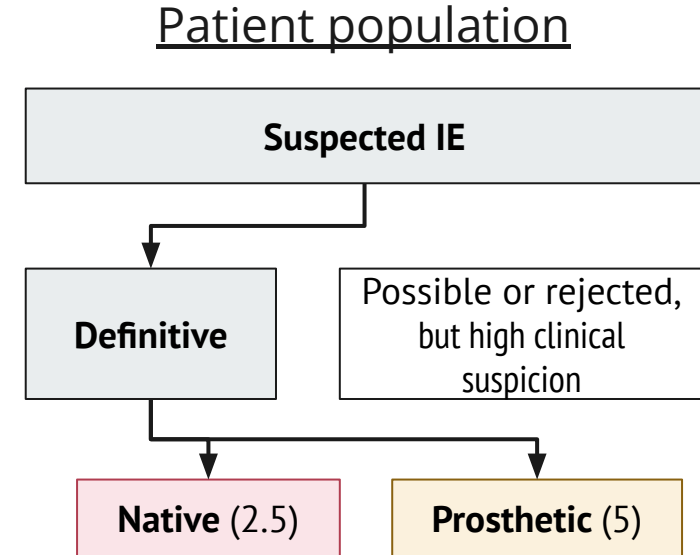


PET/CT-IE: Appropriate utilization [1]



Definitive IE:

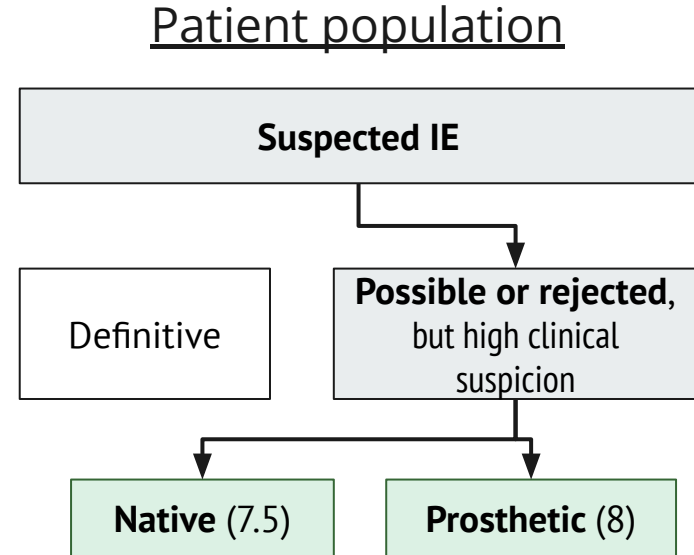
- Both: **Detection of infectious source** / focus in presence of hardware or persistent bacteremia
- PVE: **Left sided embolic** event
- PVE: **Monitoring of therapy**



PET/CT-IE: Appropriate utilization [1]

Possible or rejected IE with *high clinical suspicion*:

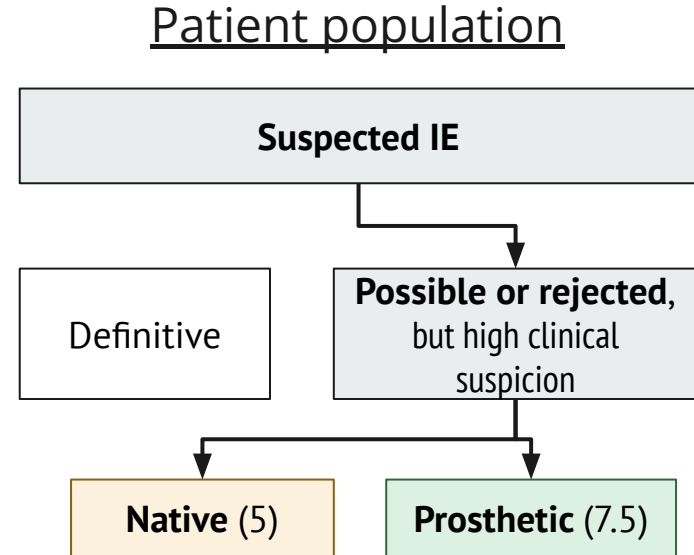
- Both: **Gram positive bacteremia** (of any type)



PET/CT-IE: Appropriate utilization [1]

Possible or rejected IE with *high clinical suspicion*:

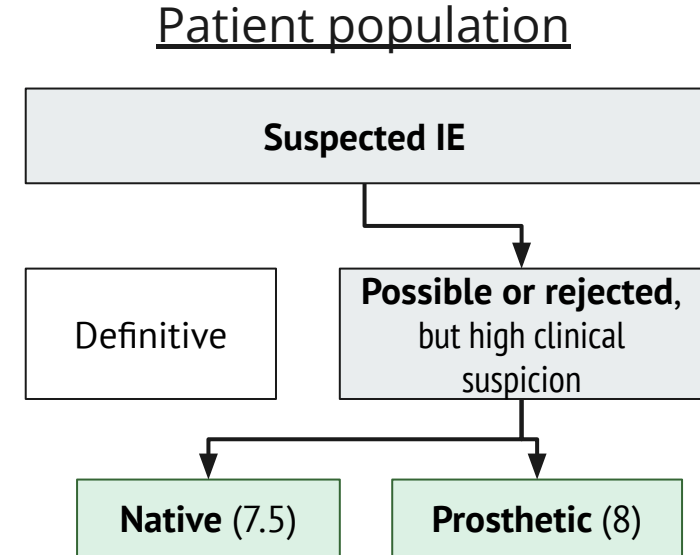
- Both: **Gram positive bacteremia** (of any type)
- **Fungemia or gram negative** with negative echo
 - **PVE**: Appropriate
 - **NVE**: May be appropriate



PET/CT-IE: Appropriate utilization [1]

Possible or rejected IE with *high clinical suspicion*:

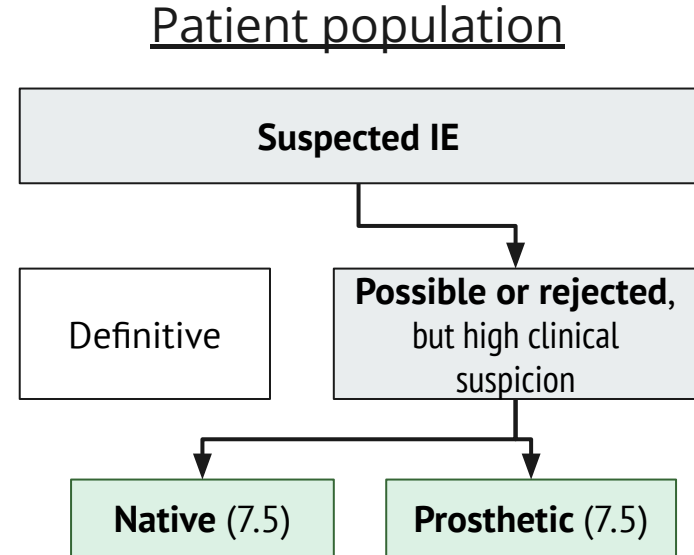
- Both: **Gram positive bacteremia** (of any type)
- **Fungemia or gram negative** with negative echo
 - **PVE**: Appropriate
 - **NVE**: May be appropriate
- Both: **inconclusive echo** or discrepant findings



PET/CT-IE: Appropriate utilization [1]

Possible or rejected IE with *high clinical suspicion*:

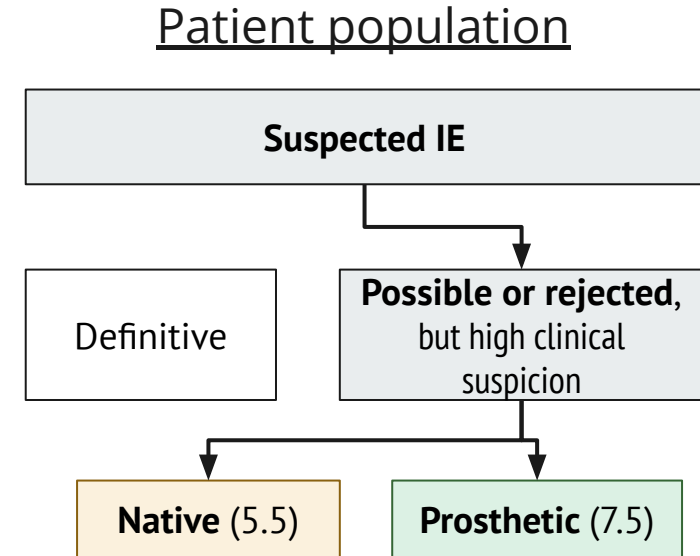
- Both: **Gram positive bacteremia** (of any type)
- **Fungemia or gram negative** with negative echo
 - **PVE**: Appropriate
 - **NVE**: May be appropriate
- Both: **inconclusive echo** or discrepant findings
- Both: **Mobile mass on echo** with negative BCx/serologies



PET/CT-IE: Appropriate utilization [1]

Possible or rejected IE with *high clinical suspicion*:

- Both: **Gram positive bacteremia** (of any type)
- **Fungemia or gram negative** with negative echo
 - **PVE**: Appropriate
 - **NVE**: May be appropriate
- Both: **inconclusive echo** or discrepant findings
- Both: **Mobile mass on echo** with negative BCx/serologies
- **Persistent bacteremia or fungemia**
 - **PVE**: Appropriate
 - **NVE**: May be appropriate

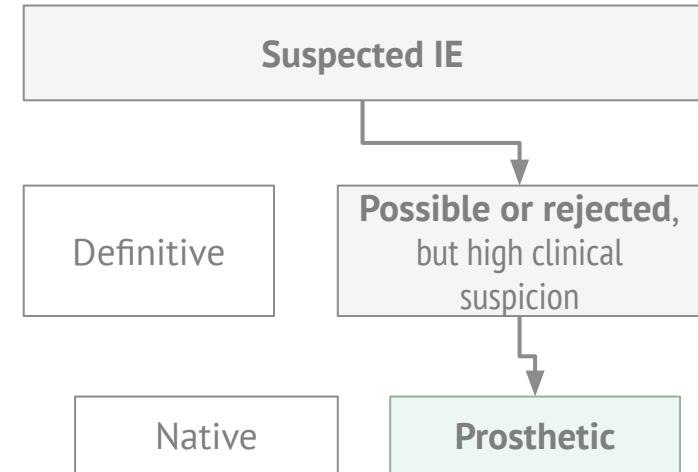


PET/CT-IE: Appropriate utilization [1]

Broader takeaway

In **suspected** prosthetic valve endocarditis (that has not been classified as definitive), **PET/CT is always appropriate** per ASNC I2 guidelines

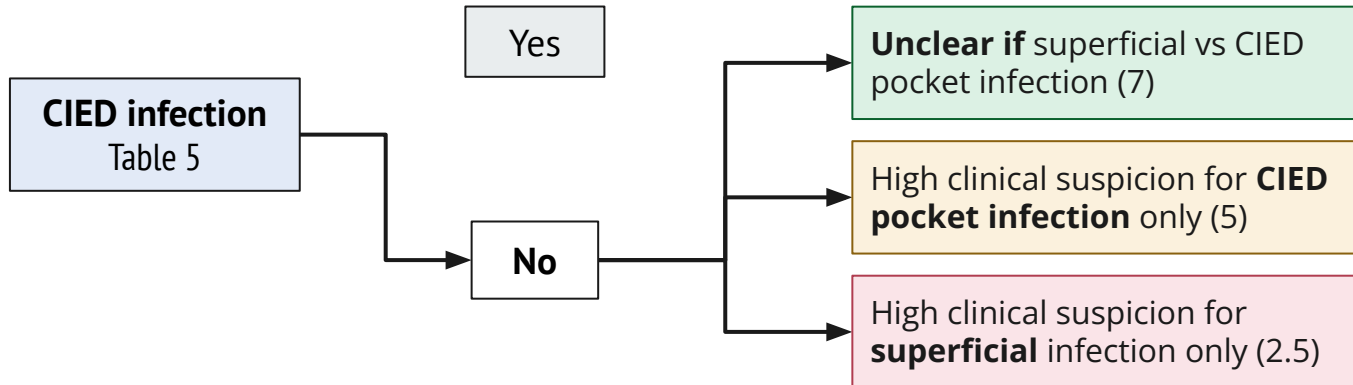
Patient population



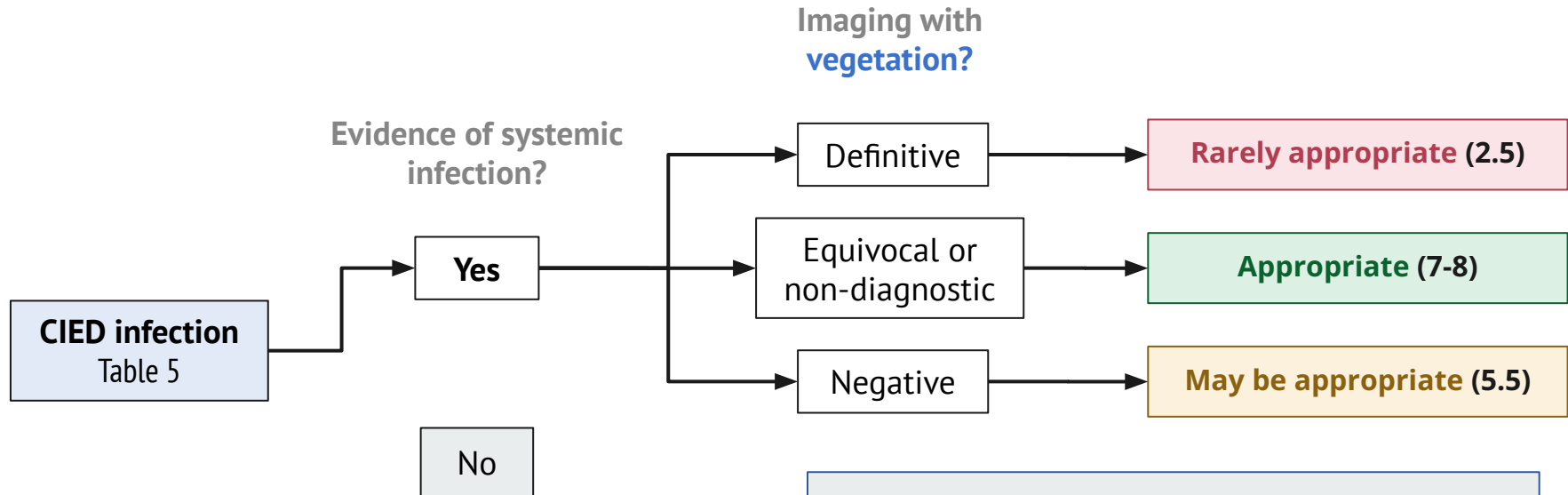
PET/CT: Other situations [1]

Evidence of **systemic**
infection?

Pocket infection?



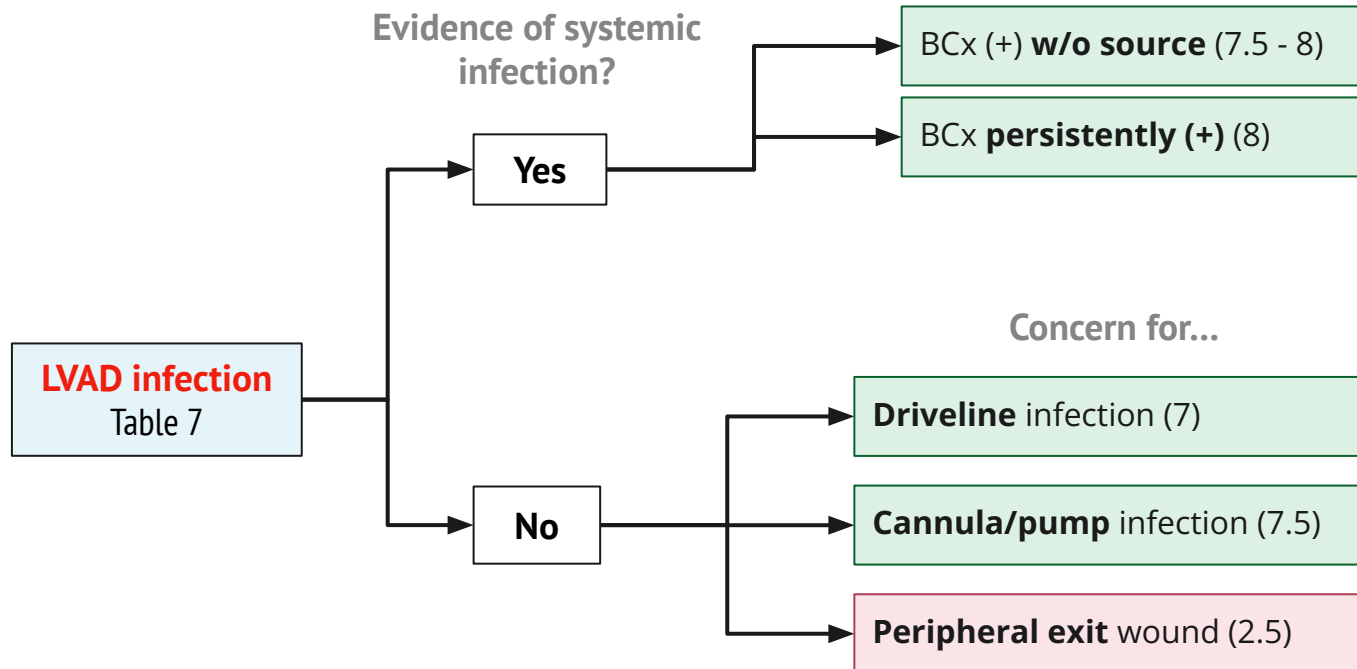
PET/CT: Other situations [1]



Note


Works better for pocket infection than lead infection; cannot use to rule out lead infection

PET/CT: Other situations [1]





Predicting the future?



- Differentiate the presentation of **endocarditis in TAVR compared to SAVR** , including
 - **Clinical manifestations**
 - **Microbiology**
 - **Echo findings** (and why it may be a **good idea to get a PET/CT**)
- Review the use of **PET/CT for endocarditis**, including
 - **Practical considerations** including **patient prep** and what **radiology is looking at**
 - **Indications for PET/CT** with a focus on **endocarditis** as well as other indications listed in the 2024 guidelines (**CIED & LVAD**)
- Appraise the very limited data on **serial PET/CTs** in **the long term monitoring** of endovascular infections



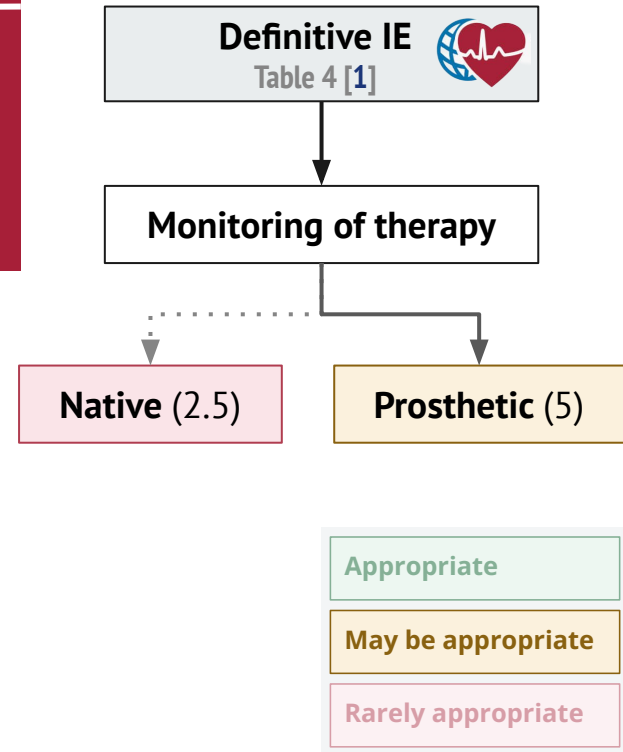
HeartRhythm


¹⁸F-FDG PET/CT and radiolabeled leukocyte SPECT/CT imaging for the evaluation of cardiovascular infection in the multimodality context

ASNC Imaging Indications (ASNC I2) Series Expert Consensus Recommendations from ASNC, AATS, ACC, AHA, ASE, EANM, HRS, IDSA, SCCT, SNMMI, and STS

In the setting of persistent bacteremia in patients with PVE and/or the presence of other prosthetic material, ¹⁸F-FDG PET/CT and radiolabeled leukocyte SPECT/CT are recommended, as they can be useful detecting extracardiac foci of infection or identifying other portals of entry.

Preliminary data suggest ¹⁸F-FDG PET/CT and radiolabeled leukocyte SPECT/CT may be useful in **monitoring cases of PVE that are medically managed with antimicrobial treatment**, but further studies are needed to inform the frequency and reliability of **monitoring strategies**. The role of these advanced modalities in assessment of suspected embolic events in both NVE and PVE is not fully elucidated but is recommended by the ESC guidelines workflow ²⁴






VASGRA study [8]

Prospective cohort study (from one Swiss hospital) of **aortic vascular graft infections**

- Adults (**n=68**) with aortic vascular graft infections (AGI)



68 patients / grafts



VASGRA study [8]

Prospective cohort study (from one Swiss hospital) of **aortic vascular graft infections**

- Adults (**n=68**) with aortic vascular graft infections (AGI)
- Diagnosis established in **multidisciplinary meeting** (ID, surgery, radiology, nuc med, micro)



68 patients / grafts



VASGRA study [8]

Prospective cohort study (from one Swiss hospital) of **aortic vascular graft infections**

- Adults (**n=68**) with aortic vascular graft infections (AGI)
- Diagnosis established in **multidisciplinary meeting** (ID, surgery, radiology, nuc med, micro)



68 patients / grafts



266 PET/CT

Patients had consecutive* PET/CTs



VASGRA study [8]

Prospective cohort study (from one Swiss hospital) of **aortic vascular graft infections**

- Adults (**n=68**) with aortic vascular graft infections (AGI)
- Diagnosis established in **multidisciplinary meeting** (ID, surgery, radiology, nuc med, micro)



68 patients / grafts



266 PET/CT

Patients had consecutive* PET/CTs

- Baseline scan
- PET/CTs while on treatment
- Scan at end of treatment
- Control PET/CT (3 months after Tx)

Median 5 scans per patient
(IQR 3-6)

* Not everyone had baseline/control scans for various reasons



Let's look at their cases

VASGRA: Case 1 [8]



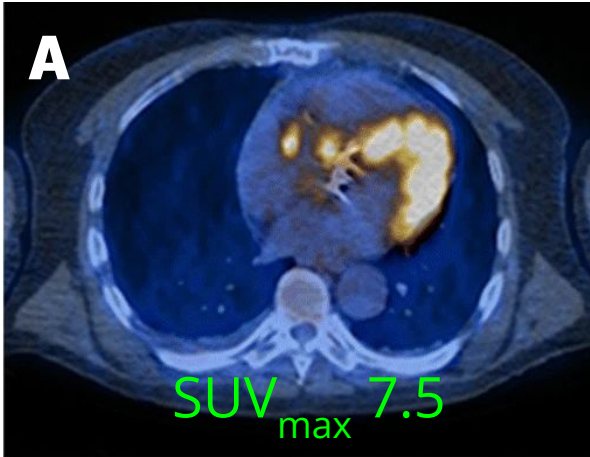
53 year old develops *Pasteurella multocida* infection of polyester composite vascular graft (Aortic Valved Graft ATS)



VASGRA: Case 1 [8]

53 year old develops *Pasteurella multocida* infection of polyester composite vascular graft (Aortic Valved Graft ATS)

A) Initial scan (SUV_{max} 7.5)



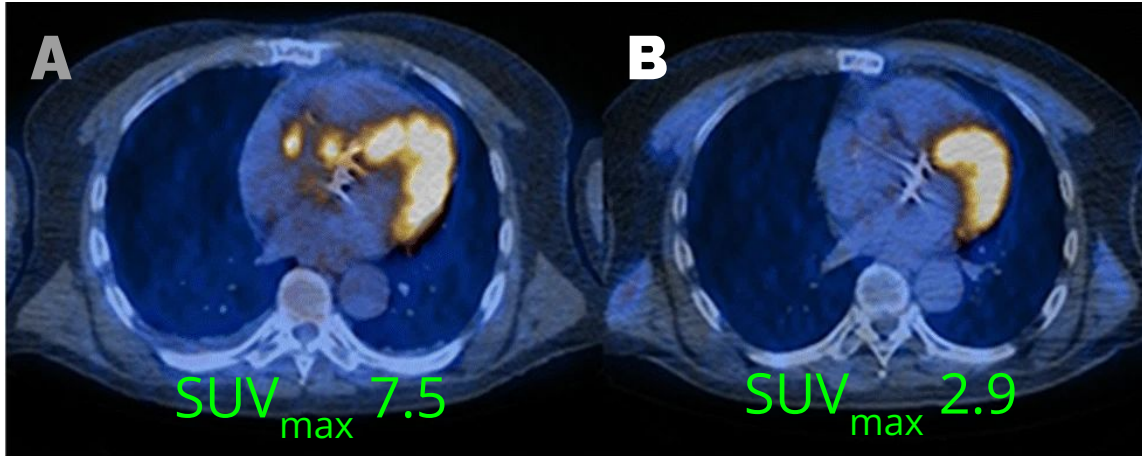


VASGRA: Case 1 [8]

53 year old develops *Pasteurella multocida* infection of polyester composite vascular graft (Aortic Valved Graft ATS)

A) Initial scan (SUV_{max} 7.5)

B) Complete response 3 months later (SUV_{max} 2.9)





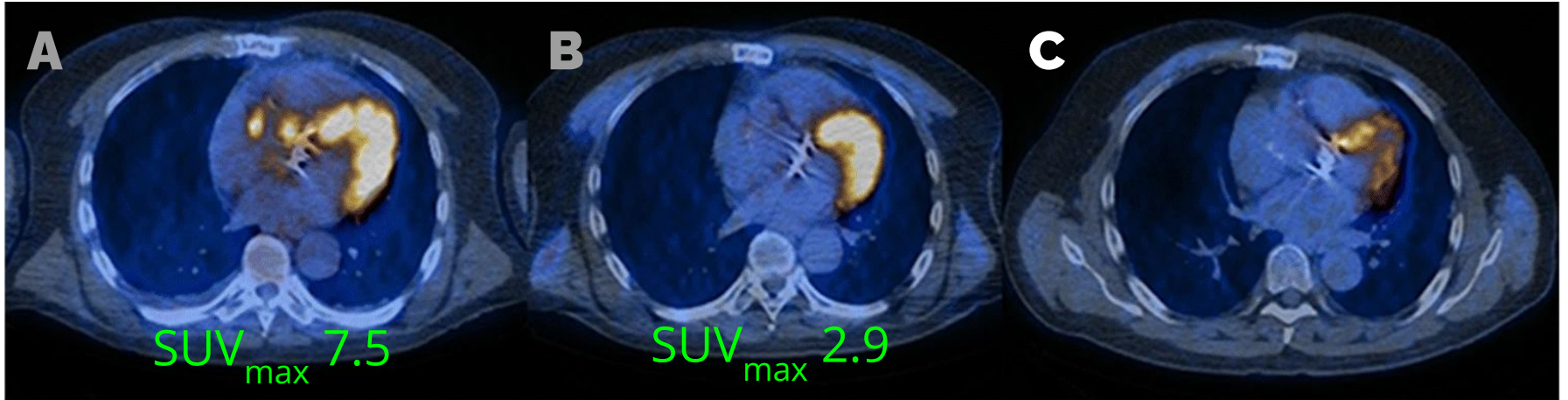
VASGRA: Case 1 [8]

53 year old develops *Pasteurella multocida* infection of polyester composite vascular graft (Aortic Valved Graft ATS)

A) Initial scan (SUV_{max} 7.5)

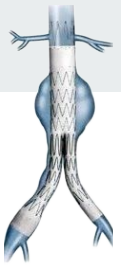B) Complete response 3 months later (SUV_{max} 2.9)

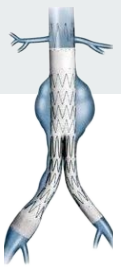C) Scan 6 months after stopping antibiotics; still good



VASGRA: Case 2 [8]

71M developed Coagulase negative Staphylococci infection of endovascular abdominal aneurysm repair

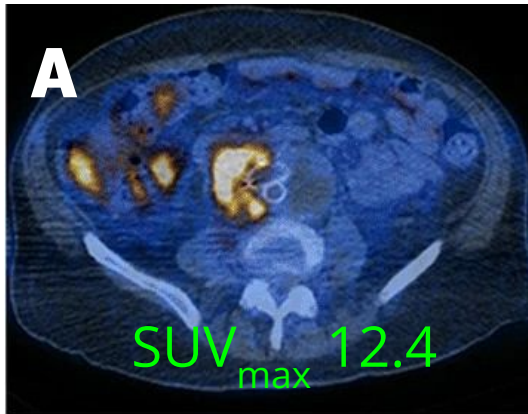




VASGRA: Case 2 [8]

71M developed Coagulase negative Staphylococci infection of endovascular abdominal aneurysm repair

A) Initial scan (SUV_{max} 12.4)





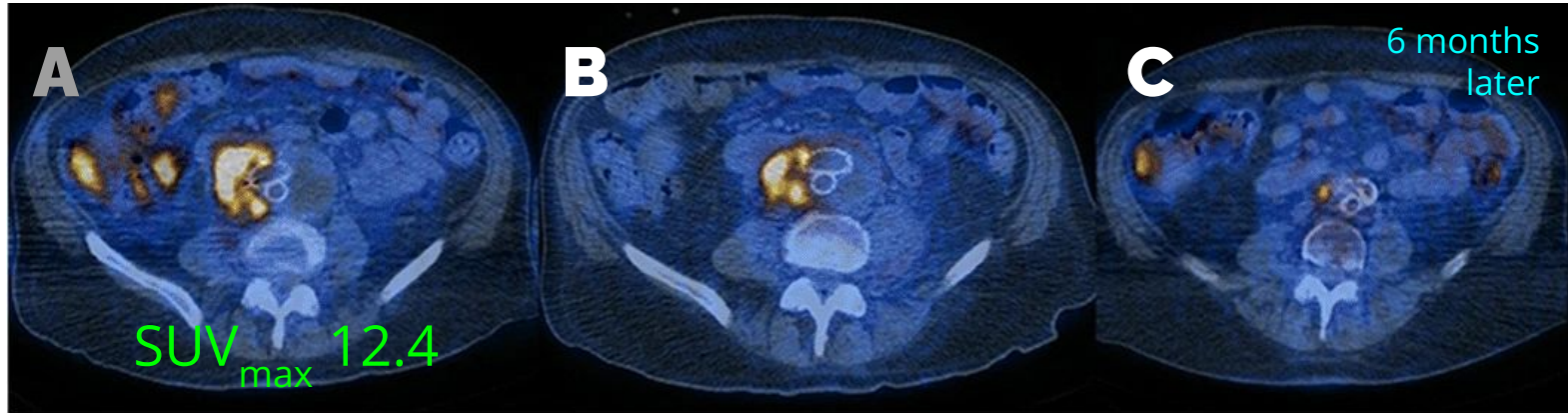
VASGRA: Case 2 [8]

71M developed Coagulase negative Staphylococci infection of endovascular abdominal aneurysm repair

A) Initial scan (SUV_{max} 12.4)

B) On antibiotics

C) Six months later (still on antibiotics)

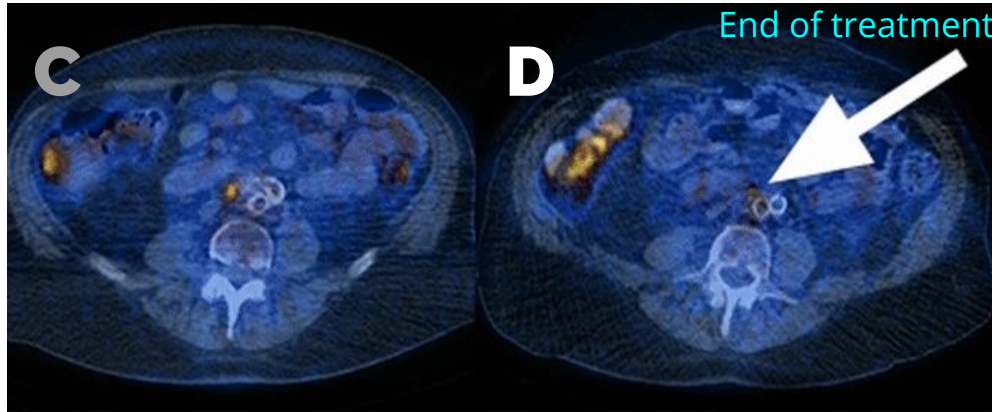
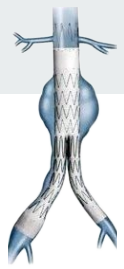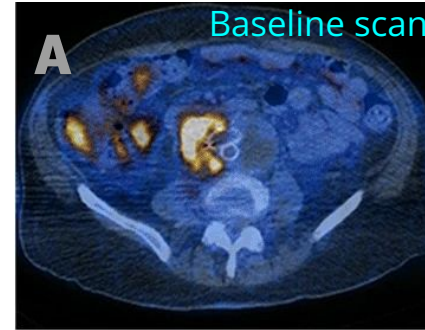


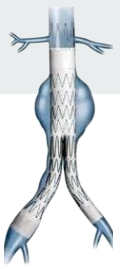VASGRA: Case 2 [8]

71M developed CONS infection of endovascular abdominal aneurysm repair

C) On >6 months of antibiotics

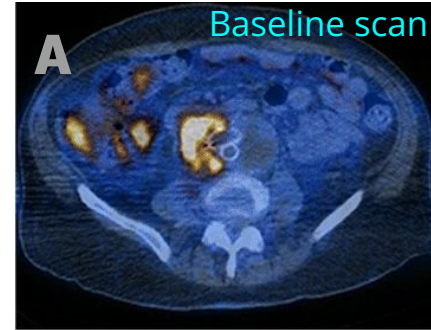
D) Only faint FDG uptake (arrow), so **stopped suppression** after >1 year of abx



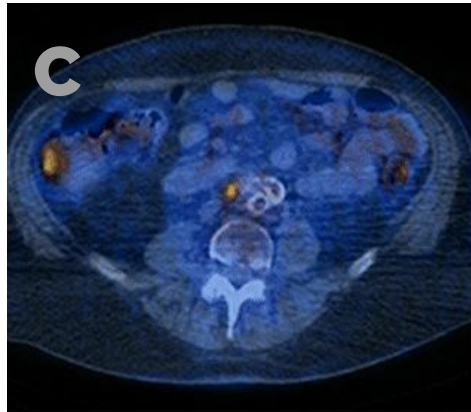


VASGRA: Case 2 [8]

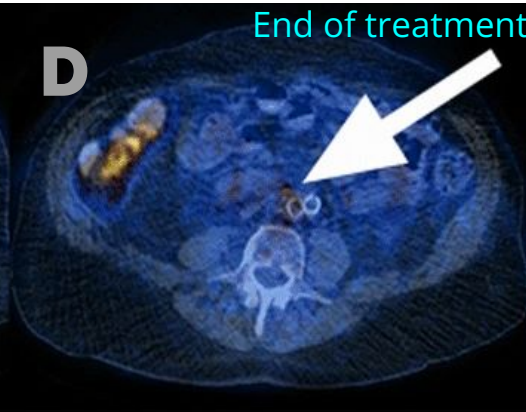
71M developed CONS infection of endovascular abdominal aneurysm repair



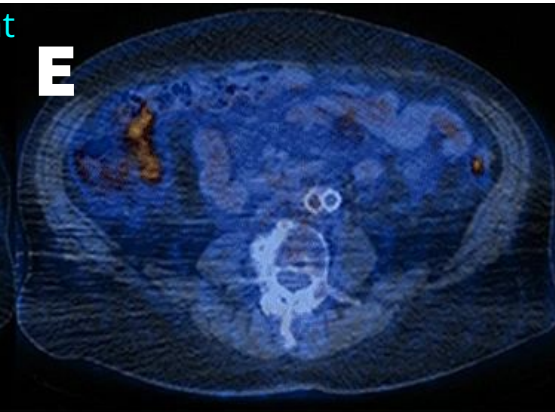
C) On >6 months of antibiotics



D) Only faint FDG uptake (arrow), so **stopped suppression** after >1 year of abx

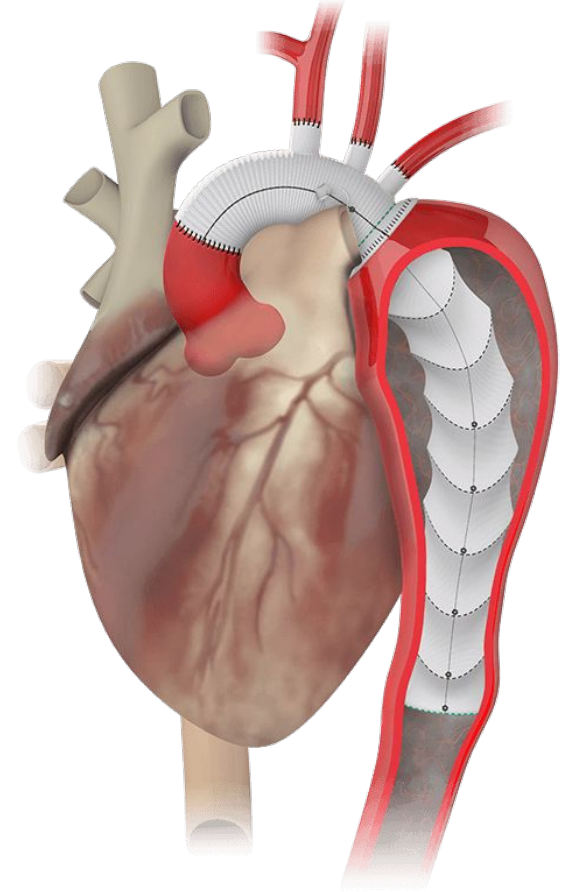
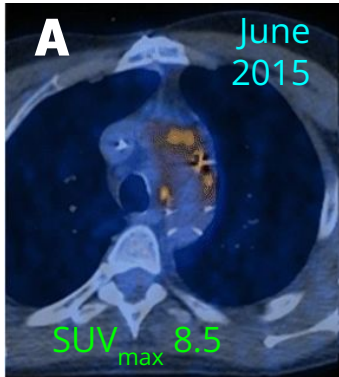


E) No uptake (3 months after stopping abx)



VASGRA: Case 3 [8]

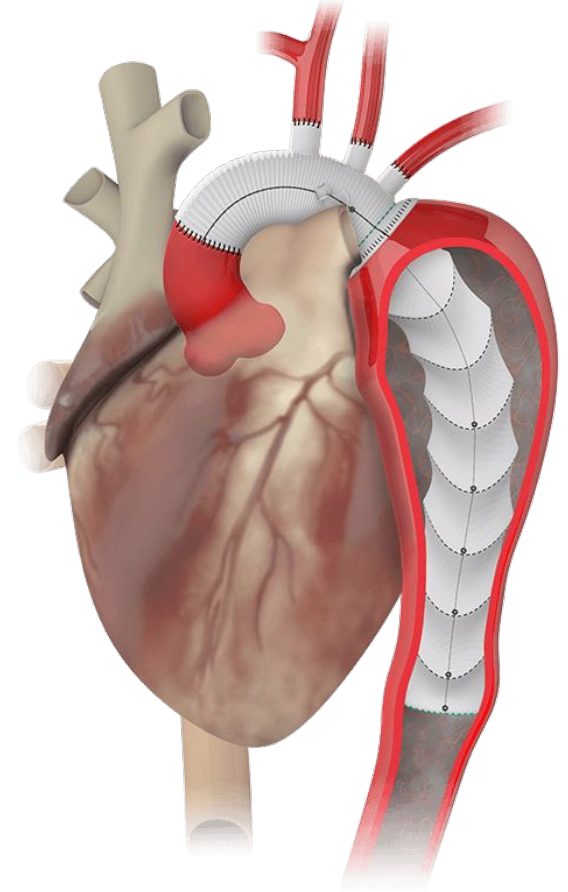
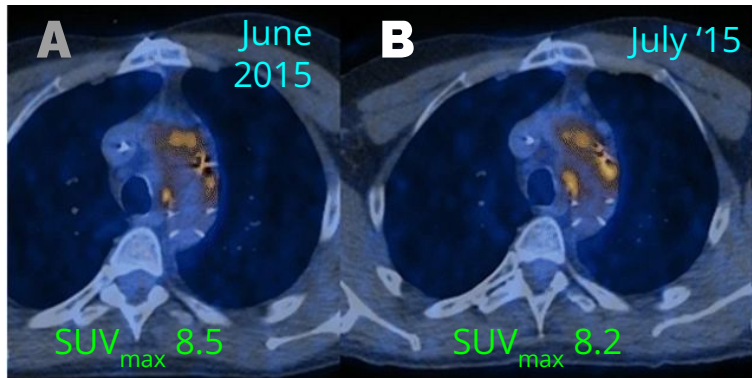
48M developed ascending aortic graft infection with *strep constellatus* & *Aggregatibacter aphrophilus*.

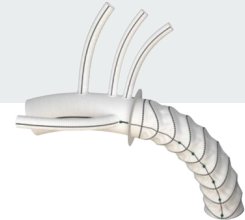


VASGRA: Case 3 [8]

48M developed ascending aortic graft infection with *strep constellatus* & *Aggregatibacter aphrophilus*.

Surgery not feasible, so **treated with levofloxacin** (starting in July '15)





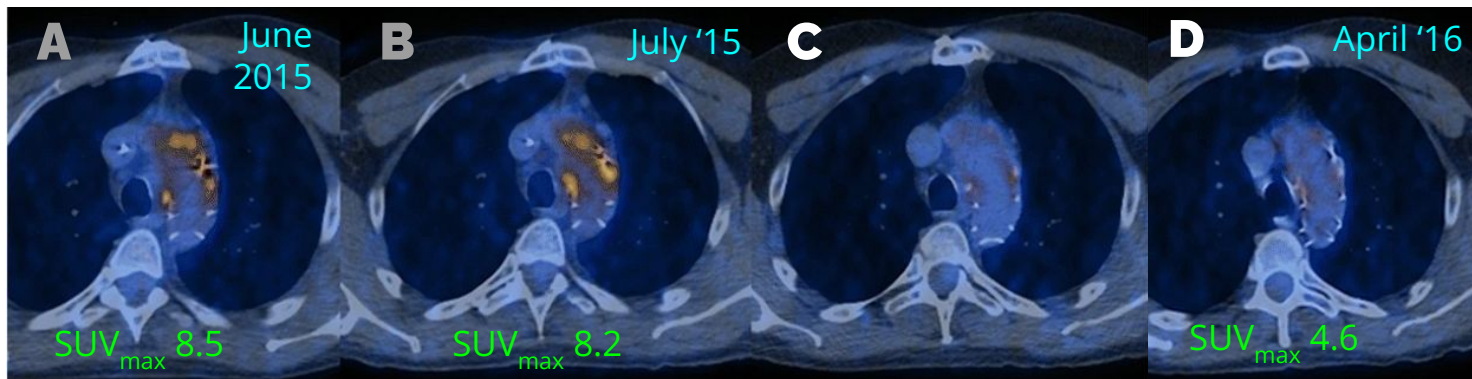
VASGRA: Case 3 [8]

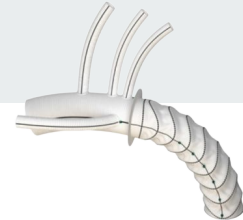
48M developed ascending aortic graft infection with *strep constellatus* & *Aggregatibacter aphrophilus*.

A) Baseline

B) Started levaquin

C & D) Improvement of SUV over ~1 year





VASGRA: Case 3 [8]

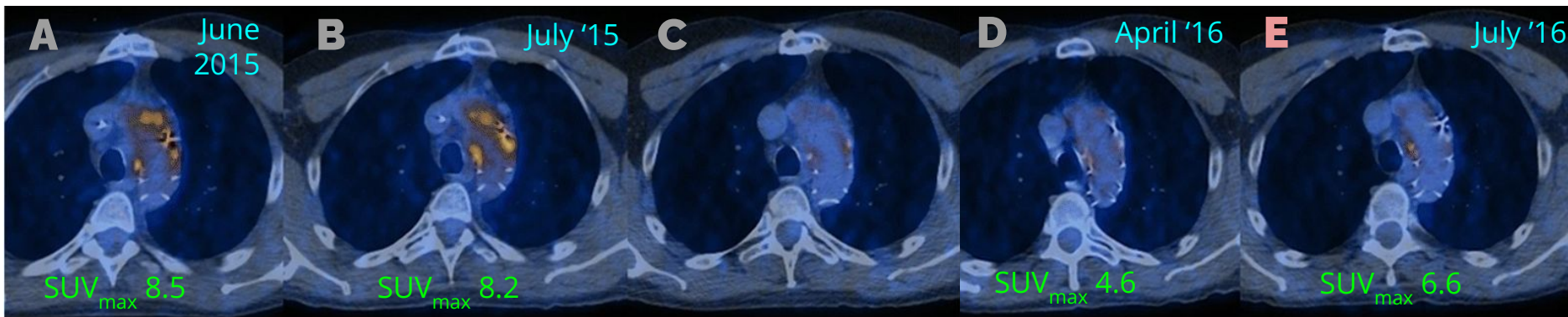
48M developed ascending aortic graft infection with *strep constellatus* & *Aggregatibacter aphrophilus*.

E) Starts having **increased uptake** after a dental procedure in June '16

A) Baseline

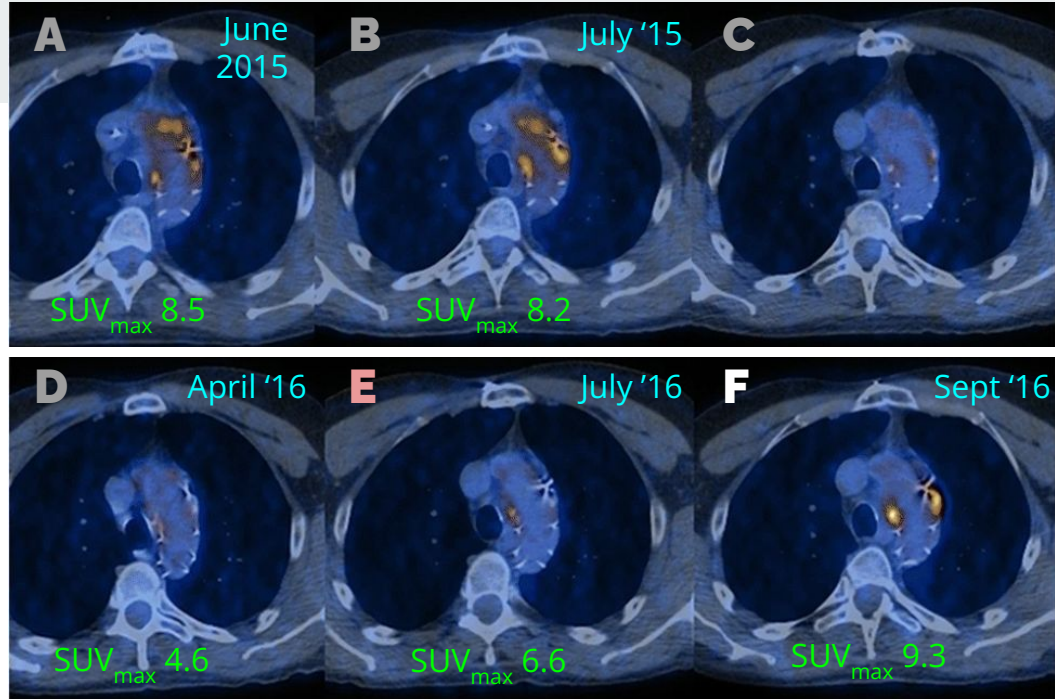
B) Started levaquin

C & D) Improvement of SUV over ~1 year



VASGRA: Case 3 [8]

48M developed ascending aortic graft infection with *strep constellatus* & *Aggregatibacter aphrophilus*. Treated with levofloxacin (starting at **B**) with good initial response (**B-D**) until increased uptake (**E**) after dental procedure. Blood cultures (**F**) grew levofloxacin-resistant *Prevotella* spp.



E) Starts having increased uptake after a dental procedure in June '16

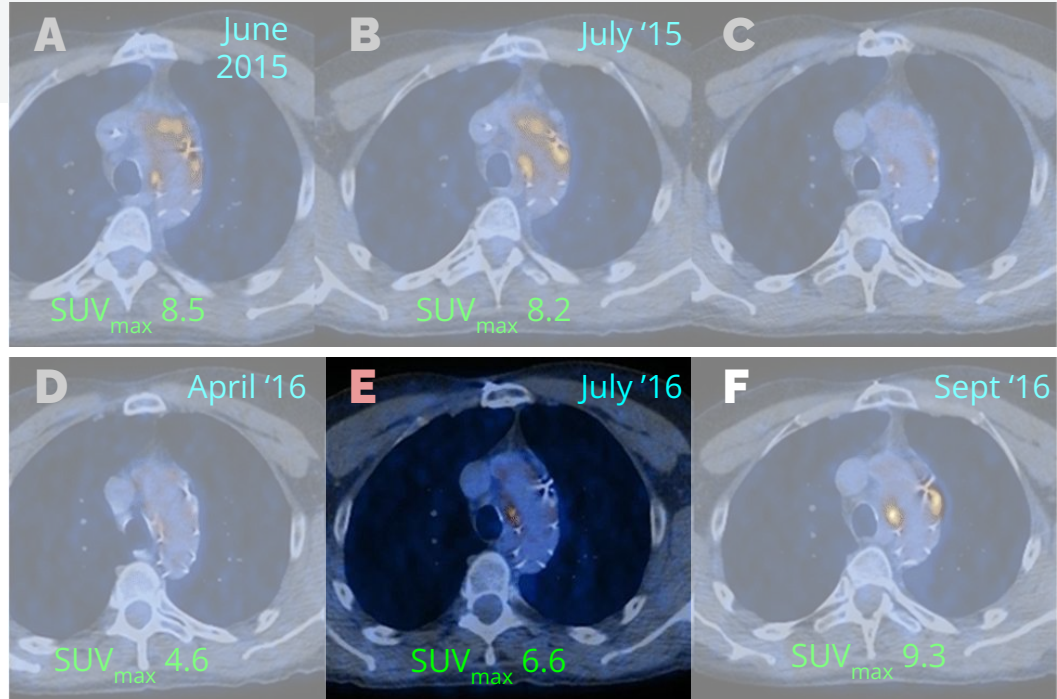
F) Found to be bacteremic with **Prevotella** spp

Dental procedure

VASGRA: Case 3 [8]

48M developed ascending aortic graft infection with *strep constellatus* & *Aggregatibacter aphrophilus*. Treated with levofloxacin (starting at **B**) with good initial response (**B-D**) until increased uptake (**E**) after dental procedure. Blood cultures (**F**) grew levofloxacin-resistant *Prevotella* spp.

PET/CT caught the new (prevotella) infection early



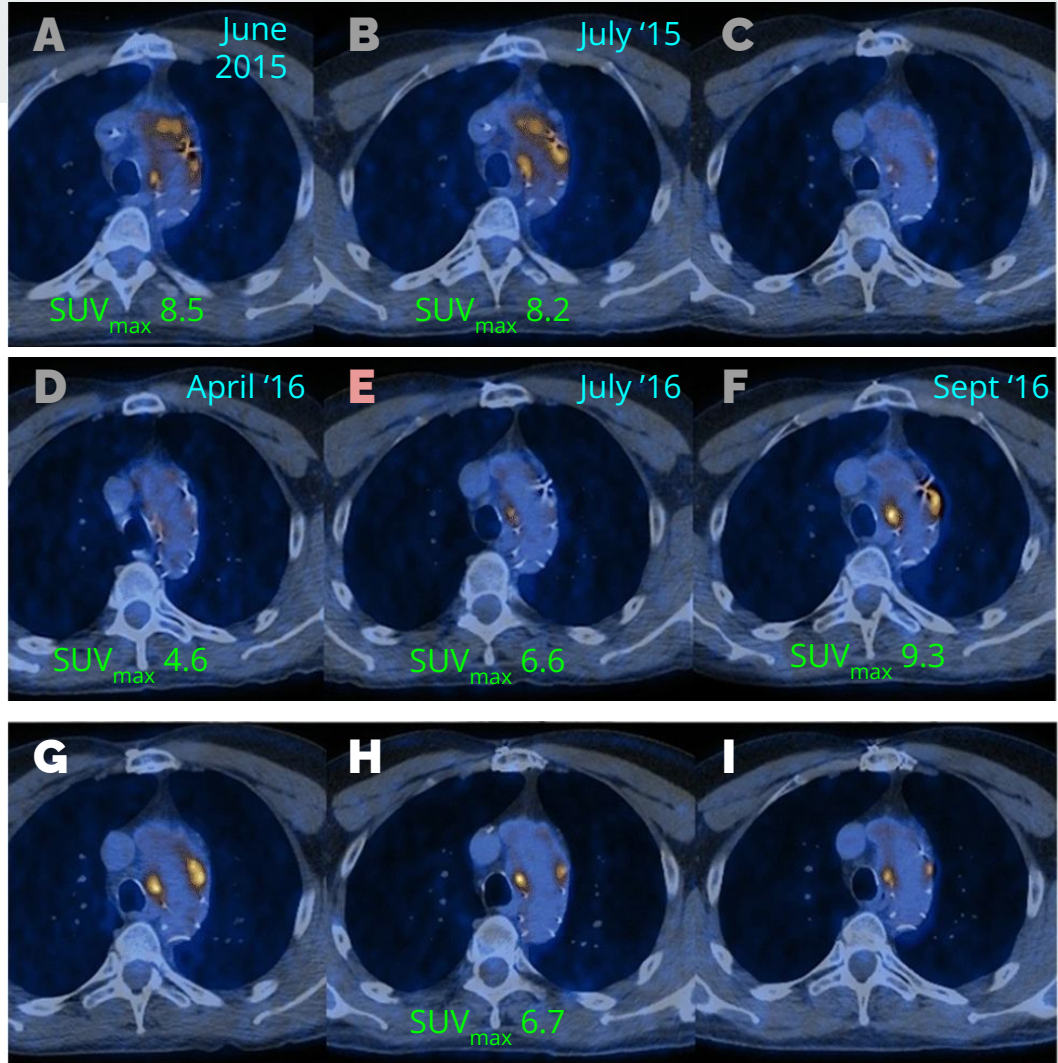
E) Starts having increased uptake after a dental procedure in June '16

F) Found to be bacteremic with *Prevotella* spp

Dental procedure

VASGRA: Case 3 [8]

48M developed ascending aortic graft infection with *strep constellatus* & *Aggregatibacter aphrophilus*. Treated with levofloxacin (starting at **B**) with good initial response (**B-D**) until increased uptake (**E**) after dental procedure. Blood cultures (**F**) grew levofloxacin-resistant *Prevotella* spp, so **antimicrobials were adjusted** (**G-I**) with good clinical response





VASGRA: Patient characteristics [8]

46% had **polymicrobial** infections

- 48% were **gram positive** pathogens
- 25% **gram negative**
- The rest were anaerobes (14%), fungi (6.5%), mycobacteria (2.4%), culture negative (3.3%)

25% of patients **did not have surgery** for their graft infection



VASGRA: Outcomes [8]

“Clinical **cure**” in **65%** of patients after median of **56 weeks of antimicrobials**

- “**22%** of patients are **still on antibiotics**”
 - Of the 15 patients still on antibiotics, **9 are lifelong suppression (13%)** due to non-response on PET/CT &/or CRP

Median duration of follow-up from...

- **Diagnosis:** 2 years
- **Stopping antibiotics:** 1.1 years



VASGRA: Outcomes [8]

“Clinical **cure**” in **65%** of patients after median of **56 weeks of antimicrobials**

- “**22%** of patients are **still on antibiotics**”
 - Of the 15 patients still on antibiotics, **9 are lifelong suppression (13%)** due to non-response on PET/CT &/or CRP
- **17%** of patients **died while on antimicrobial therapy**
 - Of the 12 who died on antibiotics, only **7 were from infection (10%)**

Median duration of follow-up from...

- **Diagnosis: 2 years**
- **Stopping antibiotics: 1.1 years**

After stopping antibiotics, **no cases of relapse** with the same pathogen



VASGRA: Outcomes [8]

“Clinical **cure**” in **65%** of patients after median of **56 weeks of antimicrobials**

- “**22%** of patients are **still on antibiotics**”
 - Of the 15 patients still on antibiotics, **9 are lifelong suppression (13%)** due to non-response on PET/CT &/or CRP
- **17%** of patients **died while on antimicrobial therapy**
 - Of the 12 who died on antibiotics, only **7 were from infection (10%)**

Median duration of follow-up from...

- **Diagnosis: 2 years**
- **Stopping antibiotics: 1.1 years**

After stopping antibiotics, **no cases of relapse** with the same pathogen

**How did PET/CT
change things?**




VASGRA: Results [8]

In cases where **antibiotics were escalated**

In cases where antibiotics were **continued**

In cases where antibiotics were **stopped**



VASGRA: Results [8]

In cases where **antibiotics were escalated**

- **100% of patients** had **focal uptake on PET** (i.e. abnormal PET)
- **1 in 8** of these patients (who were escalated) had **normal CRPs**
- 1 in 4 had no clinical signs of infections

In cases where antibiotics were **continued**

In cases where antibiotics were **stopped**



VASGRA: Results [8]

In cases where **antibiotics were escalated**

- **100% of patients** had **focal uptake on PET** (i.e. abnormal PET)
- **1 in 8** of these patients (who were escalated) had **normal CRPs**
- 1 in 4 had no clinical signs of infections

In cases where antibiotics were **continued**

- Mostly **based on PET/CT findings and CRP**
- **35% of patients** in this group had **normal CRPs** (but abnormal PETs)

In cases where antibiotics were **stopped**



VASGRA: Results [8]

In cases where **antibiotics were escalated**

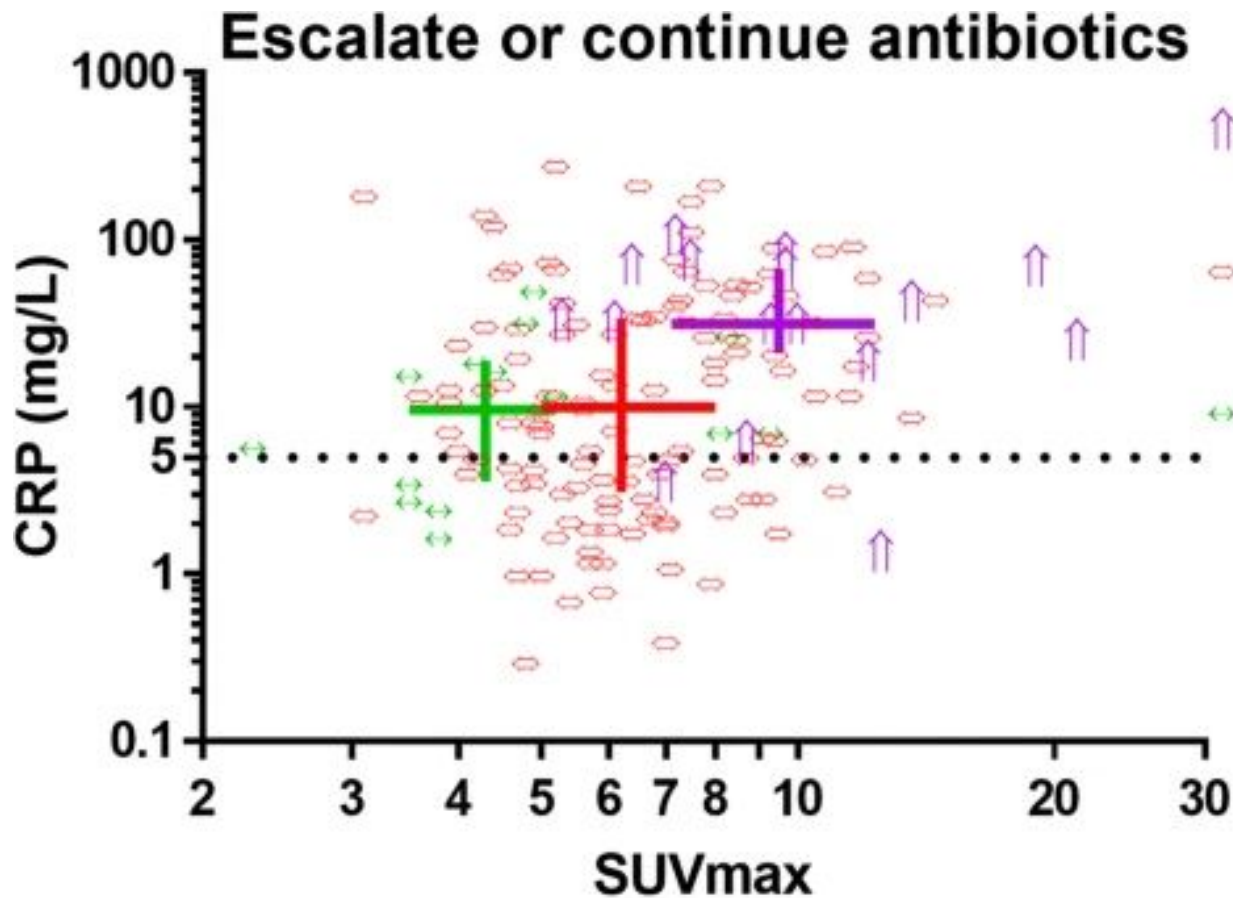
- **100% of patients** had **focal uptake on PET** (i.e. abnormal PET)
- **1 in 8** of these patients (who were escalated) had **normal CRPs**
- 1 in 4 had no clinical signs of infections

In cases where antibiotics were **continued**

- Mostly **based on PET/CT findings and CRP**
- **35% of patients** in this group had **normal CRPs** (but abnormal PETs)

In cases where antibiotics were **stopped**

- **61%** still had **focal uptake** on PET/CT, but the median **SUV_{max} was lower (4.3)** than the other groups (**6.0** and **9.5**)
- **1 in 3** still had **abnormal CRPs**



Escalate
with focal uptake

Continue
with focal uptake

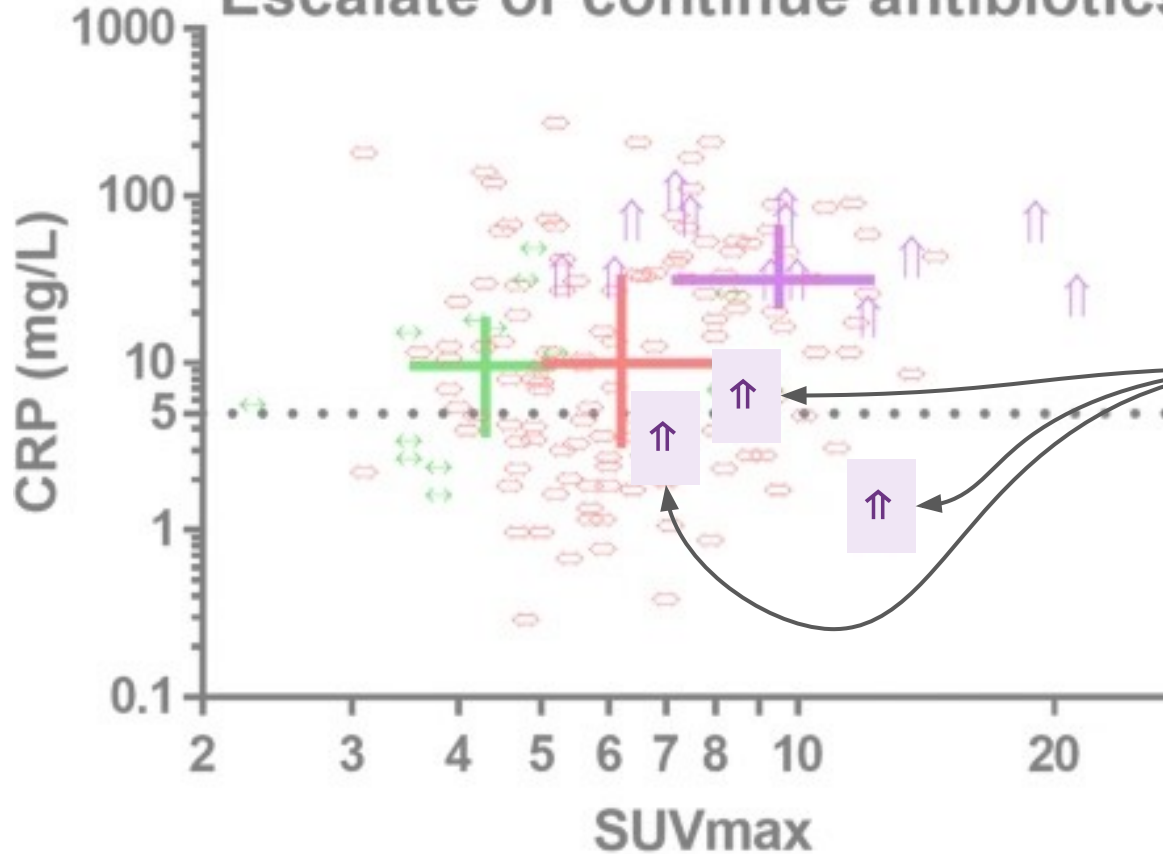
Continue
without focal uptake

The color lines cross at the
median (and extend from the
25th to 75th percentiles)

Dotted line is upper limit of
normal for CRP



Escalate or continue antibiotics

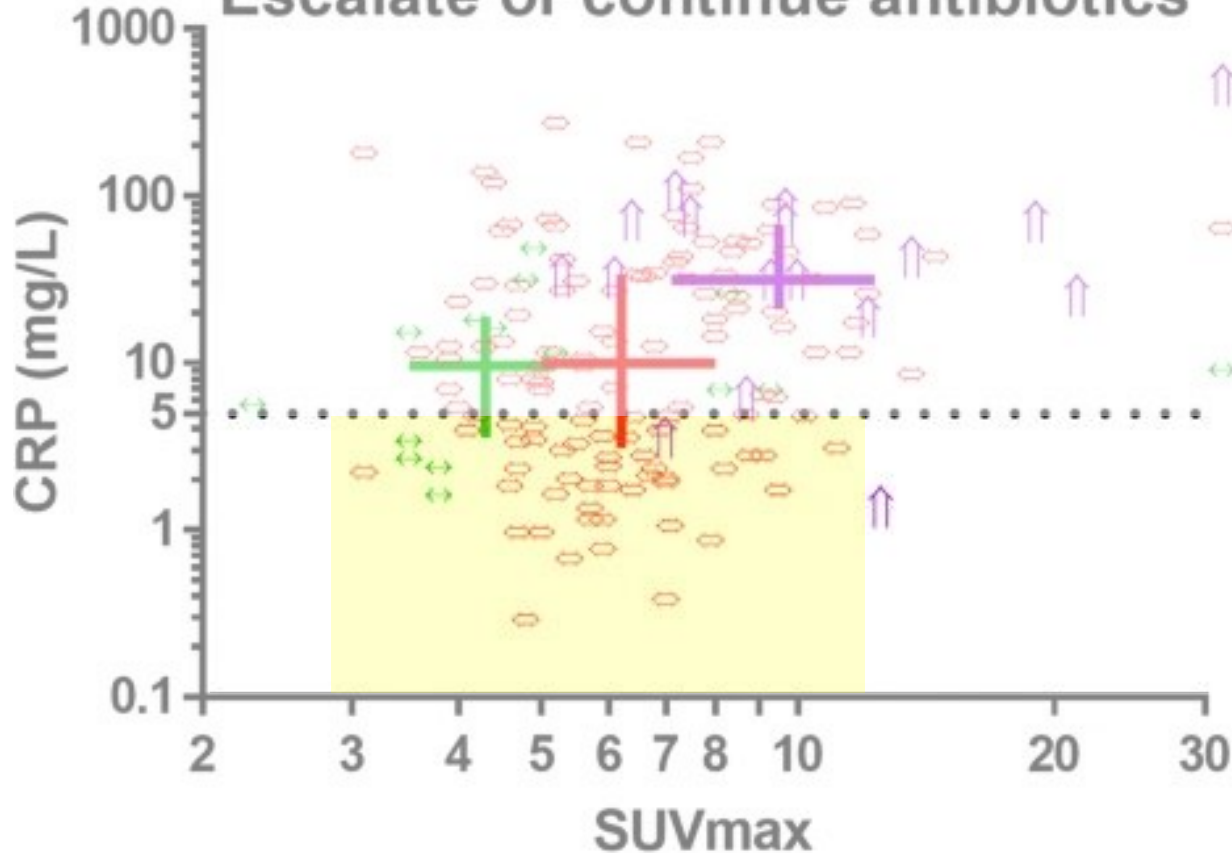


Cases where antibiotics were **escalated despite normal CRPs**

(12.5% of 'escalation' cases)



Escalate or continue antibiotics




Escalate
with focal uptake

Continue
with focal uptake

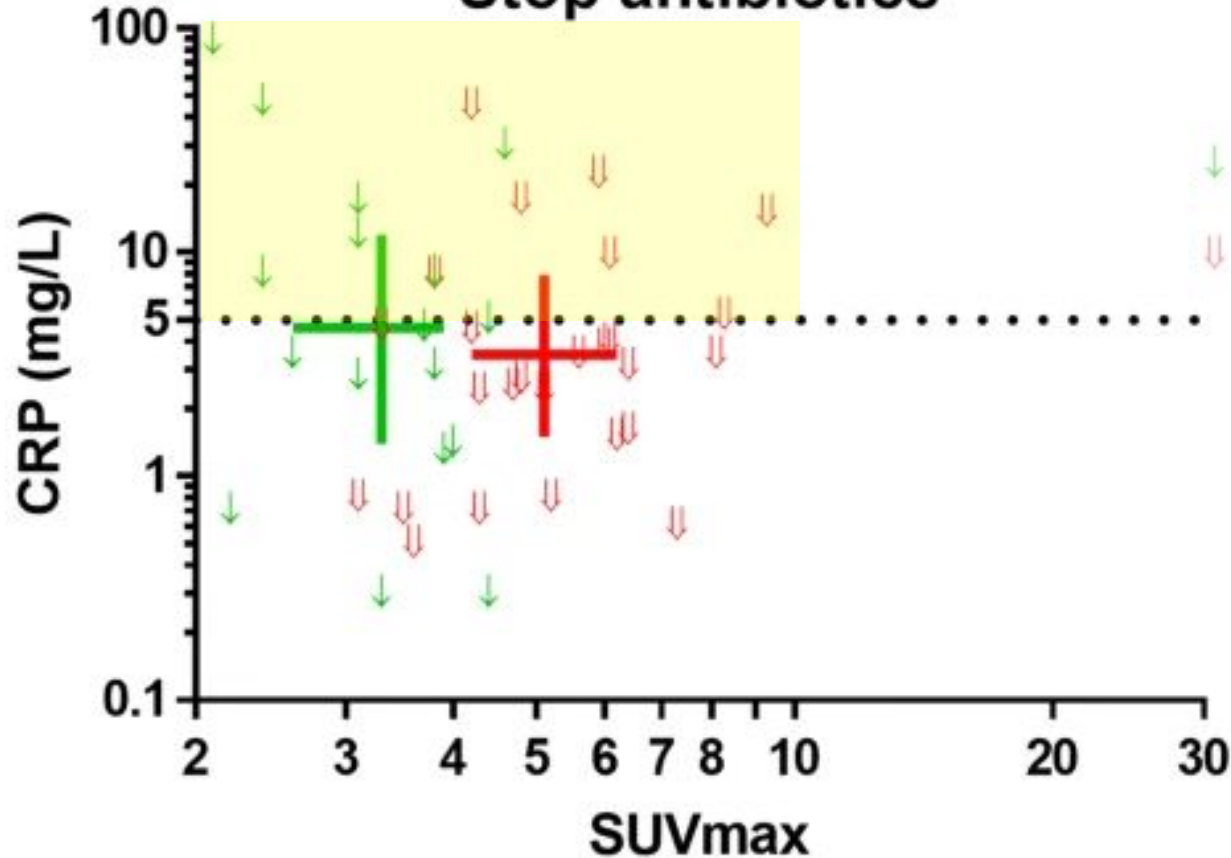
Continue
without focal uptake

Cases where antibiotics were
**continued despite normal
CRPs**

(35.7% of 'continue' cases)



Stop antibiotics



Without focal uptake

With focal uptake

Cases where antibiotics were **stopped despite abnormal CRPs**

(36.4% of 'stop' cases)

The color lines cross at the median (and extend from the 25th to 75th percentiles)

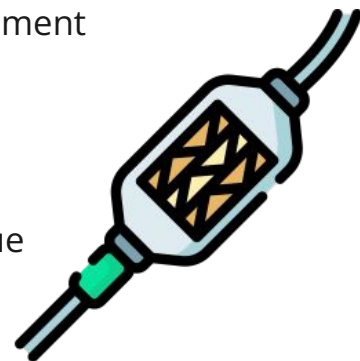
Dotted line is upper limit of normal for CRP

Learning points & take aways



Learning points & take aways

- The presentation of **TAVR endocarditis** may differ from surgical valve-replacement endocarditis
 - May be more **subclinical** (e.g. absence of fevers or embolic phenomenon)
 - Highest risk periprocedurally (**first 100 days**)
 - Higher incidence of **Enterococcus** and healthcare-associated infections
- **Echos have reduced sensitivity** (~67%) in TAVR compared to native valves due to acoustic shadowing and artifacts
- **Cardiac PET/CT** can significantly **increases diagnostic sensitivity**
 - Require some **patient preparation** to optimize quality of images
- Emerging data suggests **serial PET/CT** may be useful to **monitor treatment response** and guide decisions on stopping antibiotics




Slides available on hunterratliff1.com/talk/; Citations available via QR code or via the “citations” button on the website




Skipped for time




Refresher on Nuclear Imaging






Refresher on nuclear imaging

	Tagged WBC / SPECT	PET scan
“What’s infused”	E.g. Tc-99m WBC	E.g. 18F-FDG
Radiotracers		
Ligand (what it measures)		




Refresher on nuclear imaging

	Tagged WBC / SPECT	PET scan
“What’s infused”	E.g. Tc-99m WBC	E.g. 18F-FDG
Radiotracers	<ul style="list-style-type: none">● Technetium-99m (shorter half life, better resolution)● Indium-111 (longer half life → delayed imaging)	Mostly uses F-18 (in ID world), but there are others used in cancer & other fields (Ga-68, N-13)
Ligand (what it measures)		

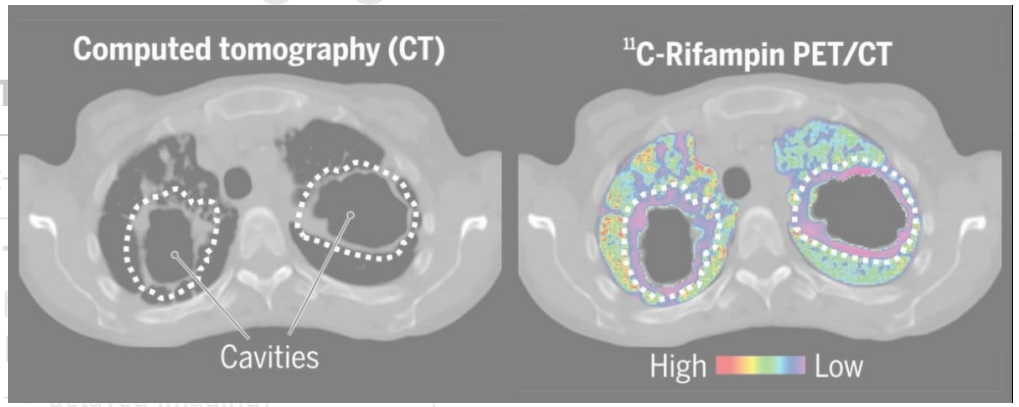
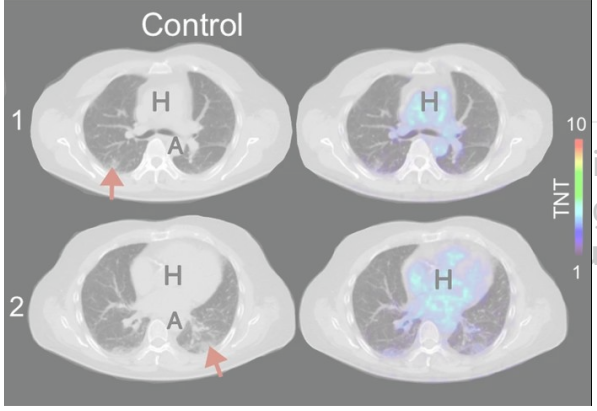
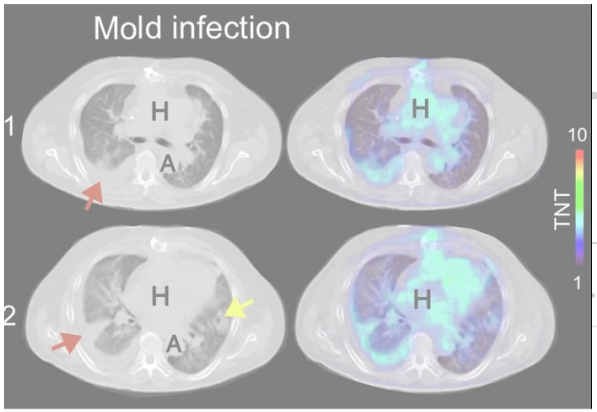


Refresher on nuclear imaging

	Tagged WBC / SPECT	PET scan
“What’s infused”	E.g. Tc-99m WBC	E.g. 18F-FDG
Radiotracers	<ul style="list-style-type: none">● Technetium-99m (shorter half life, better resolution)● Indium-111 (longer half life → delayed imaging)	Mostly uses F-18 (in ID world), but there are others used in cancer & other fields (Ga-68, N-13)
Ligand (what it measures)	Patient’s WBC are extracted, tagged, then infused (measures neutrophil activity)	18F-FDG , a glucose analog (measures metabolically active areas)



Nuclear imaging




patient's **WBC** are extracted, imaged, then infused (measures neutrophil activity)

18F-FDG, a glucose analog (measures **metabolically active** areas)

Research into other targets like:


- **Sorbitol**[6] (18F-FDS; **bacteria & fungi**)
- **Antimicrobials** (**11C-rifampin**)[7]






Refresher on nuclear imaging

	Tagged WBC / SPECT	PET scan
Common radioisotopes (what gets put in)	Tc-99m WBC In-11 WBC	18F-FDG (glucose)
What it measures	Neutrophil activity	Metabolically active areas
Imaging modality (imaging protocol)	Single-photon emission computed tomography	Positron emission tomography
How it works	No clue , I didn't major in physics for a reason	
Often paired with	CT scan (SPECT/CT or PET/CT) to line up with anatomy	



Refresher on nuclear imaging

	Tagged WBC / SPECT	PET scan
Common radioisotopes (what gets put in)	Tc-99m WBC In-11 WBC	18F-FDG (glucose)
What it measures	Neutrophil activity	Metabolically active areas
Imaging modality (imaging protocol)	<u>Single</u> -photon emission computed tomography	Positron emission tomography (uses <u>coincident</u> photons)
Better for... (generally speaking)	<ul style="list-style-type: none">• More specific• Post op infections• Charcot foot	<ul style="list-style-type: none">• Higher resolution• Higher sensitivity



Refresher on nuclear imaging

	Tagged WBC / SPECT	PET scan
Common radioisotopes (what gets put in)	Tc-99m WBC In-11 WBC	18F-FDG (glucose)
What it measures	Neutrophil activity	Metabolically active areas
Imaging modality (imaging protocol)	<u>Single</u> -photon emission computed tomography	Positron emission tomography (uses <u>coincident</u> photons)
Better for... (generally speaking)	<ul style="list-style-type: none">• More specific• Post op infections• Charcot foot	<ul style="list-style-type: none">• Higher resolution• Higher sensitivity
Issues with	<ul style="list-style-type: none">• Small areas (e.g. valves)• Indolent infections / macrophages	<ul style="list-style-type: none">• Sterile inflammation• Abnormal glucose states• Healing areas *